

Spontaneous Corneal Hydrops and Perforation in Pellucid Marginal Degeneration; A Case Report

Davoud Gharebaghi, MD; Behzad Fallahi, MD; Alireza Javadzadeh, MD
Ghassem Amiraslazadeh, MD

Nikookari Eye Hospital, Tabriz Medical University, Tabriz, Iran

Purpose: To report an unusual presentation of pellucid marginal degeneration (PMD).

Case Report: A 57-year-old man with history of corneal ectasia experienced acute hydrops and spontaneous corneal perforation in his right eye. Examination revealed PMD in both eyes. After initial treatment with cyanoacrylate adhesive and a bandage contact lens, therapeutic penetrating keratoplasty was undertaken in the right eye. Due to severity of the condition, the fellow eye was also scheduled for penetrating keratoplasty.

Conclusion: Spontaneous corneal hydrops and perforation may occur in patients with corneal ectasia due to PMD.

Key words: Pellucid Marginal Degeneration; Hydrops; Corneal Perforation

J Ophthalmic Vis Res 2009; 4 (3): 174-176.

Correspondence to: Davoud Gharebaghi, MD. Professor of Ophthalmology; Nikookari Eye Hospital, Tabriz, Iran; Tel: +98 411 6577330, Fax: +98 411 6577336; e-mail: gharabaghi_dawood@msn.com

Received: January 21, 2009

Accepted: May 2, 2009

INTRODUCTION

Pellucid marginal degeneration (PMD) and keratoconus are progressive non-inflammatory ectatic corneal degenerations characterized by localized corneal thinning and protrusion leading to irregular astigmatism and reduced vision. These conditions tend to progress during adolescence but usually stabilize when the patient has attained full growth. In more advanced cases, acute corneal hydrops may result from ruptures in Descemet's membrane. This is a rare complication of keratoconus and even rarer in PMD.¹⁻⁶ Herein we report an unusual case of pellucid marginal degeneration with spontaneous corneal hydrops and perforation and describe the therapeutic approach.

CASE REPORT

A 57-year-old Caucasian man was examined

for acute symptoms of pain, photophobia, tearing and severe visual loss in his right eye of four days' duration. He was in good general health and had no history of systemic disorders, seasonal allergy or recent ocular trauma. He reported gradual decrease in vision over the past 10 years. He had never used glasses or contact lenses. He had history of extracapsular cataract extraction and posterior chamber intraocular lens (PCIOL) implantation in the right eye 8 years ago. He had a documented ophthalmologic examination 5 years before presentation which revealed visual acuity of 20/80 and 20/200 in the right and left eyes respectively. The cornea in both eyes had been clear but demonstrated early signs of ectasia such as mild infero-central bulging, scissoring of the red reflex and the Rizzutti sign. The left eye demonstrated significant posterior subcapsular cataract and subsequently underwent extracapsular cataract extraction and

PCIOL implantation 5 years ago resulting in visual acuity of 20/40.

Upon presentation, visual acuity was light perception and 20/400 in the right and left eyes respectively. Slitlamp biomicroscopy in the right eye revealed dense central and nasal corneal edema and a small corneal perforation in the apical part of the bulging cornea (Fig. 1), the anterior chamber was flat and Seidel test was positive. In the left eye, the cornea was clear except for a crescent-shaped area of sub-epithelial scarring approximately 3 mm in length superior to the inferior limbus, neither Fleischer ring nor Vogt's striae were noted. Corneal thickness was 404 μm centrally, 566 μm superiorly, 297 μm in the inferior para-central area and 617 μm just above the inferior limbus (Fig. 2).

For the right eye we initially used cyanoacrylate adhesive and a bandage soft contact lens but leakage continued and the anterior chamber remained flat for three days. Therefore we planned an 8 mm tectonic penetrating keratoplasty which was performed with 18 interrupted 10-0 nylon sutures (Fig. 3). The fellow eye was also scheduled for penetrating keratoplasty in the near future.

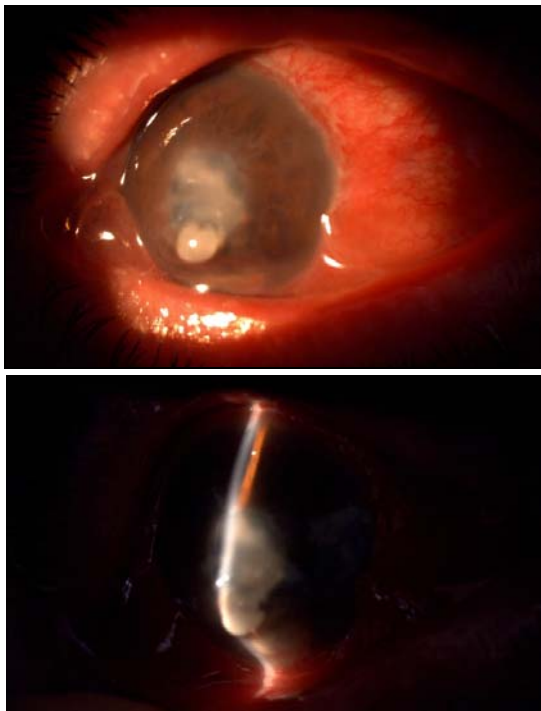


Figure 1 Right eye of the patient presenting with acute hydrops and corneal perforation.

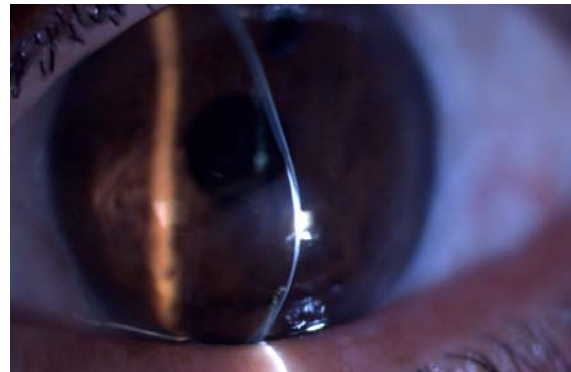

Figure 2 Left eye of the same patient demonstrates signs of pellucid marginal degeneration.

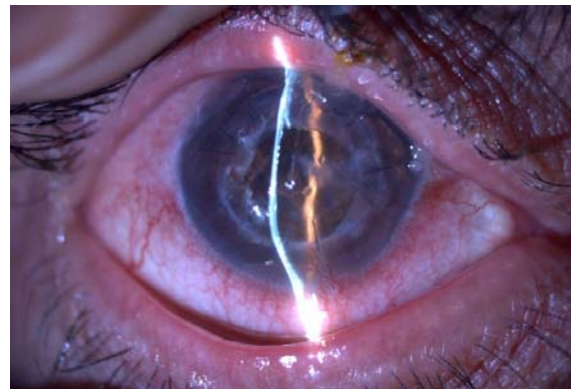


Figure 3 Right eye of the patient after penetrating keratoplasty.

DISCUSSION

Progressive corneal ectasia in keratoconus and PMD can rarely lead to Descemet's membrane rupture causing acute hydrops,³ which has been shown to respond favorably to conservative medical management.^{2,5} Corneal perforation in this setting is exceedingly rare,^{1,4,6} and usually occurs secondary to trauma, eye rubbing and very rarely spontaneously.^{5,7,8} Coexisting severe allergic eye disease has also been associated with the development of acute hydrops.^{4,8} The stromal edema in hydrops is typically self limited and resolves over a period of 6-10 weeks leaving corneal scar and opacity. It has been reported that the ensuing corneal scar improves vision due to flattening of the conical corneal deformation.^{5,7} In a large study of acute hydrops in keratoconus, Tuft et al⁸ found evidence suggesting that flattening of the cornea may occur after spontaneous resolution of hydrops.

Our patient developed symptoms of corneal perforation in the right eye following an acute episode of hydrops without any evidence of trauma, eye rubbing or allergic eye diseases. It was not possible to distinguish between keratoconus and PMD in the involved eye, but the fellow eye demonstrated characteristic features of PMD (Fig. 2). The patient mentioned no visual problems during adolescence and the earliest evidence of corneal ectasia in both eyes appeared in his ophthalmologic reports 5 years before the recent presentation (at the age of 52 years). At that time the patient underwent cataract extraction alone in both eyes. The development of signs and symptoms of PMD in the fifth decade of life and rapid progression to spontaneous perforation in one eye during the next decade is unusual for PMD. Jeng et al⁴ reported the first case of hydrops and perforation in both eyes in a patient with PMD. In their report, the second eye developed hydrops and perforation 20 months after initial presentation. Dantas and Nishiwaki-Dantas⁷ reported another patient who developed hydrops and perforation in the fellow eye 12 months after a similar presentation in the first eye, confirming that patients with hydrops and perforation in one eye are at risk for a similar event in the other eye.

Forooghian et al⁹ reported the first case of successful conservative treatment for hydrops with perforation in PMD. We also tried cyanoacrylate adhesive and a bandage contact lens in our patient for three days which was ineffective and the anterior chamber remained flat. Since the patient had developed rapid progression of corneal ectasia in both eyes over a few years leading to perforation in the right eye, we decided to perform penetrating keratoplasty in his left eye in which visual acuity had deteriorated from 20/80 to 20/400, to prevent the risk of spontaneous perforation.

At times, it is difficult to distinguish PMD from keratoconus. Further adding to the confusion is the fact that keratoconus has been reported to coexist in approximately 10% of eyes with PMD. A keratoconic cornea usually protrudes at the point of maximal thinning, in contrast PMD often demonstrates protrusion above the area of thinning.^{7,8} Typically, inferior

PMD is the most common (85.3%) variant and thinning usually occurs at the 5 to 7 clock hour areas.⁷

In summary, PMD may follow a rapid course of increasing ectasia leading to spontaneous corneal hydrops and perforation. Conservative treatment should initially be considered before resorting to surgery, however the fellow eye is at risk of the same fate and may benefit from early corneal grafting.

Acknowledgements

The authors wish to thank Dr Solmaz Shoa for her kind assistance in preparing the photographs.

REFERENCES

1. Lucarelli MJ, Gendelman DS, Talamo JH. Hydrops and spontaneous perforation in pellucid marginal corneal degeneration. *Cornea* 1997;16:232-234.
2. Orlin SE, Sulewski ME. Spontaneous corneal perforation in pellucid marginal degeneration. *CLAO J* 1998;24:186-187.
3. Akpek EK, Altan-Yaycioglu R, Gottsch JD, Stark WJ. Spontaneous corneal perforation in a patient with unusual unilateral pellucid marginal degeneration. *J Cataract Refract Surg* 2001;27:1698-1700.
4. Jeng BH, Aldave AJ, McLeod SD. Spontaneous corneal hydrops and perforation in both eyes of a patient with pellucid marginal degeneration. *Cornea* 2003;22:705-706.
5. Grewal S, Laibson PR, Cohen EJ, Rapuano CJ. Acute hydrops in the corneal ectasias: associated factors and outcomes. *Trans Am Ophthalmol Soc* 1999;97:187-198.
6. Aldave AJ, Mabon M, Hollander DA, McLeod SD, Spencer WH, Abbott RL. Spontaneous corneal hydrops and perforation in keratoconus and pellucid marginal degeneration. *Cornea* 2003; 22:169-174.
7. Dantas PE, Nishiwaki-Dantas MC. Spontaneous bilateral corneal perforation of acute hydrops in keratoconus. *Eye Contact Lens* 2004;30:40-41.
8. Tuft SJ, Gregory WM, Buckley RJ. Acute corneal hydrops in keratoconus. *Ophthalmology* 1994;101:1738-1744.
9. Forooghian F, Assaad D, Dixon WS. Successful conservative treatment of hydrops with perforation in pellucid marginal degeneration. *Can J Ophthalmol* 2006;41:74-77.