

Case Report

Bilateral Orbital Metastasis of Follicular Thyroid Carcinoma: a Rare Case Report

Farahnaz Bidari-Zerehpoosh¹, Guive Sharifi², Sara Zahedifard¹,
Hussein Soleimantabar³, Kaveh Ebrahimzadeh², Arezoo Aghakhani⁴

1. Dept. of Pathology, Loghman Hakim Hospital, Shahid Beheshti University of Medical Sciences, Tehran, Iran
2. Dept. of Neurosurgery, Loghman Hakim Hospital, Shahid Beheshti University of Medical Sciences, Tehran, Iran
3. Dept. of Radiology, Loghman Hakim Hospital, Shahid Beheshti University of Medical Sciences, Tehran, Iran
4. Dept. of Clinical Research, Pasteur Institute of Iran, Tehran, Iran

ABSTRACT

Follicular thyroid carcinoma (FTC) is the second most common type of thyroid cancer after papillary carcinoma. It usually grows slowly and is clinically indolent; but rarely, its aggressive forms with distant metastases can occur. We report here an uncommon case of bilateral orbital metastasis of FTC. A 70-year-old woman presented with bilateral exophthalmus and past medical history of thyroid nodule surgery 15 years ago. Radiologic evaluation showed massive bilateral orbital mass with extension to calvarium. Tumor decompressed and removed with the suction and curettage and the patient was treated with chemoradiotherapy after operation. Pathologic examination showed metastatic follicular thyroid carcinoma. Although orbital metastasis of follicular thyroid carcinoma is uncommon, FTC should be considered as a potential primary neoplasm in a patient with orbital mass.

Key words: Follicular Thyroid Carcinoma, Orbit, Neoplasm, Metastasis

Received: 03 June 2013

Accepted: 18 August 2013

Address Communications to: Dr. Arezoo Aghakhani , Clinical Research Department, Pasteur Institute of Iran; No 69, Pasteur Ave., Tehran, , Iran.

Email: araghakhani@hotmail.com

Introduction

Follicular thyroid carcinoma (FTC) is a well differentiated tumor and is the second most common type of thyroid carcinomas with 10-15% frequency rate among various types of thyroid cancers. Peak onset of follicular thyroid cancer is between ages 40 and 60 years old and is more common in females than males by 3:1 ratio (1- 3). Despite the well-differentiated characteristics of FTC, this neoplasm can be minimally or overtly invasive. FTC is a slow growing tumor, but after metastasis, it could be associated with high morbidity and mortality (1).

Spread of this cancer to lymph nodes is uncommon. Metastasis from FTC occurs via hematogenous route, and the most common sites of metastasis are bone, lung and the central nervous system. Overall cure rate is high (near 95% for small lesions in young patients), but this decreases with age (3).

There have been a few case reports of follicular carcinoma causing unusual metastases, such as metastasis to skull (4) mandible (5), maxilla (6) and spine (7). Metastatic thyroid carcinoma rarely involves the orbit. They constitute 5% to 6.5% of the total orbital neoplasms (8- 10).

We report an unusual case of follicular thyroid carcinoma with bilateral orbital metastasis and to our knowledge this case is unique due to first report of bilateral orbital metastasis of this type of thyroid carcinoma.

Case Report

A 70-year-old woman was referred with bilateral exophthalmos which had evolved over the past 3 years. Her chief complaint was disfiguring proptosis with peri-orbital swelling. In physical examination, she had no pain and pulsation over the globe. Her eyes were displaced inferiorly and

laterally, but her visual acuity was not affected. Both perimetry and fundoscopic examination were normal.

In past medical history she underwent partial thyroidectomy for multinodular goiter with a prominent cold nodule 15 years ago with pathology diagnosis of nodular goiter. She also had a facial skin lesion with pathologic diagnosis of metastatic follicular thyroid carcinoma 10 years ago but she did not accept to receive any treatment.

At the time of referring she had no clinical findings of hyperthyroidism or hypothyroidism and examination of central nervous system, abdomen and cardiovascular system had no abnormality. Bimanual palpation of anterior neck and thyroid area showed no thyroid mass or nodule and no lymph node.

The complete blood count (CBC), serum electrolyte, abdomeno-pelvic ultrasound and thyroid function tests were all normal. Bone scan showed no pathologic uptake in any bone. Chest computed tomography (CT) showed multiple nodular lesions which were suspicious for metastatic lesions.

On radiologic examinations of orbits, there were bilateral heterogeneous orbital masses. The tumor destructed the orbital rim in both sides with no globe involvement and in the left side protrudes through the key-hole and fronto-zygomatic suture outward and produces clinically noticeable bump. Inferiorly, tumor invaded the posterior wall of orbit, passed through inferior orbital fissure and reached the infra-temporal fossa and pterygomaxillary fissure. After Gadolinium enhancement, tumor took strong homogenous enhancement and there were many flow voids indicating rich vascular supply of this tumor. In CT scan, corrosive nature of the tumor was markedly obvious indicated by destruction of all orbital walls except medial wall (Fig. 1).

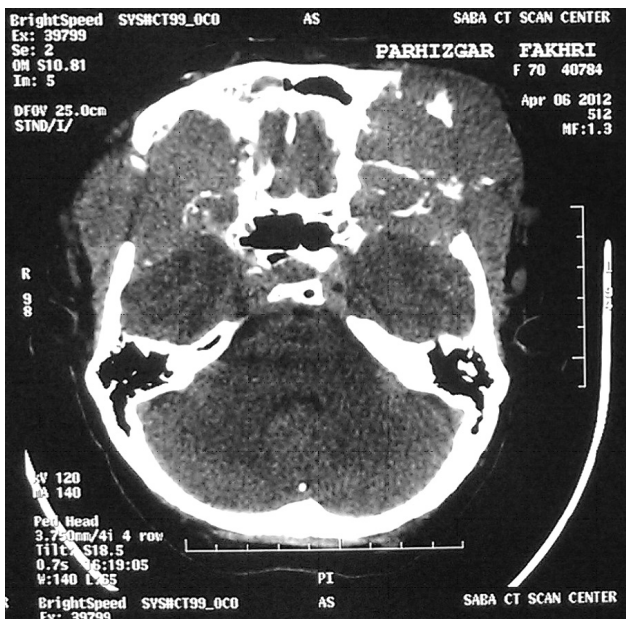


Fig.1: Axial CT scan demonstrates bilateral destructive orbital roof mass lesions.

Bilateral tumor resection followed by reconstruction surgery was performed for the patient. In order to abolish tumor remnants, the patient received radioactive iodine therapy after surgery.

Pathologic examination of the removed masses showed destructive and invasive neoplasm composed of epithelial cells with round to oval nuclei arranged in follicular pattern that contained colloid material and trabecular structures. Mild nuclear pleomorphism and sparse mitotic activity were noted. Tumor invaded the surrounding striated muscles and bones suggestive of invasive follicular thyroid carcinoma (Fig. 2, 3).

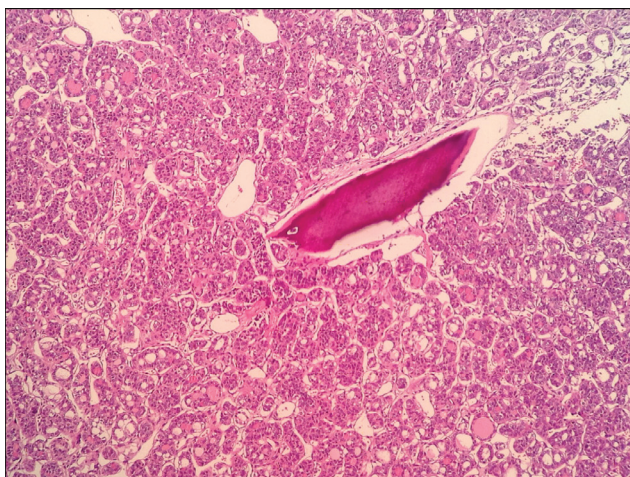


Fig. 2: Orbital mass showing invasive neoplasm composed of epithelial cells with round to oval nuclei arranged in follicular pattern that contain colloid material (Hematoxylin & Eosin staining × 100).

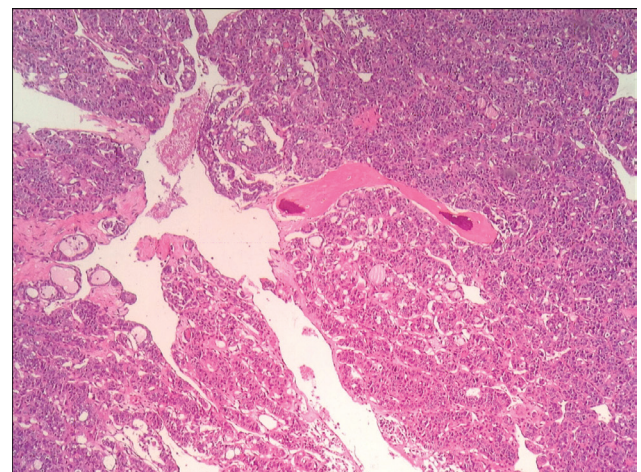


Fig. 3: Sections of orbital masses specimen showing metastatic follicular thyroid carcinoma destructing adjacent bone tissue (Hematoxylin & Eosin staining × 100).

Discussion

Follicular thyroid carcinoma is the second most common type of thyroid cancer after papillary thyroid carcinoma (PTC). FTC occurs in a slightly older age than papillary thyroid carcinoma and is less common in children. Follicular carcinoma is considered more aggressive than papillary carcinoma (3).

Vascular invasion is characteristic for follicular

carcinoma and therefore distant metastasis is more common than PTC. Mortality is related to the degree of vascular invasion. Age is a very important factor in prognosis. Patients older than 40 years old have a more aggressive disease. Lung, bone, brain, bladder, liver and skin are potential sites of distant metastasis in FTC. Lymph node involvement is less common than in papillary carcinoma (1- 3).

Metastases of thyroid carcinomas to the orbit are rare. In a survey by Besic *et al.* orbital metastases of thyroid carcinomas were reported in nine patients. Four of them had PTC, three had history of FTC and one Hürthle cell and one not specified tumor were also reported in orbital metastasis of thyroid cancers. The age of the reported patients ranged from 29 to 83 years (11).

In an investigation in Japan on 128 patients with orbital metastasis in 2002; the most metastatic orbital tumors were from the lung, breast, liver, adrenal gland and stomach. Neuroblastoma and malignant lymphoma were the most frequent neoplasms with bilateral orbital metastasis. Orbital metastasis was very rare in patients with carcinoma of the uterus, ovaries, bladder, pancreas, colon or rectum (12). No orbital metastasis of thyroid carcinomas was reported in this study.

The treatment options for follicular thyroid carcinomas are surgical resection of both primary and secondary, radioactive iodine therapy, Thyroid Stimulating Hormone (TSH) suppression therapy, chemotherapy, and external radiotherapy (13). In our case, bilateral tumor resection followed by reconstruction surgery was performed and radioactive iodine therapy was performed after surgery.

Unilateral proptosis as an initial manifestation of follicular carcinoma thyroid is unusual and only a few cases have been reported in the literature (8-10, 14). Our case is unique, because in our knowledge, this is the first case of bilateral orbital metastasis of follicular thyroid carcinoma in the literature. Therefore although orbital metastases of thyroid carcinomas are infrequent, thyroid malignancies should be considered as a potential primary tumor in a patient with an orbital mass.

Acknowledgements

All ethical issues were considered by the authors. The authors declare that there is no conflict of interest.

References

1. Buandasan K, Hussein A. Follicular thyroid carcinoma mimicking meningioma: A case report. *Asian Pac J Trop Med* 2012; 1: 82-4.
2. Kisakol G, Guney E, Kabalak T. Follicular thyroid carcinoma with late choroidal metastasis. *Turkish J Endocrinol Metabolism* 2002; 4: 155-7.
3. Parlea L, Fahim L, Munoz D, Hanna A, Anderson J, Cusimano M, *et al.* Follicular carcinoma of the thyroid with aggressive metastatic behavior in a pregnant woman: Report of a case and review of the literature. *Hormones* 2006; 5(4):295-302.
4. Ozdemir N, Senoglu M, Acar UD, Canda MS. Skull metastasis of follicular thyroid carcinoma. *Acta Neurochir (Wien)* 2004, 146: 1155-8.
5. Anil S, Lal PM, Gill DS, Beena VT. Metastasis of thyroid carcinoma to the mandible. Case report. *Aust Dent J* 1999; 44: 56-7.
6. Hefer T, Manor R, Zvi Joachims H, Groisman GM, Peled M, Gov-Ari E, *et al.* Metastatic follicular thyroid carcinoma to the maxilla. *J Laryngol Otol* 1998; 112: 69-72.
7. Scarrow AM, Colina JL, Levy EI, Welch WC. Thyroid carcinoma with isolated spinal metastasis: case history and review of the literature. *Clin Neurol Neurosurg* 1999, 101: 245-8.
8. Hornblass A, Kass LG, Reich R. Thyroid carcinoma metastatic to the orbit. *Ophthalmology* 1987; 94(8):1004-7.
9. Betharia SM. Metastatic orbital carcinoma of thyroid. *Indian J Ophthalmol* 1985; 33(3):191-3.
10. Daumerie C, De Potter P, Godfraind C, Rahier J, Jamar F, Squiffi et JP. Orbital metastasis as primary manifestation of thyroid carcinoma. *Thyroid* 2000; 10(2):189-92.
11. Besic N, Luznik Z. Choroidal and orbital metastases from thyroid cancer. *Thyroid* 2013; 23(5):543-51.
12. Amemiya T, Hayashida H, Dake Y. Metastatic orbital tumors in Japan: a review of literature. *Ophthalmic Epidemiol* 2002; 9(1):35-47.
13. What you need to know about thyroid cancer. *Nat*

tional Cancer Institute Web site. <http://www.cancer.gov/cancertopics/wyntk/thyroid/page1>. October 26, 2007. Accessed April 30, 2010.

14. Basu S, Nair N, Aravind N. Unilateral proptosis with thyrotoxicosis resulting from solitary retroorbital soft tissue metastasis from follicular carcinoma thyroid. *Clin Nucl Med* 2001; 26(2):136-8.