

Familial Presentation of Monocular Elevation Deficiency Syndrome due to Hypoplasia and Absence of Superior Rectus

Mohammad Reza Talebnejad, MD¹ • Mansure Jamshidian, MD² • Mahnaz Mosallaei, MD³

Abstract

Purpose: To report a new familial presentation of hypoplasia and absence of superior rectus in the form of unilateral monocular elevation deficiency

Case report: A 7-year-old boy was referred to our center (Poostchi eye clinic) with a chief complaint of ocular misalignment in his right eye since birth. One of his siblings was a known case of unilateral monocular elevation deficiency and was operated previously. Other family members were normal. Ocular motility examinations revealed more than 60 prism diopters hypotropia of right eye in primary position associated with limitation of elevation in both abduction and adduction. No pattern (A, V, etc.) was detected. There was no sign of craniosynostosis by neurologic exams or by imagings. Unilateral monocular elevation deficiency was diagnosed. Under operation congenital absence of superior rectus was found while in her sister's chart review, only congenital hypoplasia of superior rectus was reported.

Conclusion: This is the first report of familial presentation of monocular elevation deficiency resulted from both hypoplasia and absence of superior rectus. This finding may suggest the possible role of a genetic mechanism to be responsible for this disorder.

Keywords: Familial, Congenital, Hypoplasia, Absence, Superior Rectus

Iranian Journal of Ophthalmology 2010;22(3):53-56 © 2010 by the Iranian Society of Ophthalmology

-
1. Associate Professor of Ophthalmology, Poostchi Eye Research Center, Department of Ophthalmology, Shiraz University of Medical Sciences
 2. Resident in Ophthalmology, Poostchi Eye Research Center, Department of Ophthalmology, Shiraz University of Medical Sciences
 3. Ophthalmologist, Poostchi Eye Research Center, Department of Ophthalmology, Shiraz University of Medical Sciences

Received: May 8, 2010

Accepted: August 25, 2010

Correspondence to: Mohammad Reza Talebnejad, MD

Poostchi Eye Research Center, Shiraz, Iran, Tel:+98 711 2302830, Email: talebmor@sums.ac.ir

Introduction

Monocular elevation deficiency is characterized by limitation of elevation in adduction as well as abduction and in straight upward gaze.¹ Abnormal muscle development was pertained as one of the causes of this ocular deviation. Some previous reports were in favor of abnormal muscle structure in patients with craniosynostosis associated with monocular elevation deficiency.¹ However, there is one previous report of such a case in the literature with both unilateral absence of superior rectus and no evidence of craniofacial anomalies. There was also one report of bilateral aplasia presented as double elevator palsy and forme frustre type of craniofacial anomalies.² Here, we report a case of familial presentation of unilateral monocular elevation deficiency due to congenital absence of superior rectus without craniosynostosis.

Case report

A 7-year-old boy presented to our center (Poostchi Eye Clinic) with ocular misalignment since birth time. He was in a family of 6 members and was a product of normal vaginal delivery with no history of previous trauma or surgery. Consanguineous marriage was not found in his family. The patient had the history of eye deviation in one of his sisters, but other siblings were normal. Best corrected visual acuity (BCVA) was found to be about $20/200$ in the right eye and $20/40$ in the left eye and cycloplegic refraction was $-9.00-5.00@22$ and $-4.00-1.00@100$, respectively. Ocular motility examinations revealed more than 60 prism diopters hypotropia of the right eye in primary position associated with limitation of elevation in both abduction and adduction (Figure 1). No pattern (A, V, etc.) was detected. More ocular exams also demonstrated ptosis of right upper lid with poor bells' phenomena. Neurologist consultation and CT-scan was negative for any evidence of craniosynostosis.

Because of positive forced duction test and inferior rectus restriction demonstrated under operation, inferior rectus recession (8 mm) with hangback sutures were performed in an attempt to correct the deviation. Two months after operation, 40 prism diopters residual hypotropia was still remaining. Consequently, in the second operation, after extensive exploration, promising absence of superior

rectus was detected (Figure 2). Modified knapp procedure was performed by half tendon transposition of the horizontal rectus muscles superiorly and suturing 7 mm posterior to the limbus with vicryl 6-0. This procedure resulted in mild esotropia and absence of any manifest vertical misalignment in primary position at least five months after operation. Further evaluations showed mild lower lid retraction as the sequela of the inferior rectus recession procedure. As was mentioned, one of his sisters was also a known case of unilateral monocular elevation deficiency syndrome with less severity of clinical findings due to congenital hypoplasia of superior rectus and was previously managed with modified knapp procedure.

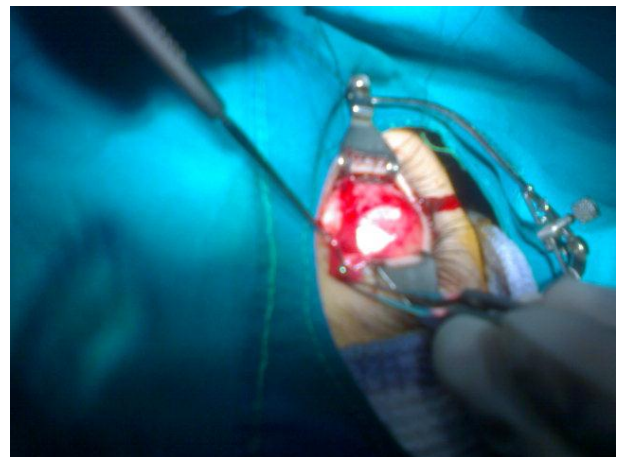


Figure 1. Superior rectus exploration showed congenital absence of this muscle.

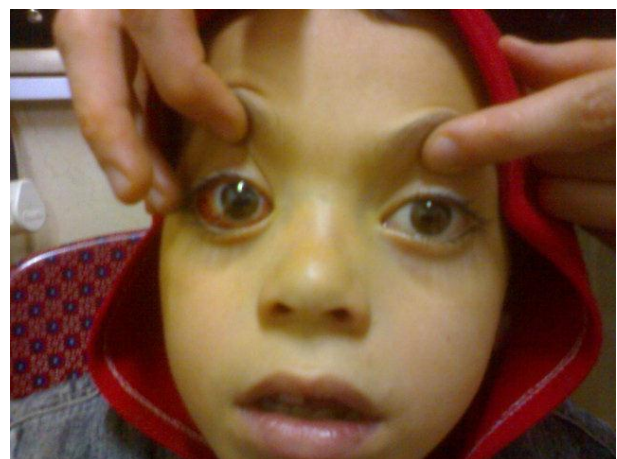

Figure 2. Patient's right eye became aligned after the second procedure.

Discussion

Congenital absence of superior rectus is a very rare abnormality, seldom reported in literature.¹⁻⁴ It is usually associated with craniosynostosis most commonly Apert, Crouzon and Collins Syndrome.⁶ Incomitant strabismus in cases with craniosynostosis is a common finding and is resulted from combination of both horizontal and vertical deviations mainly due to abnormal insertion of the affected muscle.¹ There are also few previous reports of both unilateral and bilateral absence of superior rectus without associated craniofacial anomalies.²⁻⁴ Although, double elevator palsy is not an uncommon congenital or acquired clinical finding, the exact mechanism of this anomalous presentation is not demonstrated so far.⁷ It was supposed that monocular elevation deficiency with palsy of superior rectus and inferior oblique can be caused either by supranuclear problems or muscular abnormalities.⁸ Inferior rectus restriction rather than palsy of superior rectus and inferior oblique can be considered as one of the cause of elevation deficiency.⁸⁻¹⁰ Because of this, it has been proposed that congenital monocular elevation deficiency could be divided into three subsets: primary superior rectus or inferior oblique palsy, primary inferior rectus restriction, and congenital supranuclear elevation deficiency.¹¹ Ptosis can be accompanied with any types of these anomalies.¹¹ Indeed, secondary restriction of inferior rectus may mislead us to perform releasing of inferior rectus and recession, rather than Knapp procedure as a first stage in the surgical management.^{8,9} In patients with primary superior rectus palsy, a recent magnetic resonance imaging of double

elevator palsy revealed small abnormal muscle with decreased volume of superior rectus muscle on the affected side, while the other rectus muscles were normal.¹²

Conclusion

This finding establishes the presence of structural abnormality of either congenital hypoplasia or absence of the involved superior rectus muscle in this condition.¹² As mentioned before, the present case has a history of similar clinical finding with less degrees of severity in her sister, where abnormal and small superior rectus was present. So, it is logically accepted to think about a possible genetic mechanism and underlying gene mutation to make a wide range of a defect from muscle hypoplasia to total agenesis of affected muscle. More genetic studies will be warranted to evaluate this theoretical hypothesis in this relation. Moreover, as forced duction test was positive in our patient, the release of inferior rectus was performed as the first step while further work ups were applied in face of postoperative under-correction. This should be considered as a possibility of masking the superior rectus abnormality by the presence of secondary inferior rectus restriction or the co-association of primary superior rectus problem with primary inferior rectus restriction. Also, imaging studies such as CT-scan as well as MRI may be suggested to be helpful in pre-operative diagnosis of muscular abnormalities in patients with congenital monocular elevation deficiency syndrome.

References

1. Xiao MY, Shou JY, Li YP. [Clinical features and surgical treatment of congenital ocular muscle palsy characterized with double elevator dysfunction]. *Zhonghua Yan Ke Za Zhi* 2004;40(10):652-54.
2. Mather TR, Saunders RA. Congenital absence of the superior rectus muscle: a case report. *J Pediatr Ophthalmol Strabismus* 1987;24(6):291-5.
3. Bagheri A, Ferdosi A, Bottros A, Hunter D. Unilateral superior rectus aplasia without craniofacial anomaly. *Digital Journal of Ophthalmology* 2005;11(5).
4. Cuttone JM, Brazis PT, Miller MT, Folk ER. Absence of the superior rectus muscle in Apert's syndrome. *J Pediatr Ophthalmol Strabismus* 1979;16(6):349-54.
5. Snir M, Gilad E, Ben-Sira I. An unusual extraocular muscle anomaly in a patient with Crouzon's disease. *Br J Ophthalmol* 1982;66(4):253-7.

6. Rattigan S, Nischal KK. Foster-type modification of the Knapp procedure for anomalous superior rectus muscles in syndromic craniosynostoses. *J AAPOS* 2003;7(4):279-82.
7. Caldeira JA. Vertical transposition of the horizontal rectus muscles for congenital/early onset "acquired" double elevator palsy: a retrospective long term study of 10 consecutive patients. *Binocul Vis Strabismus Q* 2000;15(1):29-38.
8. Scott WE, Jackson OB. Double elevator palsy: the significance of inferior rectus restriction. *Am Orthopt J* 1977;27:5-10.
9. Barsoum-Homsey M. Congenital double elevator palsy. *J Pediatr Ophthalmol Strabismus* 1983;20(5):185-91.
10. Lessell S. Supranuclear paralysis of monocular elevation. *Neurology* 1975;25(12):1134-43.
11. Metz HS. Double elevator palsy. *Arch Ophthalmol* 1979;97(5):901-3.
12. Cadera W, Bloom JN, Karlik S, Viirre E. A magnetic resonance imaging study of double elevator palsy. *Can J Ophthalmol* 1997;32(4):250-3.