

# Bronchoscopic Extraction of a Hydatid Membrane in a 26-Year-Old Woman with Recurrent Pneumonia

A Alavi<sup>1\*</sup>, M Aghajanzadeh<sup>2</sup>, G Mortaz Hejri<sup>3</sup>

<sup>1</sup>Department of Pulmonology Diseases and TB Research Center, <sup>2</sup>Department of Thoracic Surgery,

<sup>3</sup>General Physician, Guilan University of Medical Sciences, Razi Hospital, Rasht, Iran

## Abstract

Cystic echinococcosis is a public health problem in endemic areas. Recurrent pneumonia is a rare complication of ruptured hydatid cysts of the lung. We report a 26-year-old lady with a recurrent right lower lobe (RLL) pneumonia. Her CXR and chest CT scan revealed involvement of RLL. In her history, it was revealed that she had undergone a surgery for liver hydatid cyst two years ago.

During fiberoptic bronchoscopy (FOB) for unresolved pneumonia, we extracted the whitish-yellow bright gelatinous membrane obstructing the orifice of the posterior basal segment of RLL. A follow-up CT scan done six months later revealed clearance of RLL opacity and pleural effusion. Although treatment of pulmonary hydatid cyst by FOB is an exceptional event, our exceptional case illustrates a complete treatment without any further need for a thoracic surgical procedure which could have many complications and even morbidity.

**Keywords:** Pulmonary hydatid cyst; Fiberoptic bronchoscopy; Recurrent pneumonia

## Introduction

Cystic echinococcosis is seen worldwide and is an important public health problem. It occurs in endemic areas such as South and Central America, the Middle East, sub-Saharan Africa, Russia, China, Australia, New Zealand, and Iran.<sup>1,2</sup> The disease is caused by *Echinococcus granulosus*, a tapeworm of the genus *Echinococcus*.<sup>3,4</sup> Most of the intact lung cysts are discovered incidentally on chest radiographs. Occasionally, an unruptured cyst results in cough, haemoptysis or chest pain. Symptomatic hydatid disease of the lung, however, more often follows the rupture of the cyst. The cyst may rupture spontaneously, as a result of trauma, or a secondary infection.<sup>1</sup> Recurrent pneumonia is a very rare complication of ruptured hydatid cysts (HC) of the lung.<sup>2</sup>

Diagnosis of pulmonary hydatid cyst (PHC) is generally based on clinical and radiological findings.<sup>3</sup> The current treatment of the HC of the lung is complete excision of the disease process with maximum

preservation of the lung. Medical treatment may be considered in selected cases under close observation.<sup>5</sup> Some attempts have been directed to diagnosing the cysts by fiberoptic bronchoscopic (FOB) evaluation.<sup>3</sup>

The aim of this case report is to present the treatment of HC with bronchoscopic extraction of a hydatid membrane associated with post-obstructive pneumonia.

## Case Report

A 26-year-old lady was referred with intermittent cough with yellowy brown expectoration and black colored particles, exertional dyspnea, night sweating, and fever of five month duration. Zeihl-Neelsen stain of the sputum was negative for acid-fast bacilli and no other significant findings were seen on direct microscopy. In her history, it was revealed that she had undergone surgery for liver HC two years before and had been treated by albendazol for three months.

The temperature was normal and the blood pressure was 110/70 mm Hg, PR=100 and RR=14. Physical examination was generally normal except for a few crackles at the right lung base. On admission, her CXR showed alveolar opacity at the lower third part of the right lung in favor of pneumonia, so she was

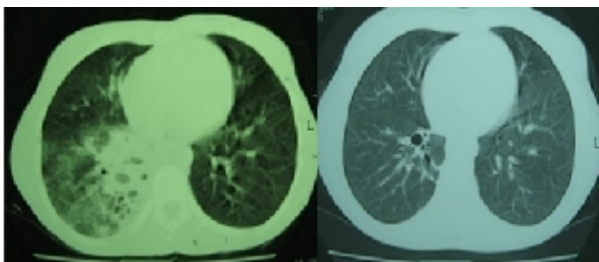
\*Correspondence Ali Alavi, MD, Assistant Professor of Department of Pulmonology, Pulmonary Diseases and TB Research Center, Razi Hospital, Guilan University Medical Sciences, Rasht, Iran. Tel: +98-131-5550028, Fax: +98-131-5530169, e-mail: rtrc-gums@yahoo.com  
Received: July 20, 2009 Accepted: October 9, 2009

treated by azithromycin and cefixim for a complete course. The control CXR after two weeks did not change the patient's condition. We requested a chest CT scan which revealed alveolar involvement of RLL with central hypolucency, a small cavitation in the postero-lateral portion of RLL, a mild pleural effusion, and a double-segmented thick wall cystic lesion in the posterior surface of the liver (Figure 1-Left).

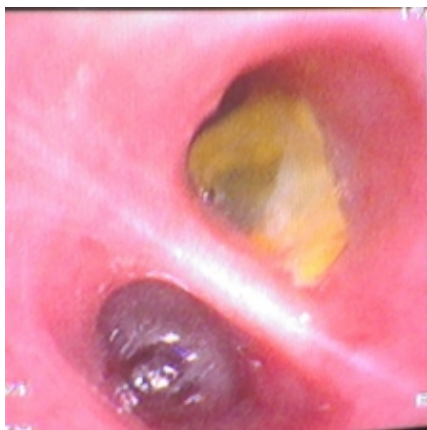The findings of CT scan made us carry out a video-bronchoscopy for diagnostic evaluation of chronic persistent pneumonia, which revealed whitish-yellow bright gelatinous membrane at the orifice of the posterior basal segment of RLL (Figure 2).

Therapeutic FOB by forceps fragmentation, complete suction and bronchoalveolar lavage were done. The bronchial washing fluid was submitted for microbiological and histopathological examinations which indicated severe acute inflammatory process and a membranous lesion composed of a laminated layer with germinal covering, suggestive of HC. After this documentation, we re-treated the patient with albendazol.

A follow-up CT scan six months later revealed clearance of RLL opacity and pleural effusion. A small cystic lesion of the liver was remained. (Figure 1- Right).



**Fig. 1:** CT scan of the lung before (left) and after (right) bronchoscopy



**Fig. 2:** Whitish-yellow bright gelatinous membrane in the video-bronchoscopy

## Discussion

PHC disease has remained a common clinical problem in areas of the world endemic to echinococcal infections.<sup>6</sup> Infection with *Echinococcus* is always asymptomatic. Symptoms develop because of one or more of three events: 1- mechanical pressure or deformation of the tissues or nearby vascular structure, 2- rupture or leakage of the cyst, or 3- superinfection.<sup>7</sup> Intact or simple HC of the lung produces no characteristic symptoms. Small, peripherally located cysts are usually asymptomatic, whereas large cysts might manifest by compression of the adjacent organs. Usual presentation is non-productive cough, sometimes with blood-streaked sputum.<sup>5</sup>

One third of the diagnosed cases of PHC show ruptured or infected cysts.<sup>7</sup> Rupture of the HC into an adjacent bronchus may be manifested by vigorous coughing and expectoration of a large amount of salty sputum, consisting of hydatid fluid and occasionally fragments of the laminated membrane, generally described as a grape skin, or frothy blood. Occasionally, the intrabronchial rupture of the cysts manifests with sudden and severe dyspnea, which may lead to suffocation and death from complete tracheal obstruction by fragments from the hydatid membrane. When the cyst is ruptured into the pleural space, the symptoms are usually insidious and consist of dry cough, chest pain, moderate dyspnea, generalized malaise, and fever.<sup>5,8</sup>

Evaluation of pulmonary disorders by FOB is a rapidly developing facility. There is little information in the medical literature about the diagnosis of hydatid disease, using FOB evaluation.<sup>9</sup> Diagnostic and therapeutic FOB for PHC is controversial. Most authors do not recommend bronchoscopy because of the risk of cyst rupture, except for excluding malignancy.<sup>7</sup> For patients who are able to undergo surgery, it is considered the treatment of choice since the parasite can be completely removed and the patient can be cured. The surgical options for lung cysts include lobectomy, wedge resection, pericystectomy, intact endocystectomy, and capitonnage.<sup>1</sup>

Management of the ruptured cyst during the acute stages is mainly directed toward the prevention of major complications resulting from the evacuation of cystic contents into the tracheobronchial tree or pleural space.<sup>7</sup> Complicated cases have higher rates of preoperative and postoperative complications and require longer hospitalization and more extensive surgical procedures than uncomplicated cases.<sup>10</sup> In comparison, FOB is a less invasive procedure that requires shorter

hospitalization and fewer complications.

In our case, FOB revealed a hydatid membrane obstructing the posteriorbasal segment of RLL which was removed completely and only a mild fibrotic opacity was seen in the control CT-scan six months later, so the indication for surgery was removed.

In one report, complete extraction of a hydatid membrane by FOB was performed, and the control radiography after it demonstrated clear regression of the opacity.<sup>11</sup>

Köksal reported two cases in which FOB revealed laminated membrane of HC. The patients underwent surgery because total extraction of the membranes was not possible.<sup>6</sup> Although treatment of PHC by FOB is an exceptional event, our exceptional case illustrates a complete treatment without any further need for a thoracic surgery which could have many complications and even morbidity.

**Conflict of interest:** None declared.

## References

- 1 Morar R, Feldman C. Pulmonary echinococcosis. *Eur Respir J* 2003; **21**:1069-77. [12797504] [doi:10.1183/09031936.03.00108403]
- 2 Saidi F. Treatment of Echinococcus cyst. In: Nyhus L, Baker RJ, Fischer JE,(ed), *Mastery of Surgery*. Little Brown 1997; pp:1035-53.
- 3 Dottorini S, Sparvoli M, Bellucci C, Magnini M. Echinococcus granulosus: diagnosis of hydatid disease in man. *Ann Trop Med Parasitol* 1985; **79**:43-9. [3985705]
- 4 Mehrabani D, Oryan A, Sadjadi SM. Prevalence of echinococcus granulosus in stray dogs and herbivores in shiraz iran. *Vet Parasitol* 1999; **86**:217-20. [10511103] [doi:10.1016/S0304-4017(99)00151-X]
- 5 Thomas W, Shields, Joseph Lociero, Ronald B, Ponn, General Thoracic Surgery, Fifth edition, Lippincott Williams & Wilkins, Philadelphia 2000; pp:1116-22.
- 6 Köksal D, Altinok T, Kocaman Y, Taştepe I, Ozkara S. Bronchoscopic diagnosis of ruptured pulmonary hydatid cyst presenting as nonresolving pneumonia: report of two patients. *Lung* 2004; **182**:363-8. [15765928] [doi:10.1007/s00408-004-2517-0]
- 7 Mason, Broadus, Murray, Nadel: *Textbook of Respiratory Medicine*; 4th ed; Philadelphia, Elsevier saunders, pp: 1101-2.
- 8 Saidi F, Rezvan-Nobahar M. Intraoperative bronchial aspiration of ruptured pulmonary hydatid cysts. *Ann Thorac Surg* 1990; **50**:631-6. [2222054]
- 9 Saygi A, Oztek I, Güder M, Süngün F, Arman B. Value of fibreoptic bronchoscopy in the diagnosis of complicated pulmonary unilocular cystic hydatidosis. *Eur Respir J* 1997; **10**:811-4. [9150317]
- 10 Kuzucu A, Soysal O, Ozgel M, Yologlu S. Complicated hydatid cysts of the lung: clinical and therapeutic issues. *Ann Thorac Surg* 2004; **77**:1200-4. [15063234] [doi:10.1016/j.athoracsur.2003.09.046]
- 11 Bousnina S, Zendah I, Marniche K, Racil H, Hassine E, El Mezni F, Chabbou A. Complete extraction of a hydatid membrane by bronchial fibroscopy. *Rev Pneumol Clin* 2005; **61**:270-4. [16208193] [doi:10.1016/S0761-8417(05)84825-4]