

# Premacular Hemorrhage in Valsalva Retinopathy:

## A Study of 21 Cases

Mehdi Nili AhmadAbadi, MD<sup>1</sup> • Reza Karkhaneh, MD<sup>2</sup> • Ahmad Mirshahi, MD<sup>1</sup>  
AliReza Lashay, MD<sup>2</sup> • Zahra Aalami Harandi, MD<sup>1</sup> • Ramak Roohipoor, MD<sup>3</sup>  
Mohammad Riazi Esfahani, MD<sup>1</sup> • Seyed Ali Tabatabaee, MD<sup>3</sup> • Morteza Movassat, MD<sup>1</sup>  
Fariba Ghassemi, MD<sup>3</sup> • Hormoz Chams, MD<sup>2</sup> • Ahmad Javadian, MD<sup>2</sup> • Ali Abdollahi, MD<sup>1</sup>

---

---

### Abstract

**Purpose:** The objective of this study was to investigate the causes, the clinical presentation, and treatment modalities in patients with valsalva premacular hemorrhage.

**Methods:** This case series study included 21 eyes of 21 patients referred to retina clinic of Farabi eye hospital and two private eye clinics during 2001-2006 with sudden loss of vision and clinical diagnosis of premacular hemorrhage due to valsalva retinopathy. Nd:YAG laser Hyaloidotomy was performed in 16 eyes with larger than 3 disc diameter (DD) hemorrhage in size and enough depth of hemorrhage pocket (dome-shaped) and conservative approach in 5 eyes with smaller than 3 DD in size. Main outcome measures including cause of valsalva premacular hemorrhage based on the history, success rate in performing hyaloidotomy, release of the entrapped blood into the vitreous cavity and the duration of its resorption, spontaneous resorption in observed cases, postoperative improvement in visual acuity (VA), additional intervention such as vitrectomy, and postoperative complications were recorded and analyzed.

**Results:** Premacular hemorrhage was a result of vigorous sexual activity in 10 patients (47.6%), heavy lifting in 2 (9.5%), end stage labor in 2 (9.5%), compressive trauma in 1 (4.7%), straining on toilet in 2 (9.5%), roller coaster riding in 1 (4.7%), sneezing in 1 (4.7%), and occurred during sleep or unknown in 1 (4.7%). Nd:YAG laser Hyaloidotomy was successful in (87.5%) of patients with large size hemorrhage and trapped blood was released in to vitreous cavity and absorbed within 6-23 (mean 14.5±5.1) days. In observed patients, spontaneous resorbtion of trapped blood was occurred within 21-83 (mean 47.2±22.8) days. No predisposing factor was seen in patients. During the follow-up of 38.47±19.2 months, an epiretinal membrane formation was seen in 1 eye. 85.7% of patients in laser group gained full vision.

**Conclusion:** In our study, vigorous sexual activity was the most common cause of valsalva premacular hemorrhage. Nd:YAG laser Hyaloidotomy was a safe and simple procedure in patients with hemorrhage occupied more than 3 DD in size and enough depth of hemorrhage pocket (dome-shaped) and caused visual recovery in majority of patients.

**Keywords:** Premacular Hemorrhage, Valsalva Retinopathy

---

*Iranian Journal of Ophthalmology 2009;21(3):11-16 © 2009 by the Iranian Society of Ophthalmology*

---

1. Associate Professor of Ophthalmology, Eye Research Center, Farabi Eye Hospital, Tehran University of Medical Sciences
2. Professor of Ophthalmology, Eye Research Center, Farabi Eye Hospital, Tehran University of Medical Sciences
3. Assistant Professor of Ophthalmology, Eye Research Center, Farabi Eye Hospital, Tehran University of Medical Sciences

Received: March 4, 2009

Accepted: July 16, 2009

Correspondence to: Ahmad Mirshahi, MD

Eye Research Center, Farabi Eye Hospital, Tehran, Iran, Tel:+98 21 55414941-6, Email: mirshahi@tums.ac.ir

## Introduction

The valsalva's maneuver was named after the Italian anatomist Antonio Maria Valsalva (1666-1723) who defined the valsalva ligaments and anatomy related to the forcible exhalation effort against a closed glottis.<sup>1</sup>

In this manner, creating a sudden rise intrathoracic and intrabdominal pressure may cause a rapid increase in venous pressure with spontaneous rupture of perifoveal retinal capillaries (Valsalva retinopathy) leading to a sudden painless loss of vision.<sup>2,3</sup> Valsalva retinopathy often occurs in healthy young adults as a result of heavy lifting, constipation (straining on toilet), vomiting, coughing (in asthma), sneezing, labors, automobile air-bag related trauma, vigorous sexual activity, vigorous dancing, bungee jumping, comprehensive injuries and is also associated with fiberoptic gastroenteroscopy, colonoscopy procedure and continuous positive pressure ventilation.<sup>4-14</sup>

Although spontaneous clearing of premacular hemorrhage in Valsalva retinopathy is possible but in most cases may take months and may result in permanent visual impairment due to pigmentary macular changes or formation of preretinal membranes and toxic damage to retina due to prolonged contact with hemoglobin and iron. Therapeutic options available include, pneumatic displacement of hemorrhage by intravitreal injection of gas and tissue plasminogen activator, vitrectomy and laser Hyaloidotomy (Nd:YAG laser or argon green laser).<sup>15-24</sup> The objective of this study was to investigate clinical features, etiologies and management of patients with premacular hemorrhage due to Valsalva retinopathy.

## Methods

This case series study included 21 eyes of 21 patients with sudden loss of vision due to Valsalva retinopathy enrolled from 2001 to 2006 in Farabi eye hospital, Tehran, Iran and two private clinics. Diagnosis of Valsalva retinopathy was based on the history, clinical examination, fundus findings and fluorescein angiography in selected cases to rule out the other causes of preretinal hemorrhage and if there was a history of trauma or any medical disorders, subjects were excluded. Pre and post-treatment examinations included best corrected visual acuity (BCVA), slit-lamp

biomicroscope examination, intraocular pressure; funduscopy and color fundus photography were taken to measure the size of the premacular hemorrhage by comparing with optic disc dimensions. Maximal midriasis by tropicamide eye drop and topical anesthesia with tetracaine (0.5%) was applied. Nd:YAG laser Hyaloidotomy was applied in patients with premacular subhyaloid hemorrhage beyond 3 disc diameter (DD) in size as judged by color fundus photographs and enough depth of hemorrhagic pocket. Through a slit-lamp and a Goldman three-mirror lens or centralis lens, (Volk) laser beam was aimed at the lowermost dependent part of the blood-containing premacular (subhyaloid or subinternal limiting membrane (ILM)) pocket, in order to enhance the blood release process and better protection of the underlying retina with an average total mean energy of  $24 \pm 10.64$  MJ (range: 11 to 45 MJ). Timing of laser therapy was 1 to 120 days after onset of symptoms. No intervention was done for cases smaller than 3 DD hemorrhage in size. Patients were followed until the end of the study for  $38.47 \pm 19.2$  days (range: 6 to 69 months), and regular examination was performed at 2nd day, 1st week, 2nd week, and 1 month after procedure. The main outcome was measured regarding causes of Valsalva premacular hemorrhage based on the history of patients, success rate in hyaloidotomy based on opening the vitreoretinal interface and releasing the entrapped blood into the vitreous cavity, duration of its resorption, spontaneous resorption in observed cases, postoperative improvement in visual acuity (VA), additional intervention such as vitrectomy, and postoperative complications.

## Results

Patients were 11 female (52.4%) with mean age of  $34.05 \pm 11$  years (range: 18 to 65 years). Sudden visual loss was the chief complain of all patients.

The cause of their premacular hemorrhage was vigorous sexual activity in 10 patients (47.6%) heavy lifting in 2 (9.5%), labor in 2 (9.5%), compressive trauma in 1 (4.7%), straining on toilet in 2 (9.5%), roller coaster riding in 1 (4.7%), sneezing in 1 (4.7%), and occurred during sleep or unknown, each in 1

(4.7%). Nd:YAG laser Hyaloidotomy was successful in 14 of 16 (87.5%) patients with the mean pretreatment hemorrhage measured  $4.43 \pm 0.81$  (range 3-6 DD). The trapped blood was released into the vitreous cavity and was resorbed after a mean period of  $14.5 \pm 5.1$  (6 to 23) days. Five patients with small size hemorrhage were managed conservatively. Spontaneous resorbtion of trapped

hemorrhage was within 21-83 days (mean  $47.2 \pm 22.8$  days) which was significantly more than the procedure group ( $P=0.032$ ). Preoperative VA in the affected eyes of these patients ranged from hand motion to counting fingers at 3 meters, which was improved from  $20/50$  to  $20/20$  postoperatively. Table 1 summarizes patients' characteristics and postoperative results.

**Table 1.** Patients characteristics and postoperative results

Patients	Sex/Age	Cause of valsalva	Size of hemorrhage (DD)	Duration of hemorrhage (D)	Total energy MJ	Nd:YAG laser	Duration of resorbtion (D)	Visual acuity	
								Before treatment	Final
1	M/35	Vigorous sexual activity	4	1	25	+	6	FC	$20/20$
2	F/44	Vigorous sexual activity	6	7	15	+	16	HM	$20/20$
3	F/31	Vigorous sexual activity	5	4	20	+	14	HM	$20/20$
4	F/18	Roller coaster riding	5	3	11	+	18	HM	$20/20$
5	M/40	Heavy lifting	2	1	-	-	38	FC	$20/20$
6	F/32	Vigorous sexual activity	4	2	26	+	8	FC	$20/20$
7	M/48	Vigorous sexual activity	3	120	11	+	12	FC	$20/25$
8	M/46	Staring on toilet	2	8	-	-	21	FC	$20/20$
9	M /40	Sneezing	4	3	26	+	22	FC	$20/20$
10	M/39	Straining on toilet	4	1	18	+	13	HM	$20/20$
11	F/24	Vigorous sexual activity	5	3	26	+	17	HM	$20/20$
12	M/25	Heavy lifting	2	3	-	-	51	FC	$20/20$
13	F/41	Compressive	4	2	35	+	12	FC	$20/20$
14	M/26	Vigorous sexual activity	2	7	-	-	83	FC	$20/25$
15	F/23	Vigorous sexual activity	4	3	26	+	23	FC	$20/20$
16	F/22	In sleep	5	1	11	+	18	HM	$20/25$
17	F/30	Labor	3	2	26	+	8	FC	$20/20$
18	M/26	Vigorous sexual activity	5	7	45	+(Vitrectomy)	-	HM	$20/20$
19	M/31	Vigorous sexual activity	2	3	-	-	43	FC	$20/25$
20	F/65	Unknown	5	17	18	+	16	HM	$20/20$
21	F/28	Labor	5	6	45	+(vitrectomy)	-	HM	$20/25$

An epiretinal membrane formation was noted in one case (no 16) during the average follow-up of  $38.47 \pm 19.2$  months.

Vitrectomy was performed for 2 patients due to a clot hemorrhage that refused to drain into the vitreous despite an opening at the vitreoretinal interface. Twelve out of fourteen patients (85.7%) in laser group and overall 16 out of 21 (76.2%) had complete visual recovery.

## Discussion

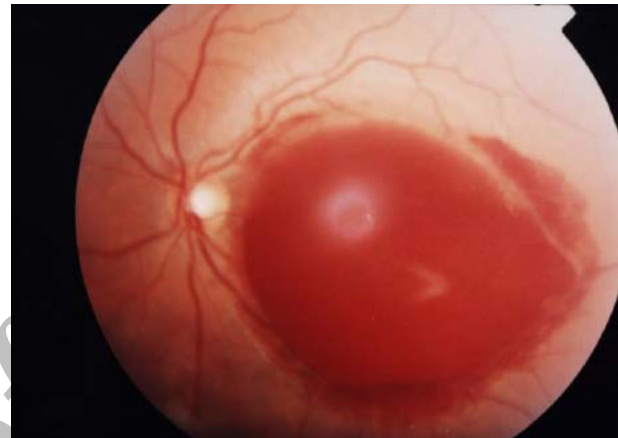Therapeutic options available for vasa retinae include observation, pneumatic displacement of hemorrhage by intravitreal injection of gas and tissue plasminogen activator, vitrectomy and laser (Nd:YAG laser, argon green and krypton laser).<sup>5-24</sup> Previously, in a pilot study we evaluated Nd:YAG laser Hyaloidotomy in 12 patients with premacular subhyaloid hemorrhage with different etiologies. Hyaloidotomy was successful in all (100%) of patients with best visual improvement in vasa retinae<sup>21</sup> but this study was conducted on a homogenous sample of 21 patients with premacular hemorrhage.

Posterior hyaloidotomy was performed in 16 cases with large size hemorrhage (beyond 3 DD) with success in 14 individuals (87.5%) (Figure 1). Based on experience of Ulbig and colleagues that identified macular hole as a complication of laser hyaloidotomy possibly due to photodestructive effect of laser too close to the macula in small size hemorrhage,<sup>17</sup> we observed 5 patients with small size hemorrhage without any intervention. The duration of absorption and clearance of hemorrhage was between 6-23 days (mean 14.5 days) in intervention group and it was between 20-83 (mean 47.2 days) in observed group ( $P= 0.032$ ).

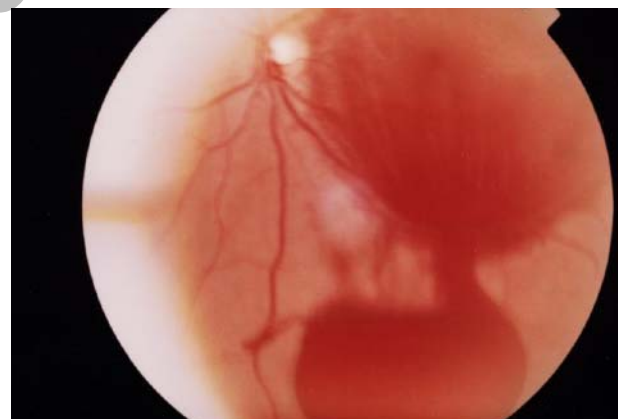
This is in accordance with Rennie<sup>16</sup> et al's findings. They evaluated 10 patients with premacular subhyaloid hemorrhage of different etiologies. Nd:YAG laser Hyaloidotomy was performed in 6 patients while 4 patients were managed conservatively. Nd:YAG laser Hyaloidotomy achieved rapid resolution of subhyaloid hemorrhage in laser group and no patient had evidence of damage to the retina or choroid.

Nevertheless, among the conservatively managed cases, 3 had slow resolution of

hemorrhage over 3 to 6 months and one with proliferative diabetic retinopathy (PDR), in 18 months. In our study, 2 eyes underwent additional vitrectomy due to a clot hemorrhage which was not drained into the vitreous. It seems that the pretreatment duration of the hemorrhage is a major prognostic factor. An epiretinal membrane formed in one case during follow-up (Figure 2).

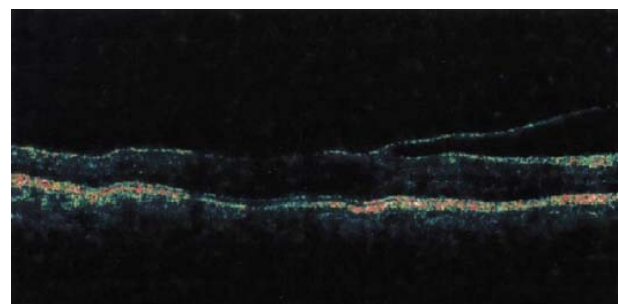


A



B

**Figure 1.** Premacular hemorrhage before treatment (A) and immediately after Nd:YAG laser Hyaloidotomy (B)



**Figure 2.** Epiretinal membrane in OCT

Twelve out of fourteen patients (85.7%) in successful laser group in our study had complete visual recovery (BCVA  $^{20}/_{20}$ ). One of our patients with long duration of valsalva premacular hemorrhage (with duration of 4 months) had a yellow color change of hemorrhage (Figure 3) as was mentioned in other studies.<sup>17</sup>

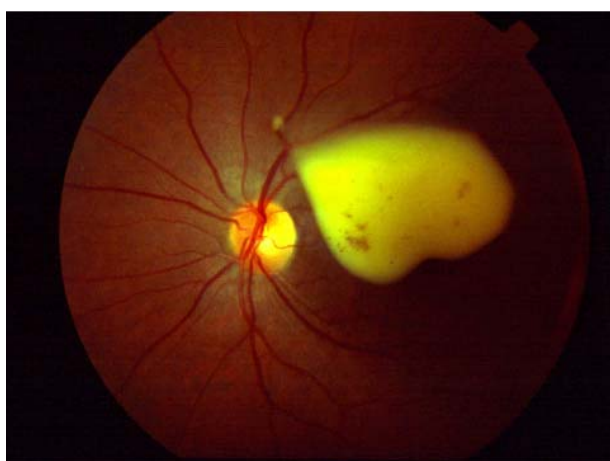

Figure 3. Longstanding premacular hemorrhage

## Conclusion

Considering the result of this study, vigorous sexual activity was the most common cause of valsalva premacular hemorrhage, and Nd:YAG laser Hyaloidotomy was a simple inexpensive outpatient procedure which is relatively safe, and results in rapid recovery as well as good visual outcomes in majority of patients with valsalva retinopathy. This technique can prevent long term entrapment of blood causing adverse effects on macula including potential permanent visual impairment. Although most articles have applied subhyaloid term in relation to valsalva retinopathy, this seems not to be accurate all the time, and it should be revised. According to endless debate on the location of hemorrhage and lack of histological proof, we suggest the nonspecific elder terminology of valsalva premacular hemorrhage for this entity. This term seems more general, and includes both subhyaloid and sub ILM hemorrhage.

## References

1. Jones WL. Valsalva maneuver induced vitreous hemorrhage. *J Am Optom Assoc* 1995;66(5):301-4.
2. Duane TD. Valsalva hemorrhagic retinopathy. *Am J Ophthalmol* 1973;75(4):637-42.
3. Duane TD. Valsalva hemorrhagic retinopathy. *Trans Am Ophthalmol Soc* 1972;70:298-313.
4. Cheung CM, Durrani OM, Kirkby GR. Sudden visual loss in asthma. *J R Soc Med* 2002;95(7):359.
5. Callender D, Beirouty ZA, Saba SN. Valsalva hemorrhagic retinopathy in a pregnant woman. *Eye* 1995;9(Pt 6):808-9.
6. Deane JS, Ziakas N. Valsalva retinopathy in pregnancy. *Eye* 1997;11(Pt 1):137-8.
7. Ladjimi A, Zaouali S, Messaoud R, et al. Valsalva retinopathy induced by labour. *Eur J Ophthalmol* 2002;12(4):336-8.
8. Choi SW, Lee SJ, Rah SH. Valsalva retinopathy associated with fiberoptic gastroenteroscopy. *Can J Ophthalmol* 2006;41(4):491-3.
9. Roberts DK, MacKay KA. Microhemorrhagic maculopathy associated with aerobic exercise. *J Am Optom Assoc* 1987;58(5):415-8.
10. Friberg TR, Braunstein RA, Bressler NM. Sudden visual loss associated with sexual activity. *Arch Ophthalmol* 1995;113(6):738-42.
11. Georgiou T, Pearce IA, Taylor RH. Valsalva retinopathy associated with blowing balloons. *Eye* 1999;13(Pt 5):686-7.
12. Fanin LA, Thrasher JB, Mader TH, Truxal AR. Valsalva retinopathy associated with transrectal prostate biopsy. *Br J Urol* 1994;74(3):391-2.
13. Oboh AM, Weilke F, Sheindlin J. Valsalva retinopathy as a complication of colonoscopy. *J Clin Gastroenterol* 2004;38(9):793-4.

14. Bar-Sela SM, Moisseiev J. Valsalva retinopathy associated with vigorous dancing in a discotheque. *Ophthalmic Surg Lasers Imaging* 2007;38(1):69-71.
15. Raymond LA. Neodymium: YAG laser treatment for hemorrhages under the internal limiting membrane and posterior hyaloid face in the macula. *Ophthalmology* 1995;102(3):406-11.
16. Rennie CA, Newman DK, Snead MP, Flanagan DW. Nd:YAG laser treatment for premacular subhyaloid hemorrhage. *Eye* 2001;15(Pt 4):519-24.
17. Ulbig MW, Mangouritsas G, Rothbacher HH, et al. Long-term results after drainage of premacular subhyaloid hemorrhage into the vitreous with a pulsed Nd:YAG laser. *Arch Ophthalmol* 1998;116(11):1465-9.
18. Celebi S, Kükner AS. Photodisruptive Nd:YAG laser in the management of premacular subhyaloid hemorrhage. *Eur J Ophthalmol* 2001;11(3):281-6.
19. Gabel VP, Birngruber R, Gunther-Koszka H, Puliafito CA. Nd:YAG laser photodisruption of hemorrhagic detachment of the internal limiting membrane. *Am J Ophthalmol* 1989;107(1):33-7.
20. Bourne RA, Talks SJ, Richards AB. Treatment of preretinal valsalva hemorrhages with neodymium:YAG laser. *Eye* 1999;13(Pt 6):791-3.
21. Nili-Ahmadabadi M, Lashay AR, Karkhaneh R, et al. Nd:YAG laser application in premacular subhyaloid hemorrhage. *Arch Iranian Med* 2004;7(3):206-9.
22. Chen YJ, Kou HK. Krypton laser membranotomy for premacular hemorrhage. *Ophthalmologica* 2004;218(6):368-71.
23. Conway MD, Peyman GA, Recasens M. Intravitreal tPA and SF6 promote clearing of premacular subhyaloid hemorrhages in shaken and battered baby syndrome. *Ophthalmic Surg Lasers* 1999;30(6):435-41.
24. Kwok AK, Lai Ty, Chan NR. Epiretinal membrane formation with internal limiting membrane wrinkling after Nd:YAG laser membranotomy in valsalva retinopathy. *Am J Ophthalmol* 2003;136(4):763-6.

Archive of SID