

Assessment of VEGF, CD-31 and Ki-67 Immunohistochemical Markers in Oral Pyogenic Granuloma: A Comparison with Hemangioma and Inflammatory Gingivitis

¹Shadi Saghafi, ^{*2}Sakineh Amoueian, ³Mehdi Montazer, ⁴Roshanak Bostan

Abstract

Objective(s)

The aim of this study was to evaluate the expressions of two angiogenic immune-markers (CD-31 and VEGF), and one proliferative immune-marker (Ki-67) in oral pyogenic granulomas (PG), hemangiomas (Hem) and inflammatory gingivitis (IG).

Materials and Methods

Sixty cases of PG, Hem and IG (twenty cases each) were examined. Immunohistochemical (IHC) staining was performed based on routine techniques. The microvessel density (MVD) index was also evaluated.

Results

The male to female ratio was 1:2. The mean age was 33.3 years old (± 20.52). The reactivity percentages for all three markers (CD-31, VEGF and Ki-67) were significantly higher in PG compared to Hem (56.8%, 13.8% and 23.0% vs. 28.3%, 7.0% and 5.4%, respectively). The mean MVD in PG was also significantly higher than in Hem (26.1 ± 0.11 vs. 13.6 ± 0.08). There was no statistically significant difference between PG and IG.

Conclusion

The current study supports the common nature of pyogenic granulomas and inflammatory gingivitis.

Keywords: CD31, Gingivitis, Hemangioma, Ki-67 Antigen, Pyogenic Granuloma, VEGF

1- Department of Oral Pathology, Mashhad University of Medical Sciences, Mashhad, Iran

2- Imam-Reza Hospital, Mashhad University of Medical Sciences, Mashhad, Iran

*Corresponding author: Tel: +98-511-802 22 34, Fax: +98-511-859 10 57, email: amouians@mums.ac.ir

3- Department of Pathology, Mashhad University of Medical Sciences, Mashhad, Iran

4- Mashhad University of Medical Sciences, Mashhad, Iran

Introduction

Angiogenesis, described as the formation of new blood vessels, is a basic natural process that occurs in both physiologic (e.g. wound healing, menstruation) and pathologic (e.g. diabetic retinopathy) conditions. Angiogenesis is controlled through a series of stimulating and inhibitory factors that tightly cooperate in order to maintain the homeostasis of angiogenesis. Alterations in this regulatory process may lead to insufficient (e.g. coronary artery disease or stroke) or excessive angiogenesis (e.g. vascular tumors such as pyogenic granulomas and hemangiomas) (1).

Pyogenic granulomas (PG) are relatively common rapidly growing acquired vascular tumors that mostly occur on the skin and gingival/oral mucosa. They are characterized by the proliferation of capillary-sized vessels along with extensive edema and abundant granulation tissue formation. Hemangiomas (Hem) are in the differential diagnosis of pyogenic granulomas, but they show more plump endothelial cells and they lack the granulation tissue. Nevertheless, they have a very similar histological morphology. On the other hand, pyogenic granuloma shares some histological findings with inflammatory gingivitis (IG) that put IG among PG's differential diagnosis (2).

Attempts have been made to differentiate these lesions utilizing immunohistochemical (IHC) staining; but to date no definite comprehensive IHC panel has been recommended and the results of the few available studies are controversial. Not surprisingly, PG varies within a spectrum with Hem as a neoplastic lesion in one end, and IG as an inflammatory reactive lesion in the other. IHC based studies may also help to understand the supposed mechanisms underlying these disorders (neoplastic vs reactive) (3-7).

In this study, we investigated the expression of two angiogenic markers (CD-31 and vascular endothelial growth factor, VEGF), and one proliferative marker (Ki-67) in PG, Hem and IG.

Materials and Methods

Patients and samples

Twenty cases of PG, twenty cases of Hem, and twenty cases of IG were collected from the Department of Oral Pathology, Mashhad University of Medical Sciences in the year 2008.

Specimens with inadequate tissue or insufficient fixation were excluded from the study.

Immunohistochemical staining

We performed immunohistochemical staining for CD-31, VEGF and Ki-67. CD-31, also known as platelet endothelial cell adhesion molecule-1 (PECAM-1), and VEGF are angiogenic markers widely used to identify vascular formations especially for the assessment of angiogenesis in pathologic phenomena. Anti-Ki-67 antibody recognizes a proliferation specific nuclear antigen. Ki-67 is routinely used as an index for cellular proliferation and activity (8).

Three- μ m-thick sections of representative formalin-fixed, paraffin-embedded tissue specimens were prepared. The sections were mounted on clean slides, previously coated with poly-L-lysine adhesive, then deparaffinized using Xylene and rehydrated in graded alcohols. Thereafter, the endogenous peroxidase was deactivated by soaking the slides in H₂O₂/Methanol solution. Antigen retrieval was done using trypsin. Afterwards, streptavidin-biotin method was conducted for immunostainings. IHC antibodies were purchased from Dako Corporation: the anti-CD-31 (clone JC/70A, Dako Corporation, North America, USA), the anti-VEGF (clone VG1, Dako Corporation, Glostrup, Denmark) and the anti-ki-67 (clone MIB-1, Dako Corporation, North America, USA). All immunostaining processes were carried based on the manufacturers' recommendations. Finally, the slides were counterstained with hematoxylin. Positive control samples were consisted of colorectal tissue for CD-31 and VEGF markers, and tonsillar lymphoid tissue for Ki-67. Tissue sections without non-immune antibody served as the negative controls.

Immunohistochemistry interpretation

Two pathologists examined each slide independently. CD-31 and VEGF were expressed in both membrane and cytoplasm, while Ki-67 was expressed in the nucleus. The percentages of reactive endothelial cells (vs non-reactive endothelial cells) in five high power fields for CD-31/VEGF, and in one hundred cells for Ki-67 were noted.

The MicroVessel Density (MVD) index was also evaluated as described by Behrem *et al* (9)

using CD-31 stained slides. First, the tissue was screened at low power (40 \times) to identify areas of the highest vascularization. Second, vessels were counted in three such high density areas at high power magnification (400 \times). The average of the MVD counted by two independent observers was considered as the MVD of each individual lesion.

Statistical analysis

Reactivity percentages for IHC markers and MVD index were compared among the three groups corresponding PG, Hem, and IG using ANOVA test. Tukey *post hoc* test was used to make all the pair wise comparisons between these groups. Similar comparison was also made between capillary and cavernous hemangiomas conducting t-test. The data was analyzed using SPSS version 10.0.1. The significance level was set at 0.05.

Results

Patients consisted of 20 (33.3%) males and 40 (66.6%) females with a mean (standard deviation, SD) age of 33.3 years old (20.52). The groups were statistically matched for age and sex ($P > 0.05$).

An example of the performed immunostainings is demonstrated in Figure 1.

Table 1 shows the summary statistics for reactivity percentages of CD-31, VEGF and Ki-67. Reactivity for all three IHC markers was

significantly different for the three lesion types.

However, the *post hoc* analysis revealed that the differences of Hem from PG and IG were responsible for most of this variability. In fact, no statistically significant difference between PG and IG was discovered.

For angiogenesis markers of CD-31 and VEGF, the reactivity percentages in PG were twice their reactivity in Hem (56.8% and 13.8% vs. 28.3% and 7.0%, respectively) ($P = 0.000$ and $P = 0.046$, respectively). Likewise, the positivity for proliferating marker of Ki-67 in PG was more than four times higher than Hem (23.0% vs 5.4%) ($P = 0.000$). VEGF and Ki-67 were absent in two cases of Hem. As mentioned earlier, there were no statistical and clinical significant differences between PG and IG regarding the IHC markers.

Mean (95% confidence interval) microvascular densities in PG, Hem and IG were 26.1 (21.1-31.1), 13.6 (9.7-17.4) and 32.2 (27.2-37.1) respectively ($P < 0.001$).

Like IHC markers, the found difference was mainly associated with the difference between Hem with the other two lesions. No difference was seen between PGs and IGs. Mean (\pm SD) MVD in PG was double the one in Hem (26.1 ± 0.11 vs 13.6 ± 0.08).

Amongst twenty hemangiomas investigated, there were nine capillary and eleven cavernous hemangiomas. They were completely similar in CD-31, VEGF, Ki-67 expression and MVD count ($P > 0.05$).

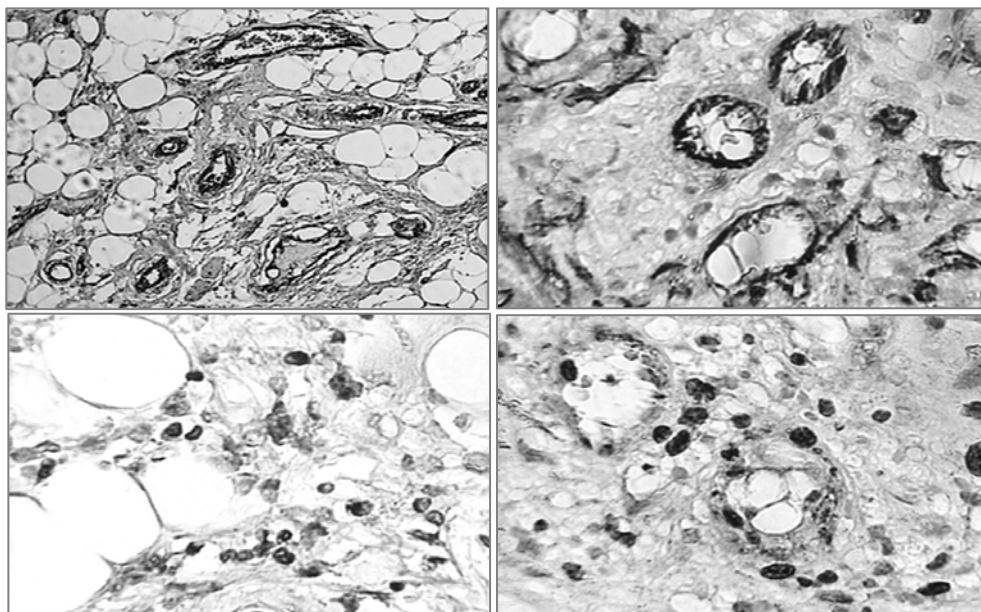


Figure 1. Immunohistochemistry staining for CD-31 (above) and Ki-67 (bottom) in pyogenic granuloma (right) and hemangioma (left).

Table 1. Reactivity percentages of CD-31, VEGF and Ki-67 in PG, Hem and IG

Antibody	Lesion	N	Mean	Standard deviation	95% Confidence interval for mean		F	P-value
					Lower bound	Upper bound		
VEGF	PG	20	13.8	12.40	8.00	19.6	7.125	.002
	Hem	20	7.0	5.83	4.3	9.7		
	IG	20	17.4	6.71	14.2	20.5		
CD-31	PG	20	56.8	21.31	46.9	66.8	19.348	.000
	Hem	20	28.3	13.87	21.8	34.8		
	IG	20	63.4	20.78	53.6	73.1		
Ki-67	PG	20	23.0	12.00	17.4	28.7	17.257	.000
	Hem	20	5.4	6.65	2.2	8.5		
	IG	20	19.6	10.89	14.6	24.8		

*PG= Pyogenic granuloma, Hem=Hemangioma, IG= Inflammatory gingivitis.

Discussion

Pyogenic granulomas are benign inflammatory lesions displaying remarkable vascularization. They may present in any age, but they are most prevalent in the second decade of life with female predominance (2). The results of our study also confirms this information (overall, 66% female; third decade of life). Few studies, such as Toida *et al* have reported an older mean age of 52.7 years (10).

Pyogenic granulomas are typically solitary nodules showing a tendency towards head and neck and extremities especially fingers. However, reports exist from uncommon sites such as, iliac vein, larynx, liver, etc. Moreover, rare multiple or recurrent PGs have been described in the literature (11-15).

The pathogenesis of PG remains to be fully understood. It has been discovered that there is a conceivable linkage between PG and chronic physical injuries (e.g. trauma, burns), insofar as almost one-third of PGs occur after such traumas. It is proposed that these injuries may act as potential stimuli that activate the healing and repair response leading to inappropriate and falsely regulated inflammation, angiogenesis, hyperplasia and consequently, improper granulation tissue formation; the hallmark of PG histopathology. Thus, PGs are suggested to be more reactive rather than neoplastic (2). Although, convincing scientific evidence does not exist.

Based on these considerations, it becomes clear that either inflammatory response or angiogenesis can play a role in pathogenesis of PG. As a result, both inflammatory gingivitis (non- neoplastic) and hemangiomas (neoplastic)

are in the differential diagnosis of PG. Unfortunately, these lesions also share a very similar histopathology and it is sometimes too hard to differentiate these lesions exclusively based on histological examination (2). In such conditions, IHC may provide some practical help. Furthermore, IHC may shed light on the putative underlying mechanisms of these lesions' pathogenesis (reactive vs. neoplastic).

In the current study, not only the expression of CD-31, VEGF and Ki-67 were significantly different between PG and Hem, but also there was a difference in their mean MVDs. These findings support the commonly believed different pathogenesis of these lesions. Besides, no difference was detected between PG and IG, confirming their common origin.

According to Dyduch *et al*, the VEGF reactivity and proliferative index (Ki-67) were higher in PG compared to Hem, to the point that the median of VEGF reactivity in the PG group was 10%-50% (++) while it was negative (-) in the Hem group. They also observed that the mean Ki-67 expression in PG was about three times higher than Hem. (14.13 vs 4.85) (3). However, in an antecedent study, the same authors, had discovered that the expression of Ki-67 did not differ significantly between these lesions (4). Nakamura also found that there was no difference in ki-67 expression between the lesions (5).

In the study conducted by Freitas *et al*, VEGF expression and microvessel density (MVD) using CD-31 were not significantly different between PG and Hem. However, the mean number of VEGF-positive cells in PG was higher compared to oral hemangioma

specimens (153.23 vs 115.17) (6). They concluded that neither VEGF immunostaining nor MVD quantification are not useful in the differential diagnosis of these lesions. In contrary, Yuan *et al* have reported the VEGF was more expressed in PG than healthy gingiva and periodontitis (7).

Conclusion

Our investigation supports the reactive nature

of pyogenic granulomas. We recommend immunohistochemistry staining as a practical and efficient technique in order to differentiate pyogenic granulomas from hemangiomas.

Acknowledgment

This research project was the graduation thesis of Dr Bostan to obtain her degree in dentistry. Mashhad University of Medical Sciences, Mashhad, Iran supported and financed the study.

References

1. Cohen M, Michel Jr. Vasculogenesis angiogenesis, hemangiomas, and vascular malformations. *Am J Med Genet* 2002; 108:265- 274.
2. Jafarzaddeh H, Sanatkhani M, Mohtasham N. Oral pyogenic granuloma: a review. *J Oral Sci* 2006; 48:167-175.
3. Dyduch G, Okoń K, Mierzyński W. Benign vascular proliferations--an immunohistochemical and comparative study. *Pol J Pathol* 2004; 55:59-64.
4. Dyduch G, Okoń K. Proliferation and apoptosis within the oral mucosa "hemangiomas". *Pol J Pathol* 2000; 51:93-96.
5. Nakamura T. Apoptosis and expression of Bax/Bcl-2 proteins in pyogenic granuloma: a comparative study with granulation tissue and capillary hemangioma. *J Cutan Pathol* 2000; 27:400-405.
6. Freitas TM, Miguel MC, Silveira EJ, Freitas RA, Galvão HC. Assessment of angiogenic markers in oral hemangiomas and pyogenic granulomas. *Exp Mol Pathol* 2005; 79:79-85.
7. Yuan K, Jin YT, Lin MT. The detection and comparison of angiogenesis-associated factors in pyogenic granuloma by immunohistochemistry. *J Periodontol* 2000; 71:701-709.
8. Bishop PW. An immunohistochemical vade mecum. Version date May 2010. Available at: www.e-immunohistochemistry.info. Last accessed: 20 August 2010.
9. Behrem S, Zarkovic K, EsKinja N, Joujic N. Endoglin is a better marker than CD31 in evaluation of angiogenesis in glioblastoma. *Croat Med J* 2005; 46:417- 422.
10. Toida M, Hasegawa T, Watanabe F, Kato K, Makita H, Fujitsuka H, *et al*. Lobular capillary hemangioma of the oral mucosa: clinicopathological study of 43 cases with a special reference to immunohistochemical characterization of the vascular elements. *Pathol Int* 2003; 53:1-7.
11. Pradhan S, Bazan H, Salem R, Gusberg RJ. Intravenous lobular capillary hemangioma originating in the iliac veins: a case report. *J Vasc Surg* 2008; 47:1346-1349.
12. Walner DL, Parker NP, Kim OS, Angeles RM, Stich DD. Lobular capillary hemangioma of the neonatal larynx. *Arch Otolaryngol Head Neck Surg* 2008; 134:272-277.
13. Abaalkhail F, Castonguay M, Driman DK, Parfitt J, Marotta P. Lobular capillary hemangioma of the liver. *Hepatobiliary Pancreat Dis Int* 2009; 8:323-325.
14. Alotaibi HM. An unusual association of recurrent pyogenic granuloma on nevus flammeus in a patient with Von Recklinghausen's disease. *Saudi Med J* 2009; 30:844-846.
15. Ceyhan AM, Basak PY, Akkaya VB, Yildirim M, Kapucuoglu N. A case of multiple, eruptive pyogenic granuloma developed on a region of the burned skin: can erythromycin be a treatment option? *J Burn Care Res* 2007; 28:754-757.