

Successful Pregnancy Following Myomectomy for Giant Uterine Fibroid in an Infertile Woman

Euzebus Chinonye Ezugwu^{1*}, Chukwuemeka Anthony Iyoke¹, Frank Okechukwu Ezugwu², George Ugwu^{1,2}

1- Department of Obstetrics and Gynaecology, University of Nigeria, Teaching Hospital, Enugu State, Nigeria

2- Department of Obstetrics and Gynaecology, Enugu State University, Teaching Hospital, Enugu state, Nigeria

Abstract

Background: Giant uterine fibroid is a rare tumor of the uterus, usually symptomatic requiring surgical intervention. Uterine fibroid is generally common among black women.

Case Presentation: In this study, a case of 31 year old nullipara was reported who presented to the Gynaecology unit of Enugu State University Teaching Hospital (ESUTH), Nigeria with a history of progressive abdominal swelling of 8 years duration, six years duration of infertility and weight loss and dyspnoea on exertion. Physical examination and transabdominal ultrasound revealed a huge abdominopelvic mass. She had myomectomy. She had a histologically confirmed giant uterine fibroid that weighed 16.8 kg. She subsequently achieved a live birth.

Conclusion: Giant uterine fibroids are relatively rare. It poses great challenges in its management. The surgical option of management should consider the fertility preservation and aspiration of couples especially in developing countries.

Keywords: Giant leiomyoma, Giant uterine fibroid, Infertility, Myomectomy, Nigeria

To cite this article: Ezugwu EC, Iyoke CA, Ezugwu FO, Ugwu G. Successful Pregnancy Following Myomectomy for Giant Uterine Fibroid in an Infertile Woman. *J Reprod Infertil.* 2014;15(4):233-236.

* Corresponding Author:
Euzebus Chinonye
Ezugwu, Department of
Obstetrics and Gynaecology
University of Nigeria
Teaching Hospital, Itukku-
Ozalla PMB 01129,
Enugu State, Nigeria
E-mail:
ezugwuezebus@yahoo.
com

Received: May. 22, 2014

Accepted: Jun 17, 2014

Introduction

Giant uterine leiomyomata are those tumors weighing 11.4 kg or more. Giant uterine fibroids are rare and usually symptomatic. Uterine leiomyomata are the commonest benign tumors of the female reproductive tract arising from smooth muscle cells of the uterus. They may be single or multiple and of varying sizes. The tumors are 2-3 times commoner in blacks than white women. It is estimated that by their fifth decade, as many as 50% of black women will have leiomyomata (1, 2).

Although uterine leiomyomata are asymptomatic in 50% of cases, they may cause menorrhagia, dysmenorrhoea, abdominal swelling and pressure symptoms (3). It is a common gynaecological tumor in Nigeria (4, 5). In Enugu, Nigeria, symptomatic uterine fibroid makes up 9.8% of gynaecological admissions (5). Although there have been reports of giant uterine fibroid from different

parts of the world, our literature search did not yield any previous report of giant uterine fibroid from the south eastern region of Nigeria. In this study, a case of a nullipara was reported who had a giant uterine fibroid which was managed by a myomectomy and the woman subsequently achieved a live birth.

Case Presentation

A 31 year old nulliparous housewife presented initially to the Gynaecology unit of Enugu State University Teaching Hospital (ESUTH), Nigeria in February 2012 with a history of progressive abdominal swelling of 8 years duration, six years duration of infertility and weight loss and dyspnoea on exertion. Her menstrual cycle was regular and menstrual flow was moderate. She had been diagnosed to have uterine fibroid 6 years prior to presentation and had refused to have surgery due

to her belief that the fibroid and infertility were spiritually inflicted on her by her enemies. She took local medications with the belief that it would dissolve the fibroid.

Physical examination revealed a cachectic woman, who was pale and had a massively protuberant abdomen. The pulse rate was 96 beats per minute and blood pressure was 110/70 mmHg. The respiratory rate was 18 cycles per *min*. There was a firm nodular abdominal mass measuring 52 cm from the pubic symphysis to the epigastrium. The mass also extended to both flanks (Figure 1). Pelvic examination revealed normal cervix with both adnexae filled with nodular masses.

The patient had hemoglobin level of 7.3 g/dl (PCV=22%). Serum urea, electrolyte and creatinine level were within the normal limit. A trans-abdominal ultrasound scan showed multiple large masses resembling fibroid. The marker of CA-125, CT Scan and MRI could not be done due to their cost and unavailability.

She was counseled for surgery. She consented to myomectomy with an option of hysterectomy as a life saving procedure, as she desired to have children. She was transfused with three units of packed cells prior to surgery. Intra-operative findings included very thin subcutaneous tissue, 300 ml of ascitic fluid, collateral blood vessels involving the omentum and rectus muscle. A part of the omentum was adherent to the fibroid masses. Large conglomerate fibroid masses measuring 24×32 cm with a broad stalk connecting it to the fundus of the uterus (Figure 2) was seen. It had an area of calcification and weighed 12.4 kg. The uterus had multiple intramural fibroid seedlings. The aggregate weight of all the fibroid extracted was 16.8 kg. Estimated blood loss was 1000 ml.

A size 16 urethral catheter was tied round the uterus at the isthmic region *i.e.* level of the internal Os to control bleeding at surgery. The pedunculated one was then excised at the base. Three subserous fibroids measuring 4.5×6.2 cm, 6.0×6.2 cm, 5.4×8.7 cm respectively were found and two intramural fibroid seedlings were enucleated. The uterus was repaired in layers and haemostasis was achieved. A peritoneal drain was inserted before closure of the anterior abdominal wall.

She had intravenous crystalloids and two units of fresh whole blood intra-operatively. Her post-operative recovery was uneventful. The packed cell volume on the 3rd post-operative day was 30%. Abdominal skin stitches were removed on

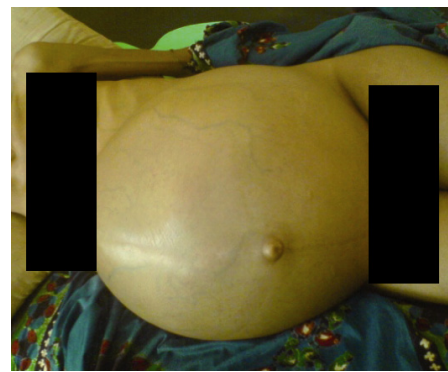

Figure 1. The patient's abdomen at presentation

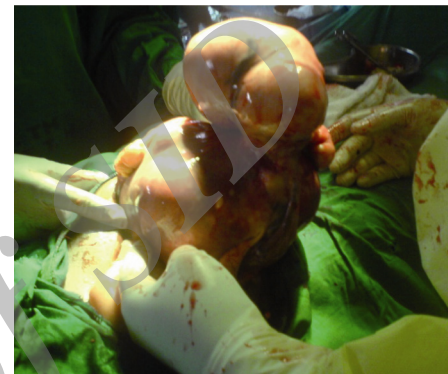


Figure 2. Intra-operative picture of the uterus delivered through the incision site before the removal of the fibroid masses

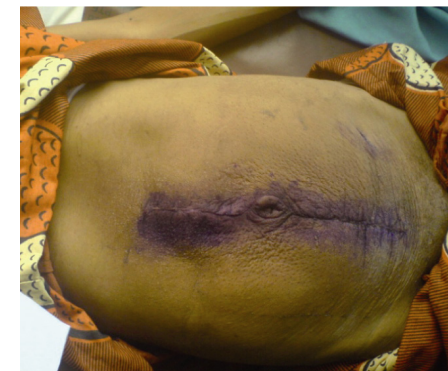


Figure 3. The abdominal wall after removal of skin stitches on the 7th post operative day

the 7th post-operative day (Figure 3). Histology confirmed multiple uterine fibroids.

She was followed up at the Gynaecology outpatient clinic. Seven months later, she presented to the clinic with history of nausea and amenorrhea. Urine pregnancy test was positive. Ultrasonography confirmed a viable intrauterine pregnancy. She registered for antenatal care and had an uneventful antenatal period. She had an elective caesarean section at 38 weeks of gestational age and delivered a live female baby that weighed 2.8 kg.

Discussion

Giant uterine fibroid has been reported to be exceedingly rare (2, 6). However, cases have been reported by different authors from different parts of the world (1, 7). Report shows that the largest uterine tumor ever removed from a patient that survived the procedure weighed 45.4 kg (8). Prior to this feat, a uterine fibroid mass that weighed 63.3 kg had earlier been removed in a women postmortem (8). The uterine fibroid extracted from our patient had an aggregate weight of 16.8 kg. The bulk of the fibroid was pedunculated making myomectomy an easy option.

Uterine fibroids are generally common among the black race. It is a common indication for hysterectomy in Nigeria (4, 5). About 36.8% of women who had symptomatic uterine fibroid had total abdominal hysterectomy with or without bilateral salpingo- oophorectomy in Enugu, Nigeria (5).

Due to the distensibility of the anterior abdominal wall and the large volume of the abdominal cavity, uterine fibroid can grow into extremely large sizes. The differential diagnosis of leiomyomas includes adenomyosis, haematometra and uterine cancer. Recently, cases of a giant leiomyoma mimicking an ovarian malignancy were reported (9, 10).

Imaging studies such as ultrasound, computer tomography, magnetic resonance imaging and tumor markers have been reported to be helpful in determining the extent of the mass and likelihood of malignancy (8). In Nigeria, like in many low income countries, except for ultrasound, these facilities are not readily available.

There is no single best approach to uterine fibroid treatment. However, giant uterine fibroids are best treated surgically and require adequate pre-operative preparations and an experienced and skillful surgeon. Many have reported total abdominal hysterectomy with or without salpingo-oophorectomy for giant uterine fibroids (1, 2, 6).

However, in Nigeria, like in many developing countries, there is a strong desire among women to have children. In most of these countries, reproductive failure is attributed to women who are childless (11), making hysterectomy a less desirable option for some patients. The surgical option for management of giant uterine fibroids should be individualized and where possible, conservation of the uterus for those women who earnestly desire future child bearing should be considered. Our patient had successful myomectomy and

achieved spontaneous conception about seven months after the surgery.

Post-operative complications are major challenges that could be prevented through adequate pre-operative preparation of the patient, especially through optimisation of haematological status, good surgical skills (with a careful attention to collateral vessel for proper ligation) and close post-operative management which would enable early detection and management of post-operative complications (12). Our patient had no complication and had good recovery post-operatively.

Conclusion

Although giant uterine fibroid is relatively rare, deciding on the best surgical option of management that considers the fertility wish and aspiration of couples in developing countries could be challenging. The surgical option for the management of giant uterine fibroid in developing countries should be individualized to the best interest of the patient.

Acknowledgement

We acknowledge the contribution of the matron in charge of labour ward, Mrs Agu and the Head, Department of Obstetrics & Gynecology to the writing of this case report.

Conflict of Interest

The authors declare no conflict of interest.

References

1. Steward RG, Denhartog HW, Katz AR. Giant uterine leiomyomata. *Fertil Steril.* 2011;95(3):1121-1127.
2. Nappi L, Matteo M, Giardina S, Rosenberg P, Indraccolo U, Greco P. Management of uterine giant myoma. *Arch Gynecol Obs.* 2008;278(1):61-3.
3. Speroff L, Fertz MA. *Clinical Gynaecologic endocrinology and infertility.* 7th ed. Philadelphia: Lippincott Williams & Wilkins; 2005. p. 463-9.
4. Okogbo FO, Ezechi OC, Loto OM, Ezeobi PM. Uterine Leiomyomata in South Western Nigeria: a clinical study of presentations and management outcome. *Afr Health Sci.* 2011;11(2):271-8.
5. Okezie O, Ezegwui HU. Management of uterine fibroids in Enugu, Nigeria. *J Obstet Gynaecol.* 2006;26(4):363-5.
6. Costa Benavente L, Silva Barroso F, Avila Flores E. [Giant uterine myoma]. *Ginecol Obstet Mex.* 2005;73(10):563-5. Spanish.

7. Savulescu F, Iordache I, Albita O, Hristea R, Dumitru C, Iordache A, et al. Giant uterine leiomyoma. *Chirurgia (Bucur)*. 2011;106(5):665-8.
8. Kjerulff KH, Langenberg P, Seidman JD, Stolley PD, Guzinski GM. Uterine leiomyomas. Racial differences in severity, symptoms and age at diagnosis. *J Reprod Med*. 1996;41(7):483-90.
9. Gajewska M, Kosinska-Kaczynska K, Marczevska J, Kaminski P. [Huge uterine leiomyoma with degenerative changes mimicking ovarian carcinoma--a case report]. *Ginekol Pol*. 2013;84(2):147-50. Polish.
10. Aydin C, Eris S, Yalcin Y, Sen Selim H. A giant cystic leiomyoma mimicking an ovarian malignancy. *Int J Surg Case Rep*. 2013;4(11):1010-2.
11. Van Balen F, Bos HMW. The social and cultural consequences of being childless in poor-resource. *Facts Views Vis Obgyn*. 2009;1(2):106-21.
12. Hackethal A, Bruggmann D, Leis A, Langde S, Stillger R, Munstedt K. Surgical management of uterine fibroids in Hesse, Germany, between 1998 and 2004. *Fertil Steril*. 2009;91(3):862-8.

Archive of SID