

Research Paper: Histomorphometrical and Histopathological Evaluation of Hedera Helix Alcoholic Extract on Dermal Collagen Bundles

Sahel Motaghi^{1*}, Mohammad Sadeghi¹, Sajad Seyyedini¹, Gholamreza Sepehri², Reza Kheirandish³

1. Department of Basic Sciences, Faculty of Veterinary Medicine, Shahid Bahonar University of Kerman, Kerman, Iran.

2. Neuroscience Research Center, Kerman University of Medical Sciences, Kerman, Iran.

3. Department of Pathobiology, Faculty of Veterinary Medicine, Shahid Bahonar University of Kerman, Kerman, Iran.

Citation Motaghi S, Sadeghi M, Seyyedini S, Sepehri Gh, Kheirandish R. Histomorphometrical and Histopathological Evaluation of Hedera Helix Alcoholic Extract on Dermal Collagen Bundles. Anatomical Sciences. 2017; 14(2):65-72.



Sahel Motaghi is assistant professor of Veterinary physiology. She was graduated from Shahid Bahonar University of Kerman (DVM) and Tehran University (PhD). She is working as an instructor in Department of Basic Sciences, Faculty of Veterinary Medicine, Shahid Bahonar University of Kerman, Kerman, Iran.

Funding: See Page 69

© Copyright: The Author(s)

Article info:

Received: 10 Nov 2016

Accepted: 20 Feb 2017

Keywords:

Hedera helix, Wound healing, Collagen

ABSTRACT

Introduction: Hedera helix is an evergreen plant used in treatment of wounds in the Iranian folk medicine. One of the main stages in wound healing process is, the proliferative phase in which fibroblasts proliferate within the wounds and produce extracellular matrix. Collagen is the main constituent of extracellular matrix. So the aim of this study was to evaluate the effect of Hedera helix alcoholic extract on dermal collagen bundles in wound healing process.

Methods: 7 adult *Oryctolagus Caniculus* rabbits were enrolled in this experiment. Four wounds were created on each rabbit. Alcoholic extract of hedera helix dried leaves were prepared. Wounds were treated with eucerin, phenytoin, hedera helix 10% and 20% eucerin-based creams for 20 days. On day 21 (after the completion of the experiment), skin samples were taken and the collagen bundles in reticular and papillary layers of the dermis were evaluated histologically.

Results: Histological assessment of dermal collagen bundles in the reticular layer showed that both 10% and 20% hedera helix creams, increased collagen bundle thickness significantly, compared to eucerin treated wounds ($P < 0.001$ and $P < 0.01$). In papillary layer there was no significant effect in both groups. Compared to eucerin treated wounds, collagen bundles were more organized in phenytoin and hedera helix 10% and 20% cream treated wounds, in a histomorphological point of view.

Conclusion: Our results showed that hedera helix contains phytochemicals which may act on the proliferative phase of wound healing process.

* Corresponding Author:

Sahel Motaghi, PhD

Address: Department of Basic Sciences, Faculty of Veterinary Medicine, Shahid Bahonar University of Kerman, Kerman, Iran.

Tel: +98 (912) 8191929

E-mail: sahelmotaghi@gmail.com; sahelmotaghi@uk.ac.ir

1. Introduction

Acute wounds are among the most common unpleasant incidents, with at least 11 million people affected [1]. The process of tissue repair, is called Wound healing. Platelets, keratinocytes, immune cells, microvascular cells, and fibroblasts play key roles in reconstruction of tissue integrity [2, 3]. The wound repair process includes 4 phases of coagulation, inflammation, genesis of granulation tissue (proliferative phase), and the phase of scar formation [4]. Effective medications in wound healing not only engage these phases to repair the skin, but also induce healing process via different mechanisms [5].

Some plants also, have the wound healing potential. Such phytochemicals are both safe and cost-effective. The literature review shows that a large number of plants are used in folk medicine for treatment of wounds and burns, worldwide [6]. A series of recent studies has indicated that the natural drugs have some bioactive constituents which induce healing and regeneration of lost tissues through multiple mechanisms such as antibacterial activity, anti-inflammatory effect, fibroblast proliferation, motility, etc. [5, 6]. One of the main stages in wound healing process, is the proliferative phase in which fibroblasts grow in wounds and produce extracellular matrix, which leads to forming granulation tissue. This matrix mainly consists of collagen III, fibrin, fibronectin, and hyaluronic acid which are progressively substituted with the matrix main containing collagen I [4].

Previous studies have emphasized that collagen provides the foundation of soft tissues and determines many biological and mechanical properties of the skin [3]. Some herbal extracts increase fibroblast cells and collagen fibers [7]. *Hedera helix* is an evergreen climbing plant native to Europe and Asia. This plant is used as an analgesic and anti-inflammatory agent, in the traditional medicine [8]. The leaves taken orally are also effective cough expectorant and may improve bronchitis. A number of existing studies in the broader literature have examined and proven the above-mentioned effects, scientifically [9, 10]. *Hedera helix* is one of the most well-known herbs for burns in Iranian traditional medicine. The objective of the current study was to evaluate the effect of *Hedera helix* on collagen formation or proliferative phase of wound healing.

2. Materials and Methods

Plant material

Fresh leaves of *hedera helix* were collected in April, from Shahid Bahonar University, Kerman, Iran. The

taxonomic identity of the plant was confirmed by Prof. M. Mirtadzadini, the Head of Herbarium Museum, in the Department of Biology, Faculty of Basic Sciences, Shahid Bahonar University of Kerman, Kerman, Iran. The voucher specimen number of the herb is 1942 in that herbarium.

Extract preparation

Fresh leaves were shade dried at room temperature (2 weeks). The maceration method was applied, to prepare the alcoholic extract. In short, 50-100 gr of plant was powdered and, methanol was gradually added until the powder was completely wet. Three minutes later, the same solvent was again added to wet the powder until completely covered and reached 8-10 cm above the powder level. The liquid was shaken for half an hour, eventually. Then, it was left in a dark place for 24 hours. Afterwards, the supernatant was filtered and some extract, collected. Consequently, some solvent was added to the remained material and the previous method proceeded. This process was repeated 2 to 3 times. In the end, filtered extracts of each stage were gathered and dried by a rotary evaporator.

Animals

Seven healthy adult *Oryctolagus cuniculus* rabbits of both genders (3 females and 4 males) weighting between 1.3-1.6 kg were enrolled to the experiment. Rabbits were quarantined individually in cages (48 cm×32 cm×31 cm) bedding with dried hay for a month to guarantee adaptation before initiation of the research. Rabbits belonging to the pre-test and post-test setting were kept individually in the same cages, with food and water ad libitum. Also, natural lighting was used during this period. The protocol of this study was on the basis of ethical principles of international committees that protect laboratory animals.

Experimental design of the study

Rabbits were anesthetized with ketamin (Trittauu, Germany; 90 mg/kg, i.m) and xylazin (Bayer, Leverkusen; 10 mg/kg, i.m). The rabbits dorsum hair was clipped and shaved. The region was surgically prepared with 7.5% povidone-iodine surgical scrub and alcohol 70% [11]. Four wounds were created on each animal as per described in the protocol by Cross et al. (1995) [12]. In brief, a template of 10 mm in diameter circular metal was placed on the disinfected region and its outline was traced on the skin, using a fine-tipped pen. In the following step, full thickness wounds were made at dorsum of rabbits with aid of a scalpel.

The wounds were parallel to sagittal axis and were 2.5 cm distant from spinal column. The wounds on each animal were washed with normal saline and treated topically, with 0.2 gr of the following drugs daily: 1. Eucerin (as negative control treatment); 2. Phenytoin 1% (Darupakhsh Co. Iran; as positive control treatment), 3 & 4. Eucerin-based creams of 10% and 20% heder helix alcoholic extract respectively. In order to eliminate the role of wound location on wound healing procedure, we considered different location for each treatment in rabbits. This procedure continued for 20 days.

Sampling and histological process

Following the completion of the experiment (on day 21), rabbits were euthanized. The wounded spots were shaved and the healed wound areas with 1 cm of normal skin around them were observed. Skin samples were taken from middle of the wounded area. Fixations were done using 10% buffered formalin solution. By absolute ethanol and xylol, they were dehydrated and then embedded in paraffin wax and serially sectioned at 5 μm (Slee® microtome; Germany and Tissue Processor Diban sabz DS2080/H; Iran).

Sections were then stained using Masson's trichrome method [in order to measure the thickness of collagen bundles in reticular and papillary layers of the dermis] and Hematoxylin-Eosin (H&E) (for standard histopathological evaluation). On the Masson's trichrome stained slides, the average diameter of 10 collagen bundles in every 10 fields were measured using a digital lens (Dino-eye, AM-7023, 5Mp, Taiwan) (Figure 1) [13, 14]. The H&E sections were used to assess the presence of inflammatory cells and angiogenesis in the dermis. Results were expressed as Means \pm SEM. Data were analyzed by One-Way ANOVA as well as the LSD test, using the SPSS software (version 17) (Statistical Package for the Social Sciences, version 17, SPSS; Chicago, USA). P-values less than 0.05 were considered as significant.

3. Results

Histomorphometrical findings

Histological assessment of dermal collagen bundles in the reticular layer showed that both 10% and 20% Hedera helix creams, increased collagen bundle thickness significantly, compared to eucerin treated wounds ($P < 0.001$ and $P < 0.01$). Expectedly, collagen bundles

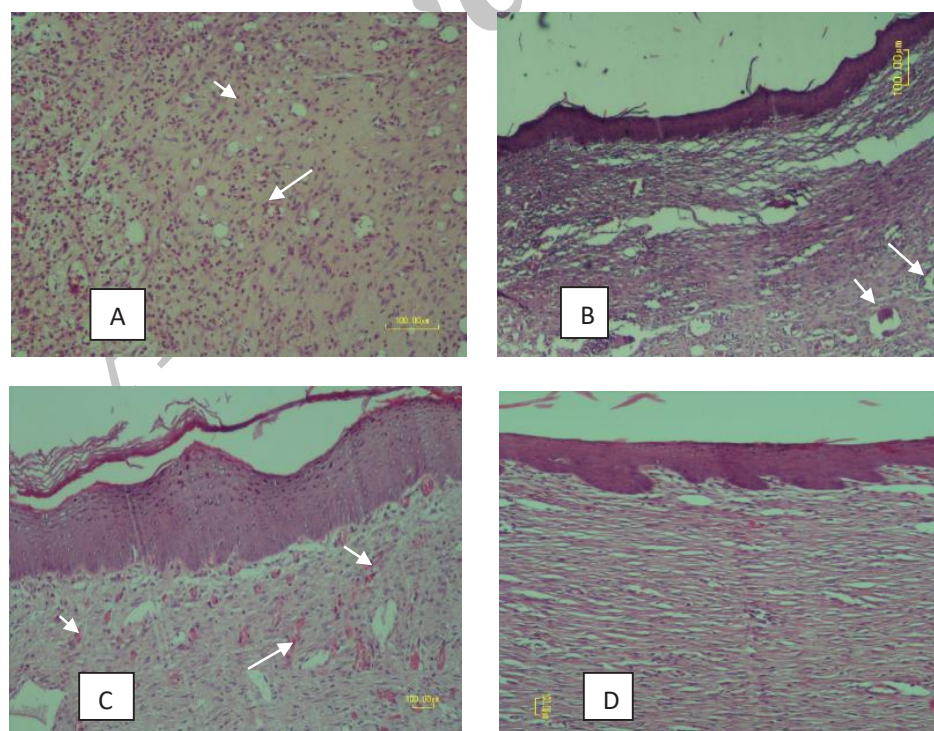
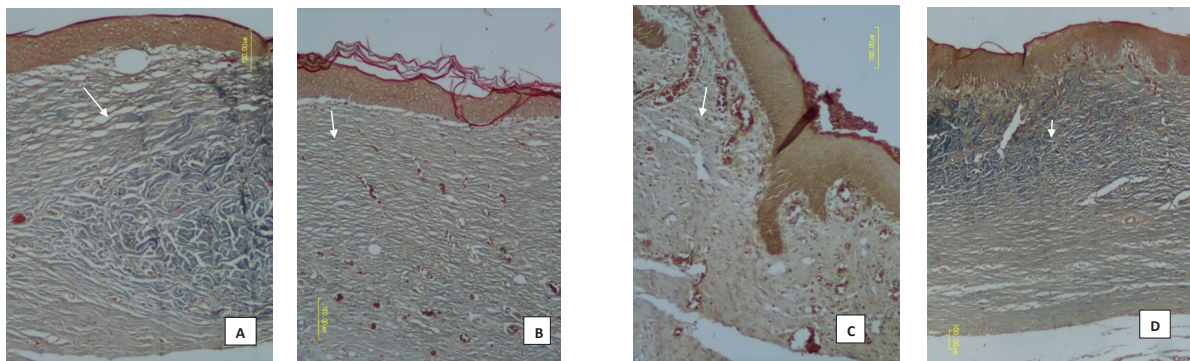


Figure 2. Histomorphology and histopathology evaluation of dermis. A, B, C and D show eucerin, phenytoin, hedera helix 10% and 20% treatments, respectively. In picture (A) arrows show the presence of inflammatory cells. Angiogenesis can be seen in pictures (B) and (C) by markers. H&E ($\times 100$)



ANATOMICAL SCIENCES

Figure 1. Histomorphometrical evaluation of collagen bundles. Picture (A) is a sample of Hedera helix 10% and (B) is a phenytoin treated wound. Pictures (C) and (D) show ucerin and Hedera helix 20% wounds respectively. Arrows show collagen bundles. The bundles are less organized in ucerin treated wounds. Masson's trichrome (×100)

thickness was significantly greater in phenytoin treated wounds compared to the eucerin treated ones ($P < 0.01$) (Table 1). No statistically significant effect was seen on both groups, with respect to the papillary layer. Collagen bundles increased in phenytoin treatment, compared to the eucerin one, although it did not reach the significance level (Table 1). Our results demonstrated that, compared to eucerin treated wounds, collagen bundles were more organized in phenytoin and Hedera helix 10% and 20% cream treated wounds, in a histomorphological point of view (Figures 1 and 2).

Histopathological findings

BY the use of H&E staining method, our results showed that the inflammatory cells including neutrophil and macrophages were more abundant in eucerin treated wounds, whereas they were scarce in phenytoin and extract treated wounds (Figure 2). Angiogenesis was observed to be more prominent in phenytoin and Hedera helix 10% treated wounds (Figures 1C and 2B).

4. Discussion

The present histomorphometrical study proved an increase in collagen bundle thickness of reticular layer,

which implies the positive effect of this plant on collagen bundles. In addition, better organization of collagen bundles was observed. In other words, this study represented the effectiveness of Hedera helix phytochemicals on wound healing process. Several studies suggest that such effect has been reached by other plants as well [15-17]. A major incident in dermal wound repairing process is the growing increment in mechanical strength of the tissue; the biomechanical properties of the skin are mostly formed as a result of the dermis function, in relation to the structure of collagen and elastic fiber networks.

In addition, it is also well acknowledged that tensile strength is also associated with the organization, content, and physical properties of the collagen fibril network [18]. The main constituents of this plant, effective in wound healing process include alkaloids, flavonoids, tannins, terpenoids, saponins, and phenolic compounds [5, 19]. During wound healing process, fibroblasts, change their position from the wound edges, to the wound site; increase, and subsequently produce the main component of the extracellular matrix, collagen.

One of the mechanisms by which herbal extracts may enhance the wound healing process, is the incitement of fibroblasts. In other words, some of the phytochemicals

Table 1. Histometric measurements of collagen bundles

Treatments	Reticular Bundles Thickness (µm)	Papillary Bundles Thickness (µm)
Eucerin	2.47±0.56	1.82±0.33
Phenytoin	3.07±0.60*	2.04±0.11
Hedera helix 10%	3.13±0.55**	1.88±0.32
Hedera helix 20%	2.78±0.70*	1.89±0.42

Data presented as Means±SE; * $P < 0.01$; ** $P < 0.001$ compared to eucerin treatments.

ANATOMICAL SCIENCES

cause proliferation, migration and functioning of fibroblasts [20, 21]. These effects on fibroblasts, probably, are the result of phytoconstituents of herbal extract that may have a growth factor-like activity or have the ability to stimulate the early expression of growth factors [22]. Many herbal studies have shown the presence of mitogenic components in medicinal plants [23-25] but the specific compounds responsible for the mitogenic activities have not yet been identified [26].

Some phytochemicals increase the viability of collagen fibers by either preventing cell damage or increasing the circulation [5, 27]. At the wound site, increased amounts of superoxide anion radicals were produced by activated platelets, neutrophils and fibroblasts, and stimulated by the pro-inflammatory cytokines during the inflammation phase [26]. Hence, any drug that inhibits these actions will increase the viability of collagen fibrils. Therefore, some herbal extracts cause better collagenation due to upgrading the antioxidant status [28].

A number of authors have recognized that antioxidants can affect the oxidation process by reacting with free radicals, chelating catalytic metals and by acting as oxygen scavengers. Free radicals and other Reactive Oxygen Species [ROs] are considered to be important causative factors in delaying the healing process [29]. It has been shown that saponins [30], tannins [31, 32], terpenoids [33] and flavonoids [34] perform antioxidant activities. In this regard it has been shown that saponins like α -hederin, hederasaponin-c, hederacolchisides E and F isolated from *hedera helix* have antioxidant features [35].

In conclusion, the effect seen in the current study may be either due to synergism of different classes of phytoconstituents or an individual one. Further specific studies for elucidating the main components involved in wound healing process is required. Overall, this study confirmed the effectiveness of traditional use of this plant, scientifically.

Ethical Considerations

Compliance with ethical guidelines

The protocol of this study was on the basis of ethical principles of international committees that protect laboratory animals.

Funding

This research was financially supported by a grant (No: 1393/12/1) provided by the Technology and Research Council of Shahid Bahonar University of Kerman, Iran.

Conflict of interest

The authors declared no conflict of interest.

Acknowledgements

The authors would like to thank Dr. M. Mirtadzadini for the valuable botanical information about this plant and Dr. MN Nazem for providing scientific comments on this research.

References

- [1] Singer AJ, Dagum AB. Current management of acute cutaneous wounds. *New England Journal of Medicine*. 2008; 359(10):1037-46. [DOI:10.1056/NEJMra0707253] [PMID]
- [2] Canty EG, Kadler KE. Procollagen trafficking, processing and fibrillogenesis. *Journal of Cell Science*. 2005; 118(7):1341-53. [DOI:10.1242/jcs.01731] [PMID]
- [3] Caves JM, Kumar VA, Wen J, Cui W, Martinez A, Apkarian R, et al. Fibrillogenesis in continuously spun synthetic collagen fiber. *Journal of Biomedical Materials Research Part B: Applied Biomaterials*. 2010; 93(1):24-38. [PMID]
- [4] Demidova-Rice TN, Hamblin MR, Herman IM. Acute and impaired wound healing: Pathophysiology and current methods for drug delivery, part 1: Normal and chronic wounds: Biology, causes, and approaches to care. *Advances in Skin & Wound Care*. 2012; 25(7):349. [DOI:10.1097/01.ASW.0000416006.55218.d0] [PMID] [PMCID]
- [5] Thakur R, Jain N, Pathak R, Sandhu SS. Practices in wound healing studies of plants. *Evidence-Based Complementary and Alternative Medicine*. 2011; 2011. [DOI:10.1093/ecam/neaq012] [PMID] [PMCID]
- [6] Hamed A, Zarshenas MM, Sohrabpour M, Zargaran A. Herbal medicinal oils in traditional Persian medicine. *Pharmaceutical Biology*. 2013; 51(9):1208-18. [DOI:10.3109/13880209.2013.777462] [PMID]
- [7] Lodhi S, Pawar RS, Jain AP, Singhai A. Wound healing potential of *Tephrosia purpurea* (Linn.) Pers. in rats. *Journal of Ethnopharmacology*. 2006; 108(2):204-10. [DOI:10.1016/j.jep.2006.05.011] [PMID]
- [8] Mandade RJ, Choudhuri A, Mashirkar V, Sakarkar D. Analgesic and antiinflammatory activities of *hedera helix* leaf extract. *International Journal of Comprehensive Pharmacy*. 2010; 1(4):1-3.

- [9] Holzinger F, Chenot JF. Systematic review of clinical trials assessing the effectiveness of ivy leaf (*Hedera helix*) for acute upper respiratory tract infections. *Evidence-Based Complementary and Alternative Medicine*. 2011; 8(1):1-9. [DOI:10.1155/2011/382789] [PMID] [PMCID]
- [10] Lutsenko YU, Bylka WI, Matlawska I, Darmohray RO. *Hedera helix* as a medicinal plant. *Herba Polonica*. 2010; 56(1):83-96.
- [11] Sohrabi-Haghdost RV, Safarmashaei S. Comparison of in-vivo wound healing activity of *Verbascum thapsus* flower extract with zinc oxide on experimental wound model in rabbits. *Advances in Environmental Biology*. 2011; 5(7):1501-9.
- [12] Cross S, Naylor L, Coleman R, Teo T. An experimental model to investigate the dynamics of wound contraction. *British Journal of Plastic Surgery*. 1995; 48(4):189-97. [DOI:10.1016/0007-1226(95)90001-2]
- [13] Nazem MN, Teymouri M, Jahantigh M. The histomorphometric and histopathologic effect of methionine on the epidermis and dermis layers of skin in rat. *Comparative Clinical Pathology*. 2016; 25(4):699-704. [DOI:10.1007/s00580-016-2250-0]
- [14] Nazem MN, Tavakoli H, Sajjadian SM. Histomorphometrical and histopathological assessment of in ovo methionine injection on the skin layers and its collagen bundles of chicken embryo. *Anatomical Sciences Journal*. 2015; 12(3):115-20.
- [15] Tsala DE, Joseph MN, Heroyine LT, Solomon H. In vivo wound healing effect of water extract of *Stereospermum kunthianum* stem-bark. *Journal of Medicinal Herbs and Ethnomedicine*. 2016; 2(1):1-6.
- [16] Samanta R, Pattnaik A, Pradhan K, Mehta B, Pattanayak S, Banerjee S. Wound healing activity of silibinin in mice. *Pharmacognosy Research*. 2016; 8(4):298-302. [DOI:10.4103/0974-8490.188880] [PMID] [PMCID]
- [17] Nabuni M, Oryan S, Ayyobipor M, Bagheri M. [Histochemical study of *Verbascum speciosum* extract's effects on the wound healing in rats (Persian)]. *Journal of Cell & Tissue*. 2011; 2(1):67-75.
- [18] Shetty S, Udupa S, Udupa L. Evaluation of antioxidant and wound healing effects of alcoholic and aqueous extract of *Ocimum sanctum* Linn in rats. *Evidence-Based Complementary and Alternative Medicine*. 2008; 5(1):95-101. [DOI:10.1093/ecam/nem004] [PMID] [PMCID]
- [19] Uddin G, Rauf A, Qaisar M, Latif A, Ali M. Preliminary phytochemical screening and antimicrobial activity of *Hedera helix* L. *Middle-East Journal of Science Research*. 2011; 8(1):198-202.
- [20] Amin ZA, Ali HM, Alshawsh MA, Darvish PH, Abdulla MA. Application of *Andropogon camphorata* promotes rat's wound healing in vivo and facilitates fibroblast cell proliferation in-vitro. *Evidence-Based Complementary and Alternative Medicine*. 2015; 2015:1-14. [DOI:10.1155/2015/317693] [PMID] [PMCID]
- [21] Bueno FG, Panizzon GP, Mello EVSdL, Lechtenberg M, Petereit F, Mello JCPd, et al. Hydrolyzable tannins from hydroalcoholic extract from *Poincianella pluviosa* stem bark and its wound-healing properties: Phytochemical investigations and influence on in vitro cell physiology of human keratinocytes and dermal fibroblasts. *Fitoterapia*. 2014; 99(8):252-60. [DOI:10.1016/j.fitote.2014.10.007] [PMID]
- [22] Priya KS, Arumugam G, Rathinam B, Wells A, Babu M. *Celosia argentea* Linn. leaf extract improves wound healing in a rat burn wound model. *Wound Repair and Regeneration*. 2004; 12(6):618-25. [DOI:10.1111/j.1067-1927.2004.12603.x] [PMID]
- [23] James O, Friday ET. Phytochemical composition, bioactivity and wound healing potential of *Euphorbia heterophylla* (Euphorbiaceae) leaf extract. *International Journal on Pharmaceutical and Biomedical Research*. 2010; 1(1):54-63.
- [24] Fikru A, Makonnen E, Eguale T, Debella A, Mekonnen GA. Evaluation of in vivo wound healing activity of methanol extract of *Achyranthes aspera* L. *Journal of Ethnopharmacology*. 2012; 143(2):469-74. [DOI:10.1016/j.jep.2012.06.049] [PMID]
- [25] Perumal Samy R, Chow VT. Pilot study with regard to the wound healing activity of protein from *Calotropis procera* (Ait.) R. Br. *Evidence-Based Complementary and Alternative Medicine*. 2012; 2012:1-14. [DOI:10.1155/2012/294528] [PMID] [PMCID]
- [26] Ghosh PK, Gaba A. Phyto-extracts in wound healing. *Journal of Pharmacy and Pharmaceutical Science*. 2013; 16(5):760-820. [DOI:10.18433/J3831V]
- [27] Majumdar M, Nayeem N, Kamath JV, Asad M. Evaluation of *Tectona grandis* leaves for wound healing activity. *Pakistan Journal of Pharmaceutical Sciences*. 2007; 20(2):120-4. [PMID]
- [28] Umadevi S, Mohanta G, Kalaichelvan V, Manavalan R. Studies on wound healing effect of *Flaveria trinervia* leaf in mice. *Indian Journal of Pharmaceutical Sciences*. 2006; 68(1):106-8. [DOI:10.4103/0250-474X.22979]
- [29] Datta HS, Mitra SK, Patwardhan B. Wound healing activity of topical application forms based on ayurveda. *Evidence-Based Complementary and Alternative Medicine*. 2011; 8(1):1-10. [DOI:10.1093/ecam/nep015] [PMID] [PMCID]
- [30] Wojdyło A, Oszmiański J, Czemerys R. Antioxidant activity and phenolic compounds in 32 selected herbs. *Food Chemistry*. 2007; 105(3):940-9. [DOI:10.1016/j.foodchem.2007.04.038]
- [31] Jain S, Jain A, Jain S, Malviya N, Jain V, Kumar D. Estimation of total phenolic, tannins, and flavonoid contents and antioxidant activity of *Cedrus deodara* heart wood extracts. *Egyptian Pharmaceutical Journal*. 2015; 14(1):10-4. [DOI:10.4103/1687-4315.154690]
- [32] Costa G, González-Manzano S, González-Paramás A, Figueiredo IV, Santos-Buelga C, Batista MT. Flavan hetero-dimers in the *Cymbopogon citratus* infusion tannin fraction and their contribution to the antioxidant activity. *Food & Function*. 2015; 6(3):932-7. [DOI:10.1039/C5FO00042D] [PMID]
- [33] Dudonné S, Vitrac X, Coutiere P, Woillez M, Mérillon JM. Comparative study of antioxidant properties and total phenolic content of 30 plant extracts of industrial interest using DPPH, ABTS, FRAP, SOD, and ORAC assays. *Journal of Agricultural and Food Chemistry*. 2009; 57(5):1768-74. [DOI:10.1021/jf803011r] [PMID]

- [34] Ghasemzadeh A, Jaafar HZE, Rahmat A, Ashkani S. Secondary metabolites constituents and antioxidant, anticancer and antibacterial activities of *Etlingera elatior* (Jack) R.M.Sm grown in different locations of Malaysia. *BMC Complementary and Alternative Medicine*. 2015; 15(1):1-10. [DOI:10.1186/s12906-015-0838-6] [PMID] [PMCID]
- [35] Gülçin İ, Mshvildadze V, Gepdiremen A, Elias R. Antioxidant activity of saponins isolated from ivy: α -hederin, hederasaponin-C, hederacolchiside-E and hederacolchiside-F. *Planta Medica*. 2004; 70(6):561-3. [DOI:10.1055/s-2004-827158] [PMID]

Archive of SID

Archive of SID