



Case Report

Journal Homepage: <http://crp.tums.ac.ir>

Fractures in Corticosteroid- and Bisphosphonate-Treated Subjects With Longstanding Rheumatoid Arthritis and Systemic Lupus Erythematosus

Atie Moghtadaie¹, Seyed Amir Miratashi Yazdi², Ahmad Salimzadeh^{3*}

1. Department of Internal Medicine, Sina Hospital, Tehran University of Medical Sciences, Tehran, Iran.

2. Department of General Surgery, Sina Hospital, Tehran University of Medical Sciences, Tehran, Iran.

3. Rheumatology Research Center, Sina Hospital, Tehran University of Medical Sciences, Tehran, Iran.

Use your device to scan and read the article online



Citation: Moghtadaie A, Miratashi Yazdi SA, Salimzadeh A. Fractures in Corticosteroid- and Bisphosphonate-Treated Subjects With Longstanding Rheumatoid Arthritis and Systemic Lupus Erythematosus. *Case Reports in Clinical Practice*. 2021; 6(2):59-65.

Running Title: Fractures in Corticosteroid- and Bisphosphonate-Treated with Rheumatoid Arthritis

Article info:**Received:** 03 Mar 2021**Revised:** 20 Mar 2021**Accepted:** 08 Apr 2021**Keywords:**

Fracture; Rheumatoid arthritis; Bisphosphonates

ABSTRACT

Background: Bisphosphonates are the most widely prescribed agents for the treatment of postmenopausal osteoporosis and other metabolic bone diseases. Atypical femoral fractures in bisphosphonate-treated patients have raised concerns regarding the long-term safety of this class of medications.

Case Presentation: In this study, we report two patients suffering from fractures while receiving bisphosphonates; a postmenopausal patient with rheumatoid arthritis and a history of long-term use of bisphosphonates and glucocorticoids presenting with multiple fractures as case one and another 52-year-old female patient diagnosed with Systemic Lupus Erythematosus (SLE) who suffered from a femoral shaft fracture without any history of prior traumatic incidents as case two.

Conclusions: Considering the low risk for atypical femoral fractures, further careful screening for these types of fractures should be undertaken. In addition, in order to lower the rate of fractures in patients on long-term bisphosphonate therapy, assessment of patients' contralateral side should be considered to prevent further fractures, especially in patients with prodromal pain

Corresponding Author:*Ahmad Salimzadeh, MD.****Address:** Rheumatology Research Center, Sina Hospital, Tehran University of Medical Sciences, Tehran, Iran.**E-mail:** salimzad@tums.ac.ir

Introduction

Bisphosphonates are the most commonly prescribed agents for the treatment of postmenopausal osteoporosis and other metabolic bone diseases [1]. However, the long-term use of these medications may result in some stress-type atraumatic fractures [1, 2].

The long-term use of bisphosphonates is associated with more cases of delayed union and more frequent bilateral fractures subsequent to unilateral fractures [2, 3]. Atypical femoral fractures in bisphosphonate-treated patients have raised concerns about the long-term safety of these types of medications. These fractures have a characteristic radiographic presentation and occur with or without the initial alarming pain [4]. The therapeutic approach for patients with a history of prolonged use of bisphosphonates is a matter of debate. Controlled use of bisphosphonates pertaining to the associated complications may help decrease the rate of bisphosphonate-related atypical femoral fractures [3, 4]. In this study, we report a postmenopausal patient (case one) with Rheumatoid Arthritis (RA) and a history of long-term use of bisphosphonates and glucocorticoids presenting with multiple fractures. The second case was a 52 years old female patient diagnosed with Systemic Lupus Erythematosus (SLE) who suffered from a femoral shaft fracture without any history of a prior traumatic incident. Bone mineral densitometry in both cases was conducted with Hologic® bone densitometry instruments.

Case Presentation

Case 1

A 47-year-old female patient with RA lasted for eleven years ago and early menopause one year before the diagnosis of RA, who was taking Methotrexate (MTX), prednisolone, sulfasalazine, and leflunomide attended the clinic. She had experienced multiple events of remissions and exacerbations, which the last episode of exacerbation was three years ago and the disease has been controlled since then. She was subjected to a bone mineral densitometry nine years ago that showed femoral head osteoporosis and lumbar spine osteopenia (Table 1). Afterwards, secondary causes of osteoporosis were investigated by the evaluation of serum calcium, phosphorus, alkaline phosphatase, 25(OH)-Vit-D3, Parathyroid Hormone (PTH), 24-hour urine calcium, serum and urine protein electrophoresis, and thyroid function tests, which were totally normal. For osteoporosis

treatment, alendronate, calcium, and vitamin D3 were administered.

In 2013, she was presented to the hospital with a femoral fracture due to minor trauma (Figure 1). She underwent surgery and nailing without further assessments. One year later, she was presented with multiple rib fractures and a contralateral femoral shaft fracture (Figure 2). In order to further workup for recurrent fracture, she was repeatedly admitted to the hospital after undergoing surgery. The laboratory results are shown in Table 2.

Abdominal ultrasonography and pap smears were normal. Upper and lower endoscopy assessments also showed no significant abnormal finding. There were no remarkable findings in spiral thoracic-abdominopelvic CT scan, spinal Magnetic Resonance Imaging (MRI), mammography, serum and urine protein electrophoresis, and immunofixation. On the other hand, a whole-body bone scan showed multiple fractures possibly due to metastasis. Upper and lower endoscopy assessments also showed no significant abnormal findings. Cancer Antigen 125 (CA125), Alpha-Fetoprotein (AFP), Lactate Dehydrogenase (LDH), CA19-9, and Carcinoembryonic Antigen (CEA) levels were 11.8, 1.9, 292, 1.3, and 1.3, respectively.

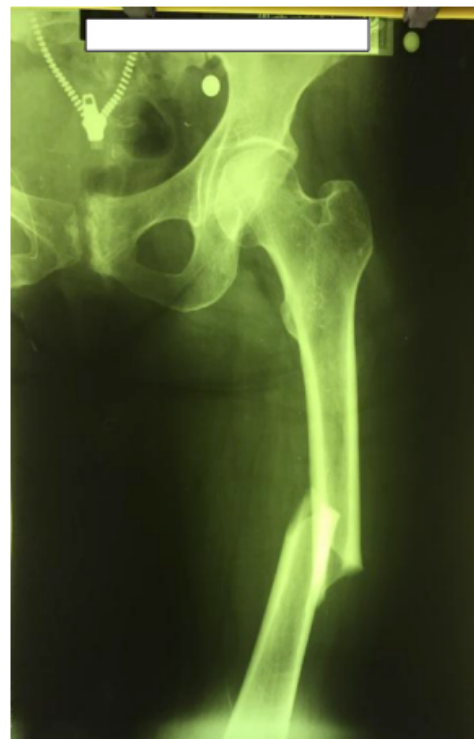

Figure 1. First femoral fracture four years ago

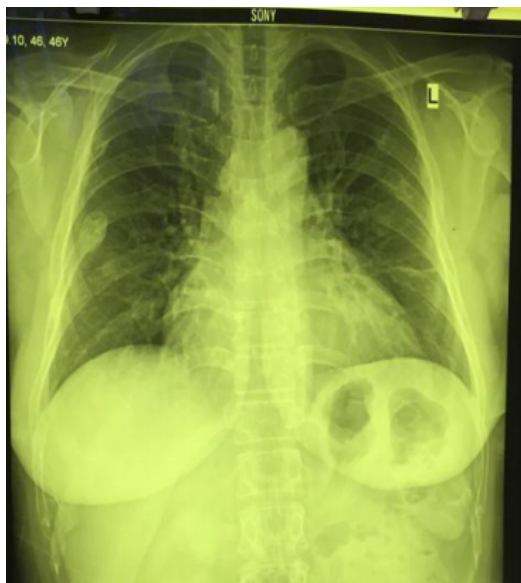

Figure 2. Multiple rib fractures



After ruling out five main differential diagnoses, namely malignancy, multiple myeloma, leukemia, hyperthyroidism, and hyperparathyroidism, the diagnosis of Atypical Femoral Fracture (AFF) due to prolonged bisphosphonate therapy was made. At the time of the diagnosis, bisphosphonate was discontinued and teriparatide therapy was started for up to 18 months. She had no new fractures since the start of the new drug and previous fractures were healed.

Case 2

Another notable case of AFF is a 52 years old female with a history of SLE that lasted for 15 years ago with diagnostic criteria as follows: seizures, positive serology,

leukopenia, Raynaud phenomenon, and polyarthritis. She was under treatment with CellCept® (Mycophenolic acid), hydroxychloroquine, and prednisolone for 6 years after the initial diagnosis until oral alendronate was added to her treatment after bone densitometry that revealed osteoporosis in the patient.

To rule out the secondary causes of osteoporosis, serum 25OHD, calcium, phosphorus, and PTH were checked and were found to lie within the normal range. Her bone densitometries had been tracked for 8 years (Table 3 and Figure 3). Although there was no history of a prior traumatic accident, due to a femoral shaft fracture, the patient underwent a fixation surgery 5 years after the initiation of alendronate (Figures 4 and 5). Despite the inefficacy of the drug, due to costly alternatives and undiagnosed AFF, oral alendronate was continued for another year. Ultimately, after the diagnosis of AFF, alendronate was discontinued and CinnoPar® (teriparatide 750 µg) was started.

Discussion

Bisphosphonates reduce the incidence rate of vertebral and non-vertebral fractures and suppress bone volume loss in patients with osteoporosis [5]. However, treatment with bisphosphonates is associated with some adverse effects. Bisphosphonates inhibit the osteoclastic function and induce apoptosis, leading to suppression of the bone turnover and subsequent AFF [6, 7]. AFF is a rare type of femoral stress fracture potentially associated with prolonged use of bisphosphonates [8]. The risk factors for AFF include long-term bisphosphonate use, high body mass index, proton pump inhibitor or glucocorticoid use, genu-varum, bowed femur,

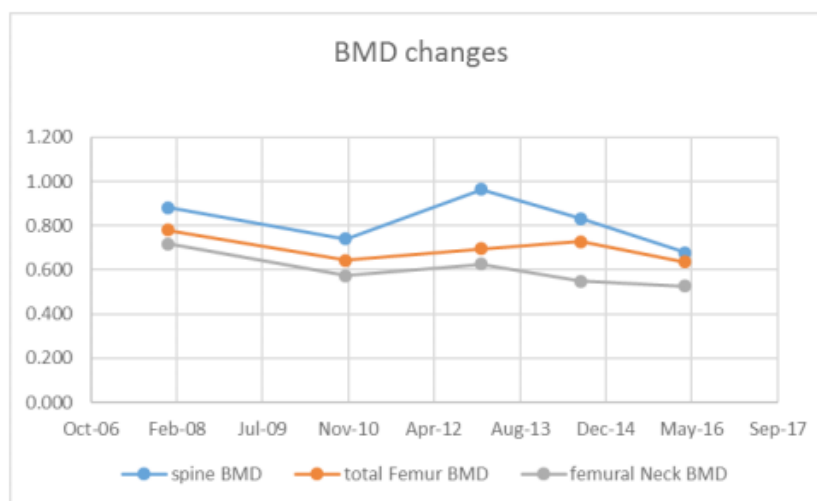


Figure 3. Spine, total femur, and femoral neck Bone Mineral Density (BMD) changes during 8 years.



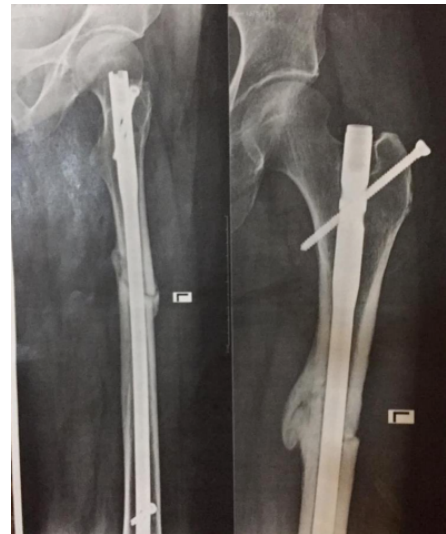
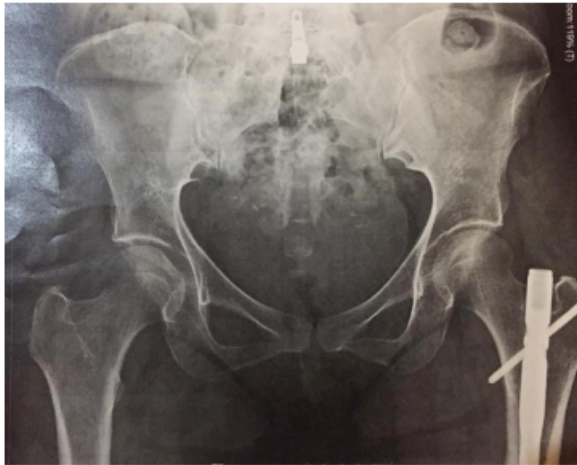
Figure 4. A and B: Femoral shaft Fracture and internal fixation



recent contralateral AFF, and collagen-vascular diseases [9-11]. The incidence rate of AFF is reported from 86 to 146 per 100,000 person-years [10, 12].

Lovy et al. reported an atypical femur fracture treated by cephalomedullary nailing with segmental fracture pattern [13]. They reported that the patient had over one year of use of bisphosphonates without any other atypical femur fracture risk factors. However, our reported patient had three risk factors, including collagen-vascular disease, long-term treatment with glucocorticoids, and long-term use of bisphosphonates. If an atypical fracture is diagnosed for a patient, then the

bisphosphonate therapy should be discontinued and the possible prophylactic surgery should be done [14]. Patients under bisphosphonate therapy would require routine screening for occasional fractures, especially in cases with prodromal pain. This screening is also advised after five years of oral or three years of intravenous therapy [14].

On the other hand, the contralateral side should be assessed with imaging modalities for possible fractures [15]. However, Maheshwari et al. [16] reported a case of a bisphosphonate-related atypical femoral fracture that was progressed despite the prophylactic cephalo-

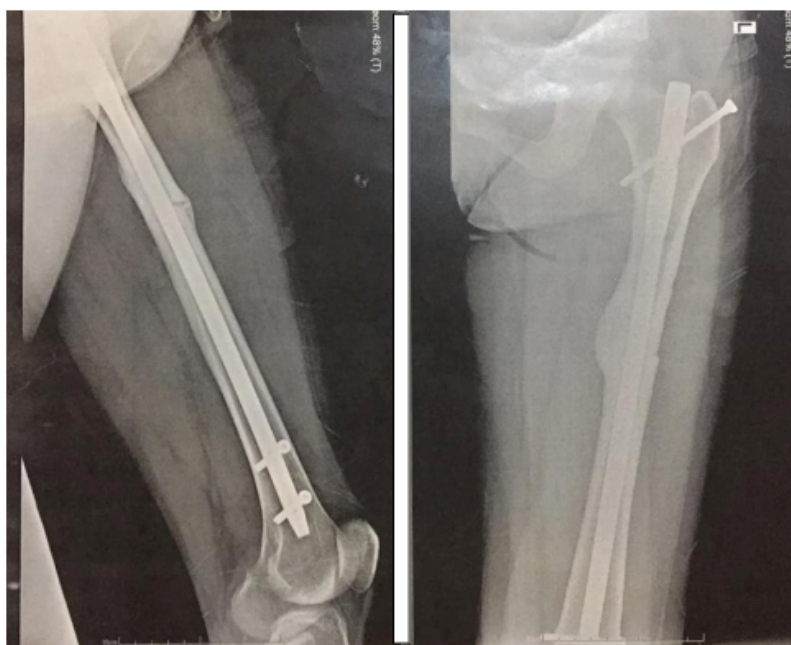


Figure 5. The 10-month post-operative radiograph



Table 1. Results of bone mineral densitometry

Variables	Spine (L2-L4)	Total Femur	Femoral Neck
Bone Mineral Density (BMD) g/cm ²	0.790	0.731	0.668
T-score	-2.3	-1.7	-1.6
Z-score	-2.1	-1.5	-1.3



Table 2. Laboratory results after second fracture

Hemoglobin	MCV	MCH	Platelets	Leukocytes	Ferritin	ESR	CRP	Calcium	Phosphorus	PTH	ALKP	Creatinine	25(OH)-VitD	Urine Volume (24 hr)	Urine Creatinine (24 hr)	Urine Calcium (24 hr)	T3	T4	TSH
7.8	67	19.6	575000	82000	7	40	2+	9.4	4.8	37.6	212	0.6	38	1440	868	154	95	5	3.2

ESR: erythrocyte sedimentation rate

CRP: c- reactive protein

PTH: parathyroid hormone

ALKP: alkaline phosphatase



Table 3. Spine, total femur, and femoral neck Bone Mineral Density (BMD) changes during 8 years

Variables		- *	+Alendronate*		+Cinnopar*	
		Jan 2008	Nov 2010	Jan 2013	Aug 2014	Apr 2016
Spine (L2-L4)	BMD g/cm ²	0.882	0.741	0.963	0.832	0.677
	T-score	-1.6	-2.8	-1.3	-1.1	-2.7
	Z-score	-1.0	-2.4	-0.8	-1.4	-2.7
Total femur	BMD g/cm ²	0.780	0.644	0.696	0.727	0.635
	T-score	-1.3	-2.4	-2.0	-1.8	-2.0
	Z-score	-0.8	-2.2	-1.5	-1.4	-2.1
Femoral neck	BMD g/cm ²	0.718	0.574	0.626	0.549	0.527
	T-score	-1.8	-2.5	-2.5	-2.7	-2.6
	Z-score	-1.2	-2.1	-1.9	-2.1	-2.2

* The first bone densitometry was done about 3 years after the initiation of SLE treatment. The patient was under treatment with alendronate due to her osteoporosis from 2010 to 2016. Alendronate was discontinued and cinnopar initiated in 2016. She was not under any osteoporosis treatment before 2010.



medullary nailing. They reported that the fracture was healed without further surgical procedures after correction in the patient's bone metabolic profile as well as improvements in some risk factors. Alwahhabi et al. reported that among 23 patients with AFF, teriparatide at a daily dose of 20 mcg, may facilitate the fracture healing process and improve the thigh pain [17]. Găleşanu et al. reported a 77-year-old female patient without a history of prior trauma who was under bisphosphonate therapy for osteoporosis over a period of ten years [18]. Interestingly, they denied that the benefits of bisphosphonate therapy outweigh the risks of AFF. This controversial result demonstrates the worldwide challenges in this field and the need for further studies to conclude more definite results. The importance of our findings is that although bone mineral densitometry showed no improvement no new fractures occurred and the healing process of prior fractures was accelerated.

In conclusion, considering the basic risk for AFFs, further careful screening for these types of fractures should be undertaken. In addition, to reduce the incidence rate of this phenomenon among patients receiving long-term bisphosphonate drugs, especially in patients with prodromal pain, assessment of the contralateral side could be beneficial for the prevention of further fractures.

Ethical Considerations

Compliance with ethical guidelines

There were no ethical considerations to be considered in this research.

Funding

This research did not receive any grant from funding agencies in the public, commercial, or non-profit sectors.

Conflict of interest

The authors declared no conflict of interest.

References

- [1] Kayali C, Altay T, Ozan F, Sozkesen S, Yamak K. Atypical femoral shaft fractures secondary to long-term bisphosphonate therapy. *Journal of Orthopaedics*. 2017; 14(2):226-30. [DOI:10.1016/j.jor.2017.01.002] [PMID] [PMCID]
- [2] Kang JS, Won YY, Kim JO, Min BW, Lee KH, Park KK, et al. Atypical femoral fractures after anti-osteoporotic medication: A Korean multicenter study. *International Orthopaedics*. 2014; 38(6):1247-53. [DOI:10.1007/s00264-013-2259-9] [PMID] [PMCID]
- [3] Khan AA, Kaiser S. Atypical femoral fracture. *Canadian Medical Association Journal*. 2017; 189(14):E542. [DOI:10.1503/cmaj.160450] [PMID] [PMCID]
- [4] Donnelly E, Saleh A, Unnanuntana A, Lane JM. Atypical femoral fractures: epidemiology, etiology, and patient management. *Current Opinion in Supportive and Palliative Care*. 2012; 6(3):348-54. [DOI:10.1097/SPC.0b013e3283552d7d] [PMID] [PMCID]
- [5] Hong CH, Quach A, Lin L, Olson J, Kwon T, Bezouglaia O, et al. Local vs. Systemic administration of bisphosphonates in rat cleft bone graft: A comparative study. *PLoS One*. 2018; 13(1):e0190901. [DOI:10.1371/journal.pone.0190901] [PMID] [PMCID]
- [6] Saita Y, Ishijima M, Kaneko K. Atypical femoral fractures and bisphosphonate use: Current evidence and clinical implications. *Therapeutic Advances in Chronic Disease*. 2015; 6(4):185-93. [DOI:10.1177/2040622315584114] [PMID] [PMCID]
- [7] Koehne T, Kahl-Nieke B, Amling M, Korbmacher-Steiner H. Inhibition of bone resorption by bisphosphonates interferes with orthodontically induced midpalatal suture expansion in mice. *Clinical Oral Investigations*. 2018; 22(6):2345-51. [DOI:10.1007/s00784-018-2335-z] [PMID]
- [8] Yamamoto N. Atypical femoral fracture and Bisphosphonate. *Clinical Calcium*. 2017; 27(2):233-8. [PMID]
- [9] Qiu S, Divine GW, Palnitkar S, Kulkarni P, Guthrie TS, Honasoge M, et al. Bone structure and turnover status in postmenopausal women with atypical femur fracture after prolonged bisphosphonate therapy. *Calcified Tissue International*. 2017; 100(3):235-43. [DOI:10.1007/s00223-016-0223-6] [PMID] [PMCID]
- [10] Kim SY, Schneeweiss S, Katz JN, Levin R, Solomon DH. Oral bisphosphonates and risk of subtrochanteric or diaphyseal femur fractures in a population-based cohort. *Journal of Bone and Mineral Research*. 2011; 26(5):993-1001. [DOI:10.1002/jbmr.288] [PMID] [PMCID]
- [11] Gedmintas L, Solomon DH, Kim SC. Bisphosphonates and risk of subtrochanteric, femoral shaft, and atypical femur fracture: A systematic review and meta-analysis. *Journal of Bone and Mineral Research*. 2013; 28(8):1729-37. [DOI:10.1002/jbmr.1893] [PMID] [PMCID]
- [12] Lee YK, Ahn S, Kim KM, Suh CS, Koo KH. Incidence rate of atypical femoral fracture after bisphosphonates treatment in Korea. *Journal of Korean Medical Sciences*. 2018; 33(5):e38. [DOI:10.3346/jkms.2018.33.e38] [PMID] [PMCID]
- [13] Lovy AJ, Patterson D, Skeeles L, Ghillani R, Joseph D, Wu Y, et al. Atraumatic segmental atypical femur fracture secondary to bisphosphonate use: A case report. *Journal of Clinical Orthopaedics and Trauma*. 2017; 8(1):S67-71. [DOI:10.1016/j.jcot.2017.03.005] [PMID] [PMCID]
- [14] Bubbear JS. Atypical femur fractures in patients treated with bisphosphonates: Identification, management, and prevention. *Rambam Maimonides Medical Journal*. 2016; 7(4):e0032 [DOI:10.5041/RMMJ.10259] [PMID] [PMCID]
- [15] Eisenstein N, Kasavkar G, Bhavsar D, Khan FS, Paskins Z. Incidence and medical management of bisphosphonate-associated atypical femoral fractures in a major trauma centre: A retrospective observational study. *BMC Musculoskeletal Disorders*. 2017; 18(1):29. [DOI:10.1186/s12891-017-1392-9] [PMID] [PMCID]
- [16] Maheshwari AV, Yarmis SJ, Tsai J, Jauregui JJ. Progression of bisphosphonate-associated impending atypical femoral fracture despite

prophylactic cephalomedullary nailing: A case report and review of literature. *Journal of Clinical Orthopaedics and Trauma*. 2016; 7(Suppl 1):92-8. [DOI:10.1016/j.jcot.2016.06.003] [PMID] [PMCID]

[17] Mir SA, Alanii FM. Long-term use of bisphosphonates in osteoporosis. *Saudi Medical Journal*. 2017; 38(8):873-4. [DOI:10.15537/smj.2017.8.20748] [PMID] [PMCID]

[18] Găleşanu C, Mocanu V, Buzdugă C, Florescu A, Zaharia V, Lisnic V. Atypical femoral fractures after long-term bisphosphonates therapy: Case report. *Bone Abstracts*. 2016; 5:386. [DOI:10.1530/boneabs.5.P386]