

# Evaluation of Image Magnification in Digital Panoramic Radiography

## Original Article

Maryam Paknahad<sup>1</sup>, Mahvash Hasani<sup>1</sup>, Mahsa Hasani<sup>2</sup>, Alireza Evazpour<sup>3</sup>

<sup>1</sup>Assistant Professor, Oral Radiology Department, Dental School, Shiraz University of Medical Sciences, Shiraz, Iran.

<sup>2</sup>Undergraduate student, Medical School, Shiraz University of Medical Sciences, Shiraz, Iran.

<sup>3</sup>Undergraduate student, Dental School, Shiraz University of Medical Sciences, Shiraz, Iran.

Received: Oct 19, 2015

Accepted: May 23, 2016

### **Corresponding Author:**

**Mahvash Hasani**

### **Address:**

Oral Radiology Department, Shiraz Dental School, Ghasrodasht Street, Shiraz 7144833586, Iran.

**Telephone:** +98-711-2292680

**Fax:** +98-711-2292680

**Email:** hasani\_m@sums.ac.ir

## **Abstract**

### **Introduction:**

The aim of the present study was to investigate image magnification in digital panoramic radiography and assess the effect of anatomical sites on the magnification in both males and females.

### **Materials and methods:**

In this retrospective study, digital panoramic radiographs of 48 patients with 202 implants were investigated. Implant diameter and length were measured on panoramic radiographs and the horizontal and vertical magnification rates of each placed area were calculated based on the length and width of the placed implant. A two-way ANOVA test was used to evaluate the magnification rate in regard to implant location and gender.

### **Results:**

The range of the magnification factor of the width was 111.09–126.02, which was lowest in the maxillary molar region and greatest in the mandibular anterior region. While the lowest magnification value of the length (111.58) was observed in the mandibular molar region, the highest value (116.09) appeared in the maxillary premolar area. Hence, there were no significant differences in image magnification with regard to anatomical site and gender.

### **Conclusion:**

Digital panoramic radiography can be reliably used for pre-implant evaluation in various anatomical sites of the jaws in both genders.

**Key words:** •Radiography• Panoramic  
• Radiographic Magnification• Dental Implants

## Introduction

Dental implants have been successfully used for replacing missing teeth over the past few years.<sup>(1)</sup> A thorough radiographic assessment for the selection of an appropriate implant size is considered as an important prerequisite for preoperative evaluation of patients for implant therapy.<sup>(2)</sup> According to the European Association for Osseointegration, cross-sectional imaging is recommended in borderline cases with limited bone height and width. Panoramic radiography has been widely used as the first choice in implant treatments because of its low radiation dose, low cost, and accessibility.<sup>(2,3)</sup> Vazquez et al.<sup>(4)</sup> have suggested that panoramic radiograph is sufficient for measuring the height of alveolar bone in the mandibular posterior region before implant surgery. Panoramic radiographs provide information on the position of the mandibular canal and maxillary sinus floor, overall shape of the jaws, and the presence of asymptomatic lesions in the jaw. However, image magnification in the horizontal and vertical planes is one of the disadvantages of panoramic radiography, which varies considerably.<sup>(4)</sup> This magnification should be considered when selecting the most appropriate implant size for a region.<sup>(5)</sup> Few studies have evaluated the magnification of digital panoramic radiography and the impact of anatomical location and gender on image magnification.<sup>(6-8)</sup> Kim et al.<sup>(7)</sup> found significant differences between the magnification of the length of inserted implants in the mandible and maxilla, which is consistent with the results of the studies conducted by Bashizade et al.<sup>(9)</sup> and Park et al.<sup>(10)</sup> Yong Geun Choi et al.<sup>(6)</sup> pointed out that the radiographic magnification of the width was influenced by gender, whereas the magnification of implant length was influenced by anatomical location.<sup>(6)</sup> Vazquez et al., however, showed that the vertical magnification of dental implants was unrelated to the mandibular sites and gender.<sup>(4)</sup> Therefore, because there is controversy over the influence of gender and anatomical location on the magnitude of the radiographic magnification in panoramic radiographs, the aim of the present study was to assess and compare the vertical and horizontal magnification rates in panoramic radiography in different areas of the mandible and maxilla.

## Materials and Methods

This retrospective study was conducted on dental records and panoramic radiographs of 48 patients (29 men, 19 women) treated with implants from January 2014 to June 2014. All panoramic radiographs were taken with a digital system (Planmeca, Helsinki, Finland) in a 1:1 mode. The radiographs with high technical standards (appropriate density, contrast, and sharpness) were included in the study. A total of 202 implants were evaluated and the study was approved by the Ethics Committee of Shiraz Medical University. Patients' age had a range of 32–80 years (mean age:  $57.4 \pm 8.3$  years). The distribution of the implant sites is described in Table 1. The maximum dimension of implant length (along the edge of the implant from the implant's apex to the most coronal point of the implant) and width at the collar region were measured on panoramic radiographs under standardized conditions by a trained senior dental student using an image measurement program (OsiriX imaging software) (Figure 1). To reduce measurement errors, only one implant model (Intra-lock, USA) was included. The dimensions of the implant fixture placed corresponded to the width and length of the fixture suggested by the implant manufacturer. The examiner was blinded to the length and width of the implant placed as well as to the patients' gender.

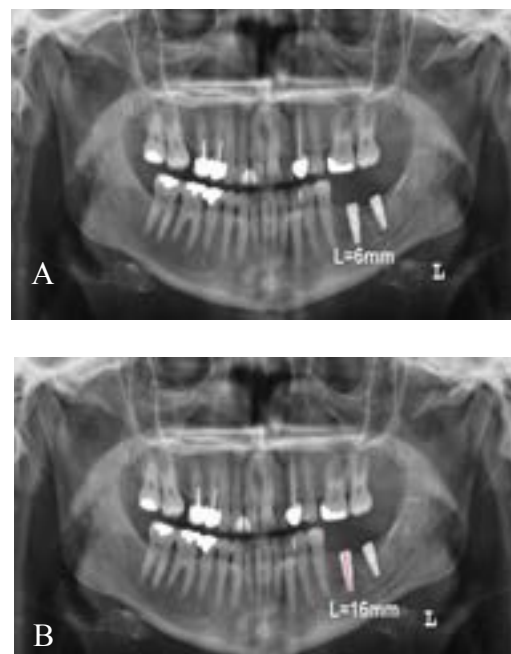


Figure 1. Measuring the width (A) and length (B) of implants in a sample patient

The magnification rate of the width and length was calculated as follows:

$$\text{The magnification rate of length} = \frac{\text{The length of implant on radiograph}}{\text{The actual length of the placed implant}} \times 100$$

$$\text{The magnification rate of width} = \frac{\text{The width of implant on radiograph}}{\text{The actual width of placed implant}} \times 100$$

The data was analyzed using SPSS version 16 (SPSS Inc., Chicago, IL, USA) at a 5% significance level. The two-way ANOVA test was used to evaluate the statistical significance of the difference in magnification rates for width and length of the implant in regards to anatomic locations (among different anatomic locations). The paired t-test was used to determine the difference of magnification rate in regards to gender.

To assess intra-observer reliability, the researcher, measured 10% of the radiographs again after 2 weeks. The paired t-test was then used to determine the difference in magnification rates between dual measurements.

## Results

The intra-observer reliability was good and the correlation coefficients for length and width were 0.89 and 0.85, respectively. There was no significant difference between the actual implant length and that of the radiographic implant.

There was no significant difference in the magnification of width and length for the implant in regard to gender. In other words, the magnification rate of the width and the length was not significantly different between males and females.

The range of magnification factor for the width was 111.09–126.02 and was lowest in the maxillary molar region and greatest in mandibular anterior region. While the lowest magnification value of the length (111.58) was observed in the mandibular molar region, the highest value (116.09) appeared in the maxillary premolar area (Table 1). However, there were no significant differences between magnification rate of width and length according to the anatomic location of the implant (Table 2).

Based on the one-way ANOVA results, when the effect of different jaws were controlled, there was no significant difference between mean magnification rate for width and positions in the jaw ( $p = 0.346$ ). Moreover, the mean magnification of width was not statistically different between the two jaws ( $p = 0.063$ ) when the effect of different positions was controlled. Interestingly, there was no significant interaction effect between different jaws and anatomical positions ( $p = 0.984$ ). By controlling the effect of the jaw, there was no significant differences between the magnification rate of length in different positions ( $p = 0.992$ ). Similarly, by controlling the effect of the position, no significant difference was found for the magnification rate of length in different jaws (Figure. 2).

Table 1. The distribution of the implant sites in the present study

Position	Magnification rate of width			Magnification rate of length			
	N	Mean	SD	N	Mean	SD	
Maxilla	Anterior	38	117.58	17.23	38	115.35	13.82
	Premolar	14	112.65	12.83	14	116.09	10.75
	Molar	27	111.09	18.12	27	113.74	11.60
Mandible	Anterior	50	126.02	21.94	50	111.80	10.65
	Premolar	40	118.22	15.90	40	115.31	8.75
	Molar	33	124.89	43.51	33	111.58	8.30

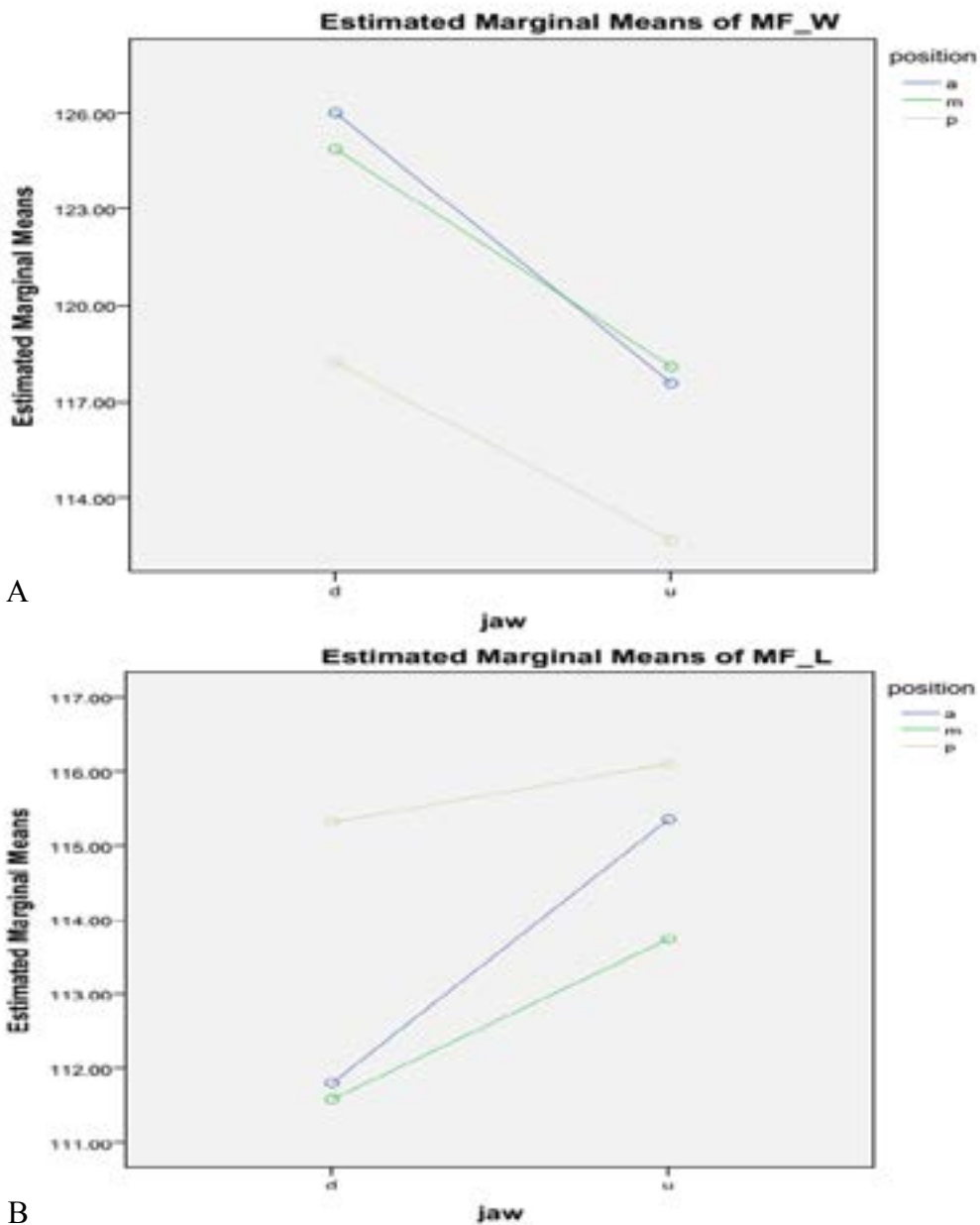
SD: standard deviation

**Table 2.** Two-way ANOVA results for magnification of width and length

	Effect	Sums of squares	df	Mean square	F	P
Width	Position	1259.599	2	629.800	1.067	0.346
	Jaw	2062.411	1	2062.411	3.492	0.063
	Position* jaw	62.621	2	31.311	0.053	0.984
	error	115743.722	196	590.529	-	-
	total	3063376.728	202	-	-	-
Length	Position	231.160	2	115.580	0.992	0.373
	Jaw	200.327	1	200.327	1.719	0.191
	Position* jaw	56.057	2	28.028	0.241	0.786
	error	22835.905	196	116.510	-	-
	total	2634382.820	202	-	-	-

SS:Sum of Square, d.f: degrees of freedom, MS: Mean Square

ANOVA: Analysis of variance



**Figure 2.** The association between magnification of width (A) and length (B) of the implants regarding anatomical site

## Discussion

The present study investigated image magnification of panoramic radiographs according to anatomical position and gender. Image magnification can be influenced by different factors, such as patient position, jaw shape and size, mandibular angulation, implant types, gender, and anatomical site in the jaw.<sup>(6, 10)</sup> A thorough radiographic examination is essential for pre-implant diagnosis and treatment planning.<sup>(4)</sup> Different imaging modalities have been used for pre-implant evaluation, including intraoral preapical radiography, lateral cephalometry, conventional tomography, computed tomography (CT), and cone-beam computed tomography (CBCT). Each radiographic technique has its own limitations and applications.

Panoramic radiography, which is considered as the standard radiographic modality for implant treatment planning, provides an overview of the teeth and surrounding structures. Panoramic radiography, however, is a low-dose and low-cost modality in comparison with other modalities, such as CT and CBCT.<sup>(11-13)</sup>

One of the limitations of panoramic radiography is the magnification in both a horizontal and vertical direction.

Different factors, such as patient position, type of equipment, anatomic location in the arch, gender, and patient's jaw size and shape, may considerably affect the degree of magnification in digital panoramic radiography.<sup>(5, 6, 14)</sup> Furthermore, panoramic radiographs provide two dimensional (2D) images, which propose certain limitations, such as distortion and superimposition of adjacent structures that may limit its use in some cases.

To increase the chance of success in implant placement, the dentist should consider the degree of magnification when selecting the most appropriate implant size.<sup>(5)</sup> Selecting the implant size precisely could enhance the survival rate of the implant and reduce the risk of complications especially when neighboring vital structures that are in close proximity to the implant site. It has been reported that the survival rate of the short and narrow implants are significantly lower than that of standard implants.<sup>(15, 16)</sup>

Different approaches have been suggested for calculating the degree of magnification includ-

ing developing a mathematical theory and using a reference calibration method with known dimensions such as a ball, autoclave cylinder markers and gutta percha markers.<sup>(17)</sup> The standard calibration method works by using a transparent template, which considers a magnification of 1.25 for all panoramic radiographs or may use the mean magnification factor of 1.25 without using a template.<sup>(17, 18)</sup> In previous studies, different factors influencing image magnification in panoramic radiographs, such as radiographic technique, patient positioning, jaw size and shape, gender, and anatomical location, have been evaluated.<sup>(2, 19, 20)</sup>

In the present study, the magnification factor of the width was lowest in the maxillary molar region and greatest in the mandibular anterior region. While the lowest magnification value of the length was observed in the mandibular molar region, the highest value appeared in the maxillary premolar area. According to the results of Kim et al.<sup>(7)</sup> and Gomez-Roman et al.<sup>(5)</sup>, the diameter of the implant was enlarged mostly in the mandibular anterior area, which was consistent with the findings of the present study. Because the curvature level of the jaw is different in each individual and can be affected by patient positioning during imaging, a higher magnification rate in the anterior area of the jaw can be seen.<sup>(21)</sup> In a study by Lars Schropp et al., maximum magnification factor in the panoramic radiographs was observed in the molar maxillary area.<sup>(17)</sup> Bashizade et al., however, showed that radiographic magnification in analog panoramic radiographs was specified by anatomic location. They found that the maximum and minimum vertical magnification was in the anterior region of the maxilla and posterior region of the mandible, respectively.<sup>(9)</sup> The difference in the results of Bashizade et al. with those of this study may be due to smaller sample size, application of analog panoramic radiographs, and considering CT scans as a gold standard for determining the magnification in panoramic radiographs.

Choi et al. evaluated the effect of patient's gender and anatomic locations of implants on image magnification. They concluded that the magnification of implant diameter (width) was significantly higher in women. However, gender did not affect the implant length magnification.<sup>(6)</sup> Kim et al. also showed that the magnification

rate of the width and length of implants according to gender was not significantly different.<sup>(7)</sup> Similarly, in the present study, no differences in magnification for width and length were found in regards to gender.

Similar to our findings, Vazquez et al. concluded that the vertical magnification of dental implants was unrelated to the mandibular sites and gender.<sup>(4)</sup> However, Choi et al. found that, while anatomic location failed to affect the magnification of the width of the implant, it affected that of the implant length.<sup>(6)</sup> Jun-Beom Park concluded that the radiographic magnification of the implant may be influenced by anatomical sites.<sup>(10)</sup> Likewise, Kim et al. found the magnification rate of the width and the length was significantly different depending on the anatomic location.<sup>(7)</sup> The factors such as the difference in the jaw size and shape because of variation in the ethnicity of the studied patients, implant types, and radiographic machine are important factors, which explain the disparity between the yielded results. Furthermore, other variables, such as the patient's head positioning and the observer's experience given to the task of measuring, may influence the accuracy of the results.

The focal variation in different radiographic panoramic equipment, which may affect the radiographic magnification.<sup>(6)</sup> Therefore, owing to the influence of the radiographic equipment on radiographic magnification, in the present study, all radiograph records were taken with the same machine. Furthermore, the examiner was blinded to the actual length and width of the implant and the patients' gender to minimize any bias. Considering the possible effect of implant types on implant magnification<sup>(7)</sup>, the radiographs of the same implant type (submerged type) were investigated.

## References

1. Misch CE, Perel ML, Wang H-L, Sammartino G, Galindo-Moreno P, Trisi P, et al. Implant success, survival, and failure: the International Congress of Oral Implantologists (ICOI) pisa consensus conference. *Implant dentistry*. 2008;17:5-15.
2. McDavid WD, Dove SB, Welander U, Tronje G. Dimensional reproduction in direct digital rotational panoramic radiography. *Oral surgery, oral medicine, oral pathology*. 1993;75:523-7.
3. Cho Y. Diagnostic value of dental CT (DentaScan) in dental implant. *Chungbuk Med J*. 1998;8:11-9.
4. Vazquez L, Nizamaldin Y, Combescure C, Nedir R, Bischof M, Ehrenfest DD, et al. Accuracy of vertical height measurements on direct digital panoramic radiographs using posterior mandibular implants and metal balls as reference objects. *Dentomaxillofac Radiol*. 2013;42: 20110429.
5. Gomez-Roman G, Lukas D, Beniashvili R, Schulte W. Area-dependent enlargement ratios of panoramic tomography on orthograde patient positioning and its significance for implant dentistry. *The International journal of oral & maxillofacial implants*. 1998;14:248-57.
6. Choi Y-G, Kim Y-K, Eckert SE, Shim C-H. Cross-sectional study of the factors that influence radiographic magnifica-

Therefore, digital panoramic radiography can be reliably used for pre-implant evaluation in various anatomical sites in both genders.

The study also had some limitations. Some variables, such as jaw size and shape and patient positioning, may influence the image magnification. However, these factors were not considered in this retrospective study. Further investigation is recommended to overcome these limitations. In conclusion, according to the present study, there was no significant difference in image magnification with regards to anatomical site and gender.

## Conclusion

The radiographic magnification of dental implants was not influenced by gender and anatomic location. Therefore, digital panoramic radiography is an effective and simple method for pre-implant diagnosis and treatment planning that can be applied in different anatomical sites in both genders.

## Acknowledgement

The authors thank the Vice-Chancellery of Shiraz University of Medical Sciences for supporting this research (Grant #6754). This manuscript is based on the thesis by Dr. Alireza Evazpour. The authors would like to thank Dr. Amalsaleh for her suggestions and providing English language editing of this manuscript. The authors also thank Dr. M. Vosoughi of the Center for Research of the School of Dentistry for statistical analysis.

## Conflict of Interest

No potential conflict of interest relevant to this article was reported.

- tion of implant diameter and length. *The International journal of oral & maxillofacial implants*. 2003;19:594-6.
7. Kim Y, Park J, Kim S, Kim J, Kim J. Magnification rate of digital panoramic radiographs and its effectiveness for pre-operative assessment of dental implants. *Dentomaxillofac Radiol*. 2014;<http://dx.doi.org/10.1259/dmfr/20544408>.
  8. Molaei N, Teimoorinezhad A. Evaluation of vertical magnification of panoramic radiography by CT scan sections for dental implant. *Journal of Dental Medicine*. 2013;26:64-70.
  9. Bashizade H, Molaei N, Teimoorinezhad A. Evaluation of vertical magnification of panoramic radiography by CT scan sections for dental implant. *Journal of Dental Medicine*. 2013;26:64-70.
  10. Park J-B. The evaluation of digital panoramic radiographs taken for implant dentistry in the daily practice. *Med Oral Patol Oral Cir Bucal*. 2010;15:e663-6.
  11. Angelopoulos C, Bedard A, Katz JO, Karamanis S, Parissis N, editors. *Digital panoramic radiography: An overview*. *Seminars in Orthodontics*; 2004; 10:194-203. Elsevier.
  12. Farman AG, Farman TT. Extraoral and panoramic systems. *Dent Clin North Am*. 2000;44:257-72.
  13. Van der Stelt PF. Principles of digital imaging. *Dent Clin North Am*. 2000;44:237-48.
  14. Reddy M, Mayfield-donahoo T, Vanderven F, Jeffcoat M. A comparison of the diagnostic advantages of panoramic radiography and computed tomography scanning for placement of root form dental implants. *Clinical oral implants research*. 1994;5:229-38.
  15. Winkler S, Morris HF, Ochi S. Implant survival to 36 months as related to length and diameter. *Annals of Periodontology*. 2000;5:22-31.
  16. Ferrigno N, Laureti M, Fanali S, Grippaudo G. A long-term follow-up study of non-submerged ITI implants in the treatment of totally edentulous jaws. *Clinical Oral Implants Research*. 2002;13:260-73.
  17. Schropp L, Stavropoulos A, Gotfredsen E, Wenzel A. Calibration of radiographs by a reference metal ball affects pre-operative selection of implant size. *Clinical oral investigations*. 2009;13:375-81.
  18. Misch CE. *Contemporary implant dentistry*: Elsevier Health Sciences; 2007.
  19. Treasure P, Chandler NP, Wilson CG. Image shift of intracoronal pins viewed on bite-wing and panoramic radiographs. *Oral surgery, oral medicine, oral pathology*. 1994;77:80-5.
  20. Szabo G, Keck B, d'Hoedt B. Präimplantologische Diagnostik mit individuellen Röntgenschablonen im Orthopantomogramm. *Z Zahnärztl Implantol*. 1991;7:33-6.
  21. BouSerhal C, Jacobs R, Quirynen M, Steenberghe D. Imaging technique selection for the preoperative planning of oral implants: a review of the literature. *Clinical implant dentistry and related research*. 2002;4:156-72.

Archive of SID