

Case Report

Lacunar infarction in child with Protein S deficiency: a case report

Azarpeikan.SAR¹ MD, Hashemi.A² MD, Atefi.A³ BSc

1- Shahid Sadoughi University of Medical Sciences and Health Services, Yazd, Iran

2- Department of Pediatrics, Hematology, Oncology and Genetics Research Center, Shahid Sadoughi University of Medical Sciences and Health Services, Yazd, Iran

3- Hematology, Oncology and Genetics Research Center, Shahid Sadoughi University of Medical Sciences and Health Services, Yazd, Iran

Received: 22 September 2010

Accepted: 5 March 2011

Abstract

Arterial ischemic stroke defines as a new focal neurologic deficit that lasted 24 hours or longer. Stroke is relatively rare in children and incidence of cerebrovascular disease is 1 per 4000 in neonates and 1 per 7000 to 1 per 70000 in older children (1 month to 18 years). Protein S deficiency is one of the causes of the stroke in children. Major manifestations of protein S deficiency are deep venous thrombosis, superficial thrombophlebitis, and pulmonary emboli. The pathogenesis of vascular occlusion in patients with protein S deficiency is unknown. The prevalence of protein S deficiency is between 1% to 7% for first episode of deep venous thrombosis.

We present a case of the 6-year-old boy with a history of tonic clonic sizure within a period of 3 years. He subsequently developed acute aphasia and right hemiparesis. Brain magnetic resonance imaging revealed lacunar infarction. Laboratory finding showed that low level of total protein S. The patient was treated with intravenous heparin and patient completely improved.

There are no evidence based strategies for the treatment of children with prothrombotic abnormality (because of the lack of research on this subject). How ever this patient completely improved and discharged with oral anticoagulant.

Keywords:

Pediatric, protein S deficiency, CVA

Corresponding Author:

Azamsadat Hashemi, Pediatric Hematologist & Oncologist, Assistant professor – Hematology, Oncology and Genetics Research Center, Shahid Sadoughi Hospital ,Yazd- Iran Email:dr_a_hashemi@yahoo.com

Introduction

Arterial ischemic stroke (AIS) was defined as a new focal neurologic deficit, which could continue 24 hours or longer due to a vascular process (1). AIS have been considered a rare event with unknown pathophysiology and doubtful evaluation and treatment. Incidence has been estimated at 1 per 4000 in neonates and 1 per 7000 to 1 per 70000 in older children (1 month to 18 years) (2, 3). It is serious disease and predisposing factors should be revealed to identify patients at risk and establish best treatment. Local or systemic infections, vascular trauma, cancer, acute lymphoblastic leukemia, drug toxicity, lupus erythematosus, nephrotic syndrome, dehydration, asphyxia, maternal problems during pregnancy, behcet's disease, and metabolic disorders have been described as predisposing factors (4).

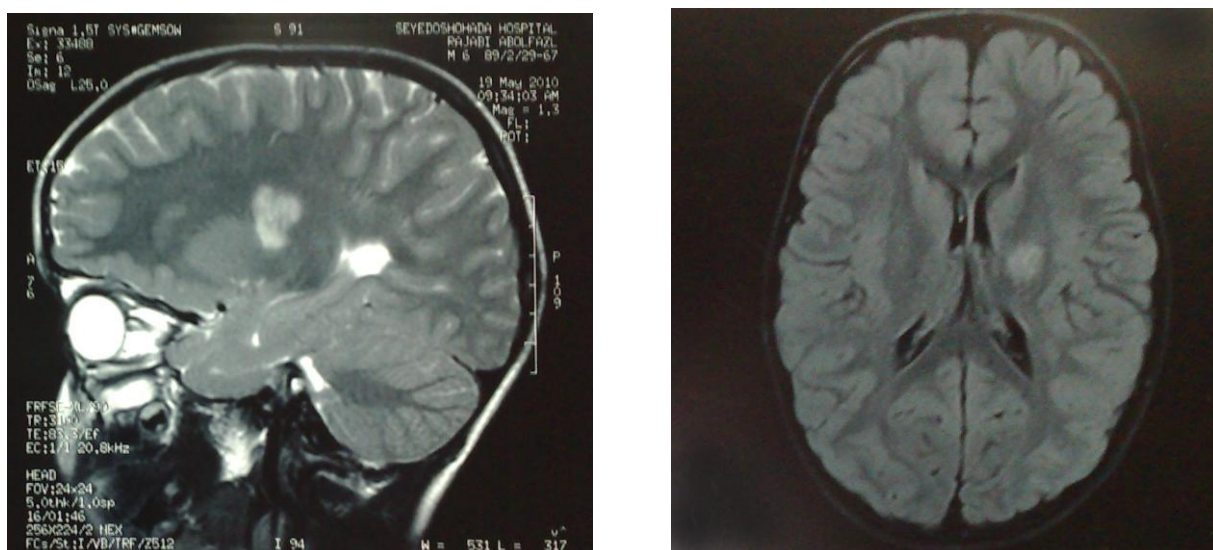
Prothrombotic disorders have been received special attention during the past decade, because thromboembolic events are major cause of AIS in children (5). Protein S is an antithrombotic plasma protein that serves as a cofactor of activated protein C anticoagulant activity (6). Hereditary protein S deficiency is an autosomal dominant disorder, which was described in 1984 in several kindreds with low level of protein S and a striking history of recurrent thrombosis (7). There was reported about 10% in families with inherited thrombophilia (8-9). The most common non genetic cause of protein S deficiency is inflammatory illnesses, which activates the complement system. It leads to increase binding of protein S to C4b and causes free protein S deficiency (10). The mean age at the first thrombotic event among 71 patients with heterozygous protein S deficiency was 38 years with a range of 15 to 68 (11) and this is rare in 6 years old however Homozygous protein S deficiency present in neonatal with fulminant purpura (12).

Case report

A 6-year-old boy admitted with acute aphasia and right sided hemiparesis without loss of consciousness. He has history of tonic-clonic seizures from 3 years ago, without any investigation for seizures. Patient received anticonvulsant drugs only 2 month before onset of cerebrovascular infarction. Neurological examination was right sided hemiparesis and upward right babinski reflex. General physical examination was normal. Patient was hospitalized and treated with intravenous heparin. After 3 days, his condition completely improved and patient discharged with oral anticoagulant. Family history was negative for thrombosis, protein S deficiency or other anticoagulant.

Brain CT after 1 day was unremarkable (Fig.1) and brain MRI after 1 week demonstrated hyper intense foci in left internal capsule and left gangliothalamic region. It suggested a cerebrovascular accident (lacunar infarction). Electrocardiogram (EEG) was normal. Chest X ray, echocardiogram and routine hematological examination with lipid profile, and coagulation profile were unremarkable. Plasma amino acid, vasculitis profile, and metabolic profile (including homocystein, ammonia, and lactate) were normal. Hemoglobin electrophoresis was normal. Protein S level of patient was measured three times, 1, 3 and 6 months after the lacunar infarction. Total protein S level were 56%, 42%, 36% (N=65_125%). The concentration of antithrombin III, fibrinogen, protein C and factor V Leiden were within normal ranges. Total protein S level of his parents was normal.

Fig1: Brain MRI demonstrating lacunar infarction in left internal capsule and left gangliothalamic region



Discussion

Many international case_control studies have demonstrated an association between prothrombotic abnormalities and AIS in children. The most associated have been reported for elevated lipoprotein (a), protein C deficiency, factor V leiden, factor II G20210A mutation, and antithrombin III deficiency.

Major manifestation of protein S deficiency is deep venous thrombosis, superficial thrombophlebitis, and pulmonary emboli. Ischemic stroke has been reported as a rare manifestation of protein S deficiency. In a study the mean age at the first thrombotic event among 71 patients with heterozygous protein S deficiency was 38 years with a range of 15 to 68 (11) and homozygous protein S deficiency usually present in neonate (12). However, in this case report, the patient was presented in 6 years old. This show that protein S deficiency can present in all age groups. The identification of a prothrombotic factor in an infant with AIS assists for determination of cause and recurrent risk, which might have implication for prevention of systemic thrombosis and screening family member (13).

Girolami et al. and sie et al. described first familial deficiency of protein S as a cause of ischemic stroke in young people (14, 15). Ranzan J reported protein S deficiency occurred in 22.5% of 46 cases of AIS under 18 years (16). Carod_A et al. reported prevalence of protein S deficiency in 130 young patients with stroke was 11.5% (17). Gansan et al. reported prothrombotic abnormality in 67 children with AIS was 12% that one of them had protein S deficiency (10). Heller et al. reported 84 (56.4%) of the 149 children with cerebral venous thrombosis had at least 1 established prothrombotic risk factor, but one of them had protein S deficiency (0.7%) (4). Lynch et al. reported prothrombotic abnormality in 63% of children with AIS (36 of 57) but in this study non of them had protein S deficiency (1). Mayer et al. also supported the fact that acquired deficiency of free protein S is not a major risk factor for ischemic stroke (18). Ranzan et al. described that seizure was the most prevalence symptom, principally the focal crisis (55%) followed by hemiparesis (42%) in 46 children with AIS (16). Ganesan et al. found that hemiparesis was the most prevalence symptom in the initial phase (83%) followed by seizure (33%) in children after 3 month age (19). Bonduel et al. also in a study with infant described that hemiparesis and seizure were the most initial symptoms (5).

Conclusion

There are no evidence based strategies for the treatment of children with prothrombotic abnormality and AIS and this could be because of the lack of research on this subject how ever this patient completely improved and discharged with oral anticoagulant.

Antithrombotic therapy is recommended in adult for acute event and as prophylaxis in high risk situations and may be useful in children with prothrombotic abnormality. The response and long term complication of antithrombotic therapy are not the same in adult and child (20). Clinical trial is needed to determine the indication and best treatment for children with prothrombotic abnormality.

References

- 1- Lynch JK, Han CJ, Nee LE. Prothrombotic factors in children with stroke or porencephaly. *Nelson KB. Pediatrics.* 2005;116:447-453
- 2- Early CJ, Kittner SJ, Feeseer BR, et al. Stroke in children and sickle-cell disease: Baltimore-Washington Cooperative Young Stroke Study. *Neurology.* 1998;51:169-176.
- 3- Giroud M, Lemesle M, Gouyon JB, et al. Cerebrovascular disease in children under 16 years of age in the city of Dijon, France: a study of incidence and clinical features from 1985 to 1993. *J Clin Epidemiol.* 1995;48 :1343-1348.
- 4- Heller C, Hinecke A, Junker R, et al. Cerebral venous thrombosis in children: a multifactorial origin. Childhood Stroke Study Group. *Circulation.* 2003 ; 108(11):1362-1367.
- 5- Bonduel M, Sciuccati G, Hepner M, Torres AF, Pieroni G, Frontroth JP. Prethrombotic disorders in children with arterial ischemic stroke and sinovenous thrombosis. *Arch Neurol* 1999; 56:967-971.
- 6- Walker FJ. Regulation of activated protein C by a new protein. *J Biol Chem* 1980; 255:5521-5524.
- 7- Comp PC, Nixon RR, Cooper MR, et al. Familial protein S deficiency is associated with recurrent thrombosis. *J Clin Invest* 1984; 74:2082-2088.
- 8- Gandrille S, Brgel D, Ireland H, et al. Protein S deficiency: a database of mutations. For the Plasma Coagulation Inhibitors Subcommittee of the Scientific and Standardization Committee of the International Society on Thrombosis and Haemostasis. *Thromb Haemost.* 1997; 77:1201-1214.
- 9- Heijboer H, Brandjes DPM, Buller HR, et al. Deficiencies of coagulation-inhibiting and fibrinolytic proteins in outpatients with deep venous thrombosis. *N Engl J Med.* 1990;323:1512-1516.
- 10- Ganesan V, McShane M A, Liesner R. Inherited prothrombotic states and ischaemic stroke in childhood. *J Neurol Neurosurg Psychiatry* 1998; 65:508-511.
- 11- Engesser L, Broekmans AW, Briet E, et al. Hereditary protein S deficiency: clinical manifestations. *Ann Intern Med.* 1987; 106:677-682.
- 12- Pegelow CH, Ledford M, Young J, et al. Severe protein S deficiency in a newborn. *Pediatrics.* 1992; 89:674-676.
- 13- deVeber G, Monagle P, Chan A, et al. Prothrombotic disorders in infants and children with cerebral thromboembolism. *Arch Neurol.* 1998; 55 :1539 –154.
- 14- Girolami A, Simioni P, Lazzaro AR, Cordiano I. Severe arterial thrombosis in a patient with protein S cerebral deficiency (moderately reduced total and markedly reduced free protein S): A family study. *Thromb Haemost.* 1989; 61:144–7.
- 15- Sie P, Boneu B, Bierme R, Wiesel ML, Grunebaum L, Cazenave JP. Arterial thrombosis and protein S deficiency. *Thromb Haemost.* 1989; 62:1040.
- 16- Ranzan J, Rotta NT. Ischemic stroke in children: a study of the associated alterations. *Arq. Neuro-psiquiatr.* 2004; 62(3A):618-625.
- 17- Carod-Artal FJ, Nunes SV, Portugal D, Silva TV, Vargas AP. Ischemic stroke subtypes and thrombophilia in young and elderly stroke patients admitted to a rehabilitation hospital. *Stroke.* 2005; 36:2012–4.
- 18- Mayer SA, Sacco RL, Hurler-Jensen A, Shi T, Mohr JP. Free protein S deficiency in acute ischemic stroke. A case-control study. *Stroke.* 1993; 24:224–7
- 19- Ganesan V, Hogan A, Shack N, Gordon A, Isaacs E, Kirkham FJ. Outcome after ischaemic stroke in childhood. *Dev Med Child Neurol* 2000; 42:455-461.
- 20- Williams MD, Chalmers EA, Gibson BE. The investigation and management of neonatal haemostasis and thrombosis. *Br J Haematol.* 2002; 119 :295 –230.