

Case Report

Infantile Fibrosarcoma in a Child: a Case Report

Hashemi A MD¹, Tefagh S MD², Seifadini A MD³, Moghimi M MD⁴

1. Department of Pediatrics, Hematology, Oncology and Genetic Research Center, Shahid Sadoughi University of Medical Sciences Health Services, Yazd, Iran.

2. MD, Hematology, Oncology and Genetics Research Center, Shahid Sadoughi University of Medical Sciences and Health Services, Yazd, Iran.

3. Medical Student, Islamic Azad University branch Yazd, Yazd, Iran.

4. Department of Pathology, Shahid Sadoughi University of Medical Sciences Health Services, Yazd, Iran.

Received: 10 June 2013

Accepted: 8 September 2013

Abstract

Background

Infantile Fibrosarcoma is a rare soft tissue tumor in infants and children mostly located in extremities. An infantile and adult form has similar histopathological patterns but survival prognosis is much better in infantile form. Recurrence of infantile fibrosarcoma is common but the rates of metastasis are less than 10 percent in children younger than five Years and 50 percent in children more than 10 years old.

Case presentation

In this case report, we presented a nine years girl with a relapsing mass in her left hand. The pathologic

findings showed sheets of spindle-shaped cells with suggested diagnose of infantile fibrosarcoma. She was successfully treated with combination of surgery and chemotherapy with a good outcome.

Conclusion

Infantile fibrosarcoma is a differential diagnose of soft tissue mass in infants and children. It has a good prognosis and distant metastasis is uncommon. Choice of treatment is surgery but chemotherapy and radiotherapy were useful in decrease metastasis.

Keywords

Infant; Fibrosarcoma; Report

Corresponding Author:

Seifadini A MD, Medical Student, Islamic Azad University branch Yazd, Yazd, Iran.
Email: Azadeh_seifaddiny@yahoo.com.

Introduction

Infantile fibrosarcoma is a rare early childhood malignancy. It includes approximately 10 % of all sarcomas in children (1). It is mostly presented as a tumor in extremities, trunk, head and neck. Ultimate diagnosis is made by physical examination, special radiologic studies, and biopsy (2). Infantile fibrosarcoma is spindle cell tumor originated from soft tissue. Histologically, it is similar to adult-type but with a better prognosis. In the Pediatric Oncology Group classification of NRSTS, infantile fibrosarcoma is classified as a grade I lesion. Although recurrence of infantile fibrosarcoma is common, metastatic spread is infrequent (1). Surgery is considered the main choice of treatment. The use of adjuvant therapy and chemotherapy is not clear

yet, but in most of high grade tumors are used for treatment of microscopic metastasis (3). In comparison with adults, chemotherapy is more effective in children (4). This case report, presented a nine years old girl with a mass in her hand which was relapsed locally. The tumor location, radiological and pathological findings proved the diagnosis of fibrosarcoma. In this age, infantile fibrosarcoma is rare and generally misdiagnosed because of histological similarities to benign tumors.

Case report:

A nine years old girl was presented with a mass in her left hand in polmar side. Initially, her mass was noticed four years ago with 3*4cm size which was growing gradually. After excision surgery, it was diagnosed as soft tissue mass (lypoma). She was

referred to Shahid Sadoughi clinic of pediatric oncology due to the relapse of the tumor four years later. On physical examination, a firm, immobile mass with mild tenderness and discrete borders was palpable. Her left finger movement was limited in all ranges. No other abnormalities were found in the examinations. Laboratory tests were normal.

Magnetic Resonance Imaging (MRI) findings showed 4*5cm neoplast lesion in left hand. Deformity of left hand was presented. Fifth metacarpal bone was not seen. Invasive soft tissue mass (recurrence or remained sarcoma) was suggested in MRI results.

The histology of the mass was reanalyzed because of the relapse. The findings showed sheets of spindle-shaped cells with suggested diagnose of infantile fibrosarcoma. Afterwards, excisional surgery was done and pathological report revealed cellular spindle neoplastic tissue with fascicular pattern of slightly pleomorphic tumoral cells with vesicular nuclei and occasionally prominent nucleoli admixed by foci of hemangiopericytoma like pattern. Tumoral cells infiltrated into fatty tissue, bone and skeletal muscle. In some focus more than five mitotic figures in per HPF were also seen moderate infiltrations of chronic inflammatory cell with follicular aggregation. (Figure, 1). Base on these findings infantile fibrosarcoma was the diagnosis. Metastatic work up was negative. Abdomen and pelvis scan with IV (intravenous) and oral contrast and thorax scan with IV contrast were normal. Abdomen and chest ray were normal.

After the surgery, the treatment was completed with systemic chemotherapy using oncovin, actinomycin and endoxan.

High response to chemotherapy was observed. No relapse was observed up to now.

Discussion

The main cause of infantile fibrosarcoma still remains unknown, but some gene fusions due to translocation and some trisomies have been reported(5). Infantile fibrosarcoma includes less than one percent of childhood tumors and about 10 percent of soft tissues sarcomas(1,6).

Infantile fibrosarcoma usually presents in the first five years of life, most of them under three years and about 40 percent under three months(7,8). It is rarely appears at older ages between 10 to 15 years old (9,10). In this case the patient was nine years old when diagnosed and the tumor was found 4 years earlier.

Clinically the most common sign is a local, progressive mass with no discrete borders in distal part of extremities. In some cases, the surface is necrotic or ulceric which makes the appearance similar to vascular malformations like hemangioma(4). Also it may be misdiagnosed as

other soft tissue tumors as it was misdiagnosed with lipoma in this case. MRI is a good choice for better evaluation in diagnoses and follow-up of soft tissue masses. MRI is considered the modality of choice for evaluation of the diseases in the extremities, head, neck and pelvis(11,12). In this case, MRI results were suggestive of soft tissue sarcoma. Although most of the tumors have a rapid growth manner, in this case, the growth of tumor was slow.

Two types of infantile fibrosarcomas are: Desmoplastic type and medullary type. Desmoplastic type in children resemble to adults (1). The histological diagnosis of fibrosarcoma may sometimes be difficult.

Local recurrence is reported in 7-34 percents of patients. The chance of recurrence is much more in older than younger ones. In this case, recurrence occurs after 4 years.

Distant metastasis is uncommon and was reported only in four percent of cases at the beginning of diagnoses. Children who are less than 5 years old are at the risk of relapse of tumor, whereas the incidence of metastases is under 10% in these patients. The rate of metastatic spread in children who are 10 years old or older is 50% at 5-year follow-up(13). In our patient no metastasis was found.

Infantile fibrosarcoma has a good prognosis. A five-year survival is reported 80 to 100 percent(14).

Currently, the main treatment in most cases is surgery with wide local excision which sometimes leads to amputation. Radiotherapy and chemotherapy were shown to be useful in reduction of tumors bulk especially in metastatic, relapsing and un-respectable tumors. In older children chemotherapy is offered to decrease the possibility of metastasis (11). In this case, surgery was followed by chemotherapy for two reasons: 1.the child was nine years old 2.the tumor was replacing. After treatment, complete remission was obtained.

The effective regimen for chemotherapy is vincristine, actinomycin D and cyclophosphamide. Orbach et al reported that 71% of patients with infantile fibrosarcoma responded to vincristin-actinomycin-D chemotherapy. The 5-year survival in these patients was 89% (15).

Conclusion

Although infantile fibrosarcoma is rare and usually presented after birth, but it is necessary to consider it as a differential diagnose of soft tissue mass in infants and even in children. Patients should be followed up for detecting further relapse or metastasis especially in older ages.

Acknowledgment

The authors have no acknowledgment.

Conflict of Interest

The authors have no conflict of interest.

References

- 1.Celkan T, Ozkan A, Apak H, Ibrahimi B, Dervisoglu S, Yuksel L,et al. Two different clinical presentation of infantile fibrosarcoma. Turkish Journal of cancer. 2000; 30: 81-6.
- 2.Pousti TJ, Upton J, Loh M, Grier H. Congenital fibrosarcoma of the upper extremity. Plast Reconstr Surg. 1998; 102(4): 1158-62.
- 3.Gosau M, Draenert FG, Winter WA, Mueller-Hoecker J, Driemel O. Fibrosarcoma of the childhood mandible. Head Face Med. 2008; 4: 21.
- 4.Aggouris K, Brilakis E, Giokas A. Infantile fibrosarcoma and infantile fibromatosis diagnosis and treatment clinical presentation of three cases. EEXOT. 2008; 59: 170-75.
- 5.Demir HA, Akyüz C, Varan A, Ergen FB, Büyükpamukçu M. Right foot congenital infantile fibrosarcoma treated only with chemotherapy. Pediatr Blood Cancer.2010; 54(4): 618-20.
6. Dixon NE, Morales J, Escalon E,et al. Congenital fibrosarcoma:Report of one case treated with pre-surgical chemotherapy. Int Pediatr.2003; 18(2): 87-91.
- 7.Kahn LB, Vigorita V. Fibrosarcoma of bone In World Health Organization Classification of Tumours. Pathology and Genetics of Tumours of Soft Tissue and Bone. Edited by Fletcher CDM, Unni KK, Mertens F. IARC Press, Lyon, France; 2002: 289-90.
- 8.Cecchetto G, Carli M, Alaggio R, Dall'Igna P, Bisogno G, Scarzello G,et al.Italian Cooperative Group.Fibrosarcoma in pediatric patients: results of the Italian Cooperative Group studies (1979-1995). J Surg Oncol. 2001; 78(4): 225-31.
- 9.Schofield DE, Fletcher JA, Grier HE, Yunis EJ. Fibrosarcoma in infants and children. Application of new techniques. Am J Surg Pathol. 1994; 18(1): 14-24.
- 10.Kynaston JA, Malcolm AJ, Craft AW, Davies SM, Jones PH, King DJ,et al. Chemotherapy in the management of infantile fibrosarcoma. Med Pediatr Oncol.1993;21(7):488-93.
11. McCarville MB, Kaste SC, Pappo AS. Soft-tissue malignancies in infancy.AJR Am J Roentgenol. 1999; 173(4): 973-7.
- 12.Lee MJ, Cairns RA, Munk PL, Poon PY. Congenital-infantile fibrosarcoma:magnetic resonance imaging findings. Can Assoc Radiol J. 1996; 47(2): 121-5.
- 13.Soule EH, Pritchard DJ. Fibrosarcoma in infants and children: a review of 110cases. Cancer. 1977 ; 40(4): 1711-21.
- 14.Minard-Colin V, Orbach D, Martelli H, Bodemer C, Oberlin O. [Soft tissue tumors in neonates]. Arch Pediatr.2009; 16(7): 1039-48.
- 15.Orbach D, Rey A, Cecchetto G, Oberlin O, Casanova M, Thebaud E,et al. Infantile fibrosarcoma: management based on theEuropean experience. J Clin Oncol.2010; 28(2): 318-23.

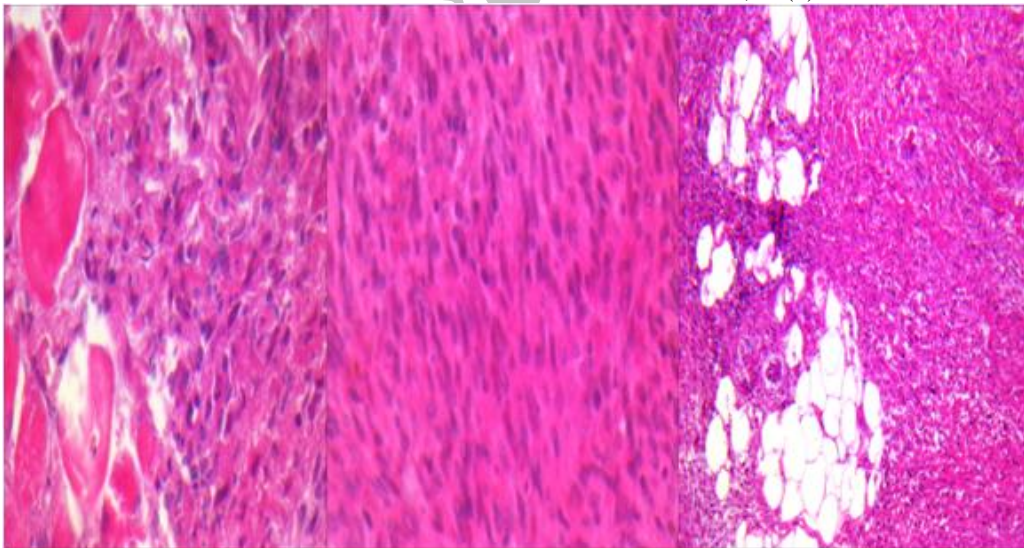


Figure1: Infantile Fibrosarcoma with High mitotic figures