

## Congenital Hemangiopericytoma: A Case Report

Mahdi Shahriari MD<sup>1</sup>, Fazl Saleh MD<sup>1</sup>, Bita Geramizadeh MD<sup>2</sup>, Sezaneh Haghpanah MD<sup>1</sup>, Mohammadreza Bordbar MD<sup>1,\*</sup>

1. Hematology Research Center, Shiraz University of Medical Sciences, Shiraz, Iran

2. Pathology department, Shiraz University of Medical Sciences, Shiraz, Iran

Corresponding author: Mohammadreza Bordbar, MD. Hematology Research Center, Nemazee Hospital, Shiraz University of Medical Sciences, Shiraz, Iran. Email: [bordbarm@sums.ac.ir](mailto:bordbarm@sums.ac.ir).

Received: 28 July 2015

Accepted: 12 June 2016

### Abstract

Hemangiopericytoma is a rare vascular tumor observed mostly in adults. It usually presents with a painless slowly enlarging mass. The infantile type with much rarer occurrence has a different course compared to adults. Very few case reports have been described in the literature with disease onset in the infancy. The first reported case of infantile hemangiopericytoma of limbs from the Middle East was described in the current study. The clinical presentation as well as diagnostic investigations and treatment options are discussed. By considering the existing information in the literature, the clinical course and outcome of this patient with similar reported cases was reported.

**Key Words:** hemangiopericytoma, infantile, treatment.

### Introduction

Hemangiopericytoma is an uncommon tumor that was first described by Stout and Murray in 1942 (1). It originates from the vascular pericytes which are contractile cells around the capillary walls. Therefore, it has a wide distribution in both soft tissue and skeletal system (2).

This tumor presents as a slowly enlarging painless mass, and generally considered to be a benign tumor, though distant metastases can occur. Histologic examination by immunohistochemical techniques is the only way to establish the diagnosis (3). Congenital or infantile hemangiopericytoma is encountered even much rarer, and till 2014, only three patients younger than 1 month have been reported in Eastern countries (4-6). Detailed report about the number of cases of congenital hemangiopericytoma in the world is lacking. Till 1998, only 86 of these tumors have been reported in the literature, which thirty of them were located in the extremities (7). A brief

description of some of these cases has been shown in Table 1. To our knowledge, this is the first case of congenital hemangiopericytoma reported in Iran.

### Case presentation

A three-month-old Iranian infant was investigated who was delivered with good APGAR score without any complication. General physical examination was completely normal, except a firm, violet-colored swelling on the ulnar aspect of left forearm measuring 4 × 2.5 cm (Figure 1A). The mass was non-tender, non-compressible, non-fluctuant, and there was no bruit on auscultation. No cervical or axillary lymphadenopathy, organomegaly or other associated congenital anomalies were detected. Complete cell blood count (CBC) and chemistry were within normal limits. Color Doppler Ultrasonography showed a hypoechoic soft tissue mass in the ulnar aspect of left forearm which consisted of multiple small vessels as well

as a few large vessels with high blood flow. With clinical diagnosis of hemangiomas malformation, the soft tissue mass was excised under general anesthesia on the second day of his life. The excised mass was sent for histopathological examination. Immunohistochemistry staining was positive for CD34 (QBEnd 10), and Vimentin (Vim 3B4), but negative for BCL2, CD31(JC70A), Cytokeratin (AE1/AE3), Desmin (D33), EMA (E29), LCA (2B11+PD7/26), MIC2 (CD99)(12E7), MYOD1 (5.8 A), and S-100, which were consistent with the diagnosis of infantile hemangiopericytoma

(Figure 1B). He was discharged on the 3rd postoperative day and was followed up in an outpatient clinic for 3 months before being referred to pediatric oncologist. There was no evidence of local recurrence or distant metastasis during the last 3 months.

The patient was treated with 4 courses of chemotherapy protocol with Cyclophosphamide 600 mg/m<sup>2</sup>, Doxorubicin 45 mg/m<sup>2</sup> and Dacarbazine 500 mg/m<sup>2</sup> repeated every 4 weeks. She is now in good general health with no evidence of tumor recurrence or distant metastasis.

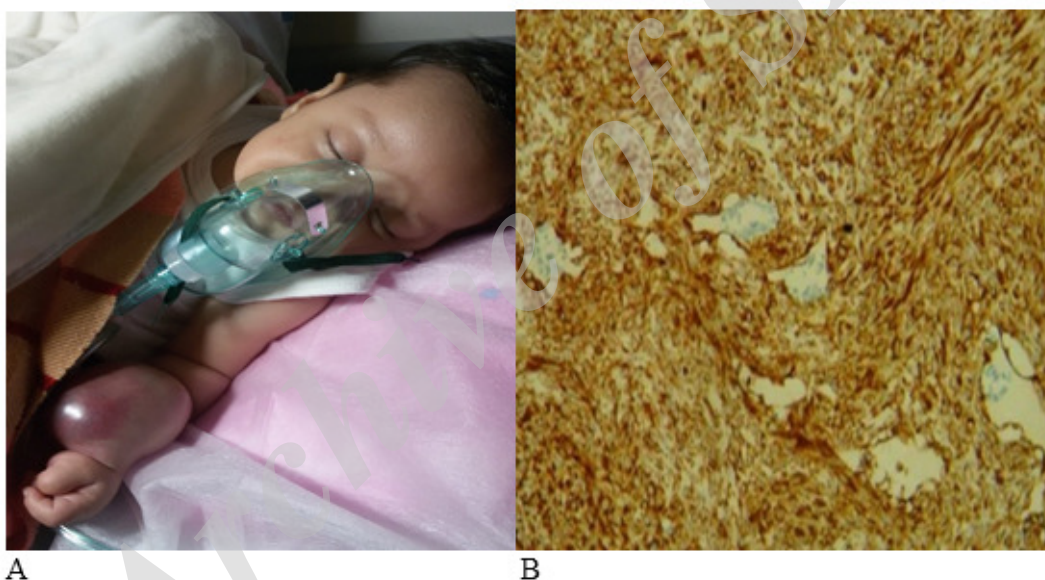


Figure 1. A: The firm, violet- colored swelling on the anterior surface of left forearm with marked surface telangiectasia. B: Sections from soft tissue mass showed a hyper cellular tumor, diffusely and strongly positive for CD34. There are some abnormal looking stag-horn type blood vessels in between.

Table I: some of the case reports of extremities hemangiopericytoma (18-22)

| Country / year.      | Age/sex   | Location of tumor   | Intervention | Treatment   | Follow – up   |
|----------------------|---|---|--------------|---|---|
| Taipei, Taiwan, 2006 | One day- female   | right inguinal  | SEB          | Chemotherapy  | NED during 12 months of follow-up   |
| Bangladesh, 2011     | 10 days - male  | right side of upper arm   | SEB          | GTR   | The patient was not available to assess remote postoperative outcome as the parents abruptly left the hospital. |
| Osaka, Japan,2000    | 4-day, male   | lower right leg   | SEB          | GTR   | Normal leg function and NED for 7 years follow-up.  |
| California, 1984     | Reported 6 cases, 2 of them in extremities.<br>1 <sup>st</sup> , 1 month ,female<br>2 <sup>nd</sup> , 3 month, male | 1 <sup>st</sup> , tumor in left thigh<br>2 <sup>nd</sup> , left antecubital fossa | SEB          | GTR in both cases.                                      | NED in both cases after 2 and 8 years follow-up<br>Respectively.  |
| New York,2010        | 6-month, girl   | right hand  | SEB          | Chemotherapy for over one year then surgical resection. | NED after one year follow-up.   |

NED= no evidence of disease SEB= surgical excision biopsy.GTR = gross-total resection

## Discussion

Hemangiopericytoma is a vascular tumor mostly observed in adults. The infantile type which comprises 5-10% of cases is histologically identical to the adult type, but is clinically more indolent and is approached more conservatively (8). The incidence is higher in boys, and usually occurs in the limbs, pelvis, or head and neck region. Approximately, 30–50% of cases occur in the extremities (9,10). Infantile type tends to be located more superficially than the adults type (11). In our case, the mass was lying subcutaneously, in the left forearm.

In an extensive review of the literature using Pubmed, Embase, Scopus and Iranmedex databases with “hemangiopericytoma, infantile, congenital” as the keywords, only three cases were reported in Eastern countries including Japan, Taiwan and India till 2014. This is the first reported case of infantile hemangiopericytoma from Iran and the Middle East.

The diagnosis can be suspected by radiography which shows a soft tissue mass, with or without calcification. Ultrasound determines the size of the lesion, vascular loops, echogenic content and whether or not a capsule is present. Angiography shows the vascular pattern and the presence of feeder vessels. CT and MRI can provide information about the extent of the tumor and help in preoperative planning. The diagnosis is confirmed by excisional biopsy and immunohistochemical study (12).

The differential diagnosis of congenital hemangiopericytoma includes all tumors which present as soft tissue mass, including: lipoma, hemangioma, and lymphangioma. Some tumors have similar histological features, such as infantile myofibromatosis, synovial sarcoma, fibrosarcoma, malignant fibrous

histiocytoma, mesenchymal chondrosarcoma, and leiomyosarcoma (13). In this case, the final diagnosis was made by excisional biopsy. The histological and immunohistochemistry features were consistent with infantile hemangiopericytoma. As the lesion was histologically malignant, it was decided to start chemotherapy for the patient as described above.

The majority of these tumors in adults tend to be highly malignant in contrast to the infantile type which are usually benign. Good response to chemotherapy, spontaneous regression, and lack of recurrence even in case of residual tumor have been reported in the infantile type (10). However, in children above 1 year old, the disease have a more malignant course similar to adults. It seems that increased age of onset is a risk factor associated with a more malignant clinical course (14).

The management of infantile hemangiopericytoma differs from that in adults, although there is no consensus on the best approach (12). Hemangiopericytoma is unresponsive to steroid therapy, unlike other vascular malformations. Wide surgical excision with safe margins is the most accepted method of treatment. Some centers use adjuvant therapy to reduce the risk of local recurrence (15). Whenever total excision is impossible or in cases of local recurrence after surgery, pre- or post-operation chemotherapy is usually advised (16).

The role of radiation therapy in infantile hemangiopericytoma is controversial (14). Jha et al. reported some success with radiotherapy when there was gross or microscopic evidence of tumor remnants after surgical excision, while others have claimed that radiotherapy is ineffective (17). This case was treated with wide surgical excision followed by four courses

of chemotherapy. His treatment has ended successfully, and he is in good general health after about 6 months of follow-up. Longer follow up with larger case series is needed to decide about the optimal treatment approach in this age group.

Infantile hemangiopericytoma is a rare vascular tumor that should be considered in the differential diagnosis of vascular malformations in pediatric age group. The diagnosis is mainly confirmed by immunohistochemistry staining. Rarely, it behaves aggressively with local infiltration, recurrences and even distant metastases. Close follow up and starting chemotherapy in times of subtotal excision, local recurrence, distant metastasis or malignant features is warranted.

### Conflict of interest

The authors declare no conflict of interest in this case report or in the production of this manuscript.

### Acknowledgments

The authors thank Dr. Ghorbanpoor M. for providing laparatomydata. We also wish to thank the patient's parents for their valuable cooperation.

### References

- 1.Carvalho JR, Haddad L, Leonhardt FD, Marques Filho MF, Santos Rde O, Cervantes O, et al. Head and neck hemangiopericytoma in a child: case report. Sao Paulo Med J 2004; 122(5):223-6.
- 2.Hatzokos I, Gigis I, Iosifidou E, Drakou A, Pournaras J. Primary Hemangiopericytoma of the Tibia. Treatment by en Bloc Resection and Bone Transportation. A Case Report. ActaOrthop Belg. 2005 Feb; 71(1):122-7.
- 3.Wilde F, Neid M, Schulz T, Sterker I, Hemprich A, Frerich B. Mund Kiefer Gesichtschir. 2005 Nov;9(6):404-8.
- 4.Hsu PY, Hsu WM, Huang HY, Chen CY, Chou HC, Tsao PN, et al. Congenital hemangiopericytoma in a neonate. J

Formos Med Assoc 2006 Mar; 105(3):247-51.

5.Hamada Y, Takada K, Akehira K, Sakaida N, Okamura A, Hioki K.. Congenital hemangiopericytoma: report of a case. Surg Today 2000; 30 (4): 386-9.

6.Anand V, Rajan R, Hazarika P, Padhee A.. Infantile hemangiopericytoma of nasal cavity. Int J Pediatr Otorhinolaryngol 1990; 18 (3):271-6.

7.Hoey SA1, Letts RM, Jimenez C. Infantile Hemangiopericytoma of the Musculoskeletal System:Case Report and Literature Review. J Pediatr Orthop. 1998 May-Jun;18(3):359-62.

8.Billings KR, Fu YS, Calcaterra TC, Sercarz JA. Hemangiopericytoma of the head and neck. Am J Otolaryngol 2000; 21:238-243.

9.Baker DL, Oda D, Myall RW. Intraoral Infantile Hemangiopericytoma: Literature Review and Addition of a Case. Oral Surg Oral Med Oral Pathol. 1992 May; 73(5):596-602.

10.Rodriguez-Galindo C, Ramsey K, Jenkins JJ, Poquette CA, Kaste SC, Merchant TE, et al. Hemangiopericytoma in children and infants. Cancer 2000; 88(1):198-204.

11.Brar R, Kulkarni S, Sheikh S, Jindal S, Brar P. Hemangiopericytoma associated with multiple keratocystic odontogenic tumors in an adolescent patient: a case report. J Oral Sci. 2008 Jun; 50(2):233-7.

12.O'Donnell TM, Devitt AT, Kutty S, Fogarty EE. Recurrent congenital haemangiopericytoma in a child. J Bone Joint Surg Br 2001 Mar; 83(2):269-72.

13.Mentzel T, Calonje E, Nascimento AG, Fletcher CD. Infantile Hemangiopericytoma Versus Infantile Myofibromatosis: Study of a Series Suggesting a Continuous Spectrum of Infantile Myofibroblastic Lesions. Am J Surg Pathol. 1994 Sep; 18(9):922-30.

14.Del Rosario ML, Saleh A. Preoperative chemotherapy for congenital hemangiopericytoma and a review of the literature. J Pediatr Hematol Oncol 1997; 19:247-50.

15. Bailey PV, Weber TR, Tracy TF Jr, O'Connor DM, Sotelo-Avila C. Congenital Hemangiopericytoma: An Unusual Vascular Neoplasm of Infancy. *Surgery*. 1993 Nov; 114(5):936-41.
16. Allt G, Lawrenson JG. Pericytes: cell biology and pathology. *Cells Tissues Organs* 2001; 169:1–11.
17. Jha N, McNeese M, Barkley HT Jr, Kong J. Does Radiotherapy Have a Role in Hemangiopericytoma Management? Report of 14 New Cases and a Review of the Literature. *Int J Radiat Oncol Biol Phys*. 1987 Sep; 13(9):1399-402.
18. Ping-Yi Hsu, Wen-Ming Hsu, Hsin-Yi Huang, Chien-Yi Chen, Hung-Chieh Chou, Wu-Shiun Hsieh. Congenital Hemangiopericytoma in a Neonate. *J Formos Med Assoc* 2006; 105(3):247-251
19. Jahan Fauzia, Ghosh PK, Khanam Rehana, Rahman Saidur. Congenital Hemangiopericytoma. *J Medicine* 2011; 12 : 89-90.
20. Hamada Y, Takada K, Akehira K, Akehira K, Sakaida N, Okamura A, Hioki K. Congenital hemangiopericytoma: report of a case. *Surg Today* 2000; 30:386–9.
21. Atkinson JB, Mahour GH, Isaacs H Jr, Ortega JA. Hemangiopericytoma in infants and children. A report of six patients. *Am J Surg*. 1984 Sep; 148(3):372-4.
22. Lisa F. Schneider, Sharon L. Gardner, Sheel Sharma. Preoperative Chemotherapy to Salvage the Hand in a Case of Giant Infantile Hemangiopericytoma. *J Hand Surg* 2010; 35A:995–998