

Pleuropulmonary blastoma: report of 2 cases

Nahid Reisi MD^{1,*}, Saeed Yosefian MD², Pardis Namatollahi MD³

1. Pediatric Oncologist, Associate Professor of Pediatric Hematology and Oncology, Faculty of Medicine, Child Growth and Development Research Center, Research Institute for Primordial Prevention of Noncommunicable Disease, Isfahan University of Medical Sciences, Isfahan, Iran.

2. Pediatric Oncologist, Assistant Professor of Pediatric Hematology and Oncology, Child Growth and Development Research Center, Research Institute for Primordial Prevention of Non-communicable Disease, Isfahan University of Medical Sciences, Isfahan, Iran

3. Anatomical and Clinical Pathologist, Assistant Professor of pathology, Isfahan University of Medical Sciences, Isfahan, Iran

*Corresponding author: Nahid Reisi, MD. Seyed Al- Shohada Hospital, Motahari Ave, Isfahan, Iran.

Email: reisi@med.mui.ac.ir

Received: 13 January 2016

Accepted: 10 April 2016

Abstract

Pleuropulmonary blastoma (PPB) is a rare, malignant intrathoracic tumor that occurs mostly in children before 5 years old. It consists about 15% of all primary pediatric pulmonary tumors and shows various mesenchymal components. Its presentations are nonspecific and common symptoms include fever, cough, chest pain, respiratory distress, and pulmonary infection. PPB should be considered in the differential diagnosis of solid and cystic lesions of thorax in children. Surgery is the main treatment of PPB that followed by chemotherapy. Radiotherapy has controversial effects on PPB. For recurrent tumors, bone marrow transplant is recommended. Two cases of this rare tumor is reported to increase the awareness about this entity and considering it in differential diagnosis of solid and cystic lesions of thorax in infants and children. The first case initially was treated with vincristine, actinomycin-D, and cyclophosphamide (VAC) regimen. Following relapse, it was scheduled with ifosfamide, vincristine, actinomycin-D and doxorubicin (IVADo) regimen and radiotherapy. Then, autologous stem cell rescue (ASCR) was recommended; but the patient was expired due to progressive disease before considering it. The second case was first treated with ifosfamide and doxorubicin alternate with ifosfamide and etoposide (IDo/ IE regimen). Following relapse, it was scheduled with ifosfamide, carboplatin and etoposide (ICE) chemotherapy regimen and he felt better.

Keywords: Intrathoracic tumors, pleuropulmonary blastoma, pulmonary tumors

Introduction

Pleuropulmonary blastoma (PPB) is a lung cancer that is very uncommon in children (1). It was described at the first time by Manivel et al. in 1988 as a distinctive neoplasm. Morphologically, it shows three subtypes and a fourth type was added in 2006(1, 2). The prognosis is strongly correlated with the histological type. In this report, two cases of PPB were presented in order to discuss the clinical, histopathological, immunohistochemical features, and the differential diagnosis of the disease.

Case 1

A 3- year-old boy was admitted to the Emam Hossein children hospital of Isfahan, Iran, with cough and dyspnea in

2012. Physical examination revealed respiratory distress with decreased breath sounds in the left hemi thorax. Chest X-ray showed left sided mass associated with shift of heart and mediastinum to the right and increased interstitial marking of middle zone in left lung field (Fig 1-A). Chest computerized tomography (CT) scan revealed an irregular thick wall cystic lesion with nodular wall containing air fluid level in the left hemithorax without pleural effusion and invasion to the adjacent structures (with mild pressure on mediastinum and left main bronchus) (Fig 1-B). Hematological and biochemical measures were within normal limits. In past medical history, he had history of pneumothorax following rib fracture due

to a blunt trauma to the chest wall during playing in park seven months ago that chest tube was inserted for him and after several days he was discharged from hospital with good condition.

The patient underwent left thoracotomy, which demonstrated a multinodular relatively well defined mass, totally resected. The multinodular resected mass showed variegate appearance, totally 14x11x3 cm, fragments of thickened pleural tissue attached to some fragments, no area of cystic tissue was noted, on cut surface showed heterogeneous consistency some fragile. Microscopic slides revealed neoplastic proliferation of mesenchymal cells in loose connective tissue merging to fibrosarcoma like (Figure 2-A), area of large bizarre pleomorphic multinucleated cells as MFH and also nodules of benign appearing to malignant cartilage (Figure 2-B). Immunohistochemical staining blastemal cells showed positivity for vimentin and negativity for CD117. Diagnosis of pleuropulmonary blastoma type II was made and documents was sent to the International Pleuropulmonary Blastoma Registry, Minnesota, USA, for confirmation. CT scan of abdomen and brain were normal and bone scintigraphy revealed no abnormality.

Chemotherapy started with VAC regimen (vincristine 1.5 mg/m² on first day, actinomycin-D 0.015 mg/kg/day×5 on first day, and cyclophosphamide 2.2 g/m² on first day with mesna). Reevaluation of the patient after three months of chemotherapy by chest CT revealed no abnormality. The patient was asymptomatic for six months but he was admitted again with cough and dyspnea. Chest X-ray and CT scan showed a mass in left hemithorax and a core needle biopsy identified recurrence of PPB and typed as predominantly solid type II tumor (due to the presence of microcysts). Neoadjuvant chemotherapy including ifosfamide, vincristine, actinomycin-D, and doxorubicin (IVADo regimen) was scheduled for reducing the tumor size prior to surgical resection and

reevaluation of the patient after the three courses of treatment showed significant reduction in tumor size. The patient underwent second operation and due to adhesion to adjacent structures, mass partially excised. After then, he was given an additional 3 courses of IVADo regimen but unfortunately after 6 courses of treatment chest, CT scan showed increase in tumor size. He was candidate for radiotherapy. One month after the completion of the radiotherapy, the patient was referred to hospital with abdominal pain and dyspnea, thoracic CT revealed a huge lobulated solid/cystic mass in left hemithorax associated with shift to right side of heart and mediastinum and also lytic destructive and expansible lesion involved posterior arc of 4th rib. Abdominopelvic and brain CT scan were normal. The patient underwent third operation and the mass partially excised again and chemotherapy with topotecan and cyclophosphamide began and high dose consolidation therapy (HDCT) with autologous stem cell rescue (ASCR) was recommended but the patient died due to progressive disease before initiating new approach.

Case 2

A 26 - month-old boy was referred to the pediatric clinic of Emam Hossein hospital with fever and cough from 3 weeks ago that not responding to medical management, in 2013. Chest x- ray showed a massive right side pleural effusion. Family and past medical history was unremarkable. Chest tube was inserted and the fluid was drained. In last serial chest sonography, a large lower lobe heterogeneous mass (measuring 11× 9× 2cm) was revealed that was confirmed by chest CT scan. He underwent thoracotomy and the mass was excised totally. Pathology report showed PPB type II and adjuvant chemotherapy including ifosfamide, doxorubicin alternate with ifosfamide and etoposide (IDo/ IE) every three weeks for a total of 6 chemotherapy courses was scheduled. He was completed

courses of chemotherapy and was free of disease for 12 months. Next, follow up chest X-ray and CT revealed a new right lower chest mass (2× 1.5× 0.7 cm). The patient underwent second operation and tumor was removed. Pathology report

confirmed recurrence of PPB. He received 6 courses of ICE chemotherapy regimens (Ifosphamide 1800 mg/m² ×3days, Carboplatin 400 mg/m² ×2 days, Etoposide 100 mg/m² ×3days) and he felt better.

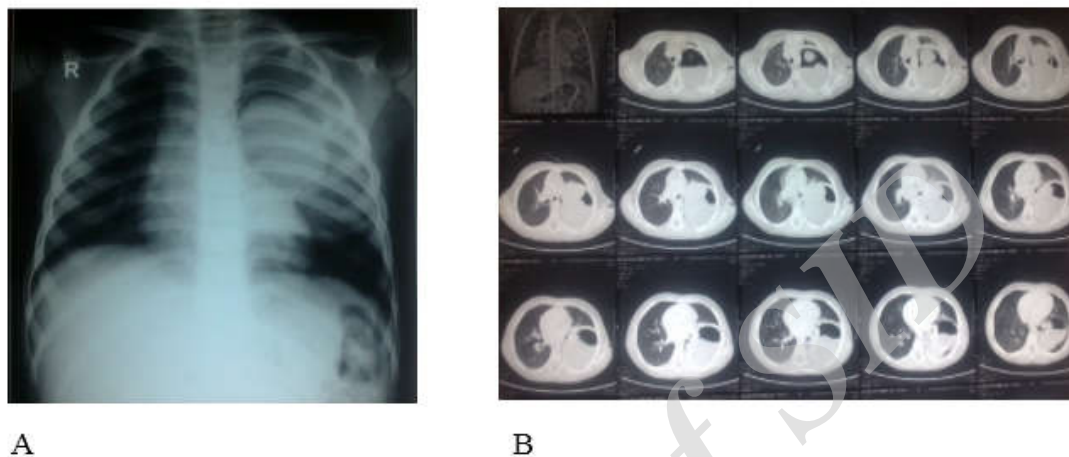


Figure 1.A: Chest X- ray, B: Chest CT scan

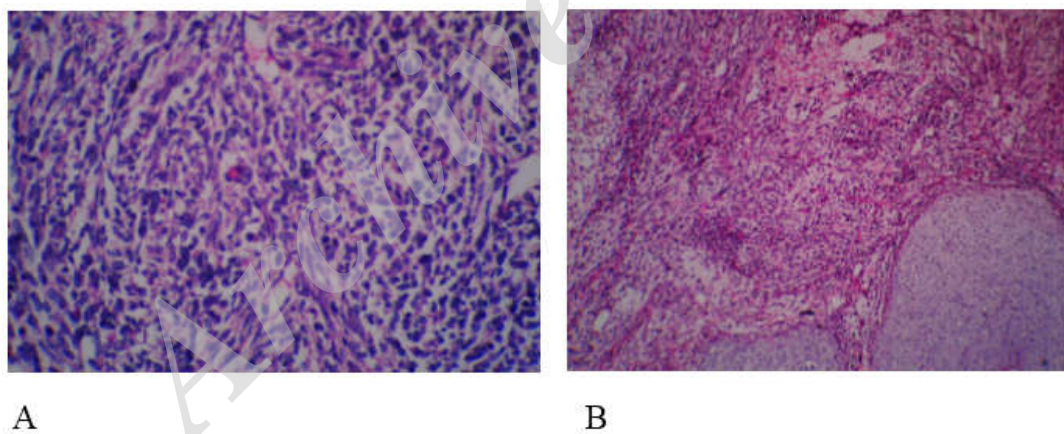


Figure 2. A: Blastematos foci consisting aggregates of primitive malignant cells (x400), B: Differentiated component of hyaline cartilage revealing relatively benign features as in this field (×100)

Discussion

Pleuropulmonary blastoma is a rare, malignant intrathoracic tumor that occurs mostly in children before five (4). At first, it was described by Manivel et al in 1988 as a distinctive neoplasm (1). It consists about 15% of all primary pediatric pulmonary tumors (3) and more commonly occurs on the right side. There is no gender predilection (4). In 25% of cases, it occurs in familial setting and can be associated with malignant and benign lesions in first and second-degree relatives (6).

PPB shows various mesenchymal components and may be presented with cartilaginous, rhabdomyoblastic or fibroblastic differentiation (7). Morphologically, it has three subtypes in children and a fourth type (Ir) was added in 2006(2). Type 1 (15%-20%) is exclusively cystic, type 2(40%) exhibit both cystic and solid components and type 3(40%) is a solid tumor without cystic spaces (3).Type Ir (type 1- regressed) is an abortive form of type I (2). Type 1 has the best prognosis whereas type 2 and type 3 behave aggressively. These three tumor types can progress over time from type 1 to type 3 (9). Immunohistochemical staining (IHC) has little diagnostic value in pleuropulmonary blastoma and diagnosis can be assessed with histopathology alone but IHC is supportive of the morphological diagnosis and can be helpful for differential diagnosis of other malignant tumors (6).

PPB occurs not only in lung but also it may arises from mediastinum, diaphragm or pleura (10). It's presentations are nonspecific and common symptoms include respiratory distress, fever, chest or upper abdominal pain, cough, anorexia, and pulmonary infection (4, 9). Neurological symptoms are seen in brain metastasis (4).Pneumothorax and pleural effusion are other symptoms (10). Common sites of metastasis in PPB include brain, bone, lymph node and liver (8).The prognosis is strongly correlated with the histopathological type,

mediastinal or pleural involvement, and the presence of metastasis (11).

Management of patients affected by PPB includes surgery, followed by chemotherapy, further surgery or radiotherapy if necessary (10).

Total resection of the tumor is the main treatment of disease (12) and majority of antineoplastic agents that have been used to treat PPB include protocols for rhabdomyosarcoma (13). Use of radiotherapy has not been agreed on PPB (14). For recurrent tumors, bone marrow transplant including high dose consolidation therapy (HDCT) with autologous stem cell rescue (ASCR) is recommended (2). In a study by Funda Çorapçioğlu et al., alternating ICE/VAC regiments was used (14). In another study by Guzin Gonullu et al., IE/VAC was also used (15). Funda Çorapçioğlu et al. followed the patient without administration of radiotherapy (14).

In conclusion, PPB is an invasive tumor with poor prognosis which is presented most often with features that mimic acute respiratory infection. PPB should be considered in the differential diagnosis of thoracic tumors in children. Main differential diagnoses are congenital cystic adenomatoid malformation, primitive neuroectodermal tumor, rhabdomyosarcoma, metastatic neuroblastoma, extrarenal rhabdoid tumor, desmoplastic small cell tumor, congenital infantile fibrosarcoma, and metastatic myxoid chondrosarcoma. Surgical excision with clear margins seems another choice of treatment for this tumor. Chemotherapy should be considered for these patients because in most patients, surgery is incomplete and chemo-reduction followed by complete resection may be another option of treatment in highly aggressive tumors.

Consent

Written informed consent was obtained from the patient's parents for publication

of these case reports and accompanying images.

Acknowledgment

We would like to thank the Research Center of Omid Hospital.

Conflicts of interest

The authors declare no conflicts of interest for this manuscript.

References

1. Manivel JC, Priest JR, Watterson J, Steiner M, Woods WG, Wick MR, Dehner LP. Pleuropulmonary blastoma the so-called pulmonary blastoma of childhood. *Cancer*. 1988; 62(8):1516-26.
2. The International Pleuropulmonary Blastoma Registry. [Cited 2015 09/12]. Available from: <http://www.ppbregistry.org/>.
3. Tomaszewski, JR. JF, Cagle PhT, Farver CF, Fraire AE. Dail and Hammar's Pulmonary Pathology: Volume II: Neoplastic Lung Disease. 3rd ed. New York, USA: Springer Science & Business Media; 2008.
4. Priest JR, McDermott MB, Bhatia S, Watterson J, Manivel JC, Dehner LP. Pleuropulmonary blastoma. A clinicopathologic study of 50 cases. *Cancer*. 1997 Jul 1; 80(1):147-61.
5. Khan AA, El-Borai AK, Alnoaiji M. Pleuropulmonary Blastoma: A Case Report and Review of the Literature. *Case Rep Pathol*. 2014; 2014:509086.
6. Parsons SK, Fishman JS, Hoorentji LE, Jaramillo L, Marcus KC, Perez-Atayde AR, et al. Aggressive multimodal treatment of pleuropulmonary blastoma. *Ann thorac surg*. 2001; 72(3): 939-942.
7. Pizzo P.A, Poplack D.G. Principles and practice of pediatric oncology. 6th ed. Philadelphia: Lippincott Williams & Wilkins; 2015.
8. Kelsey AM, McNally K, Brich J, Mitchell EL. Case of extra pulmonary, pleuro-pulmonary blastoma in a child: Pathological and cytogenetic findings. *Med Pediatr Oncol* 1997; 29(1): 61-64.

9. Romeo C, Impellizzeri P, Grosso M, Vitarelli E, Gentile C. Pleuropulmonary blastoma: long-term survival and literature review. *Med Pediatr Oncol*. 1999; 33(4): 372-376.

10. Bisogno G, Brennan B, Orbach D, Stachowicz-Stencel T, Cecchetto G, Indolfi P, Bien E, Ferrari A, Dommange-Romero F. Treatment and prognostic factors in pleuropulmonary blastoma: an EXPeRT report. *Eur J Cancer*. 2014 Jan; 50(1):178-84.

11. de Castro CG Jr, de Almeida SG, Gregianin LJ, Loss JF, Rivero LF, Schwartzmann G, Brunetto AL. High-dose chemotherapy and autologous peripheral blood stem cell rescue in a patient with pleuropulmonary blastoma. *J Pediatr Hematol Oncol*. 2003 Jan; 25(1):78-81.

12. Indolfi P, Bisogno G, Casale F, Cecchetto G, De Salvo G, Ferrari A, Donfrancesco A, Donofrio V, Martone A, Di Martino M, Di Tullio MT. Prognostic factors in pleuro-pulmonary blastoma. *Pediatr Blood Cancer*. 2007 Mar; 48(3):318-23.

13. Carli M, Colombatti R, Oberlin O, Bisogno G, Treuner J, Koscielniak E, Tridello G, Garaventa A, Pinkerton R, Stevens M. European intergroup studies (MMT4-89 and MMT4-91) on childhood metastatic rhabdomyosarcoma: final results and analysis of prognostic factors. *J Clin Oncol*. 2004 Dec 1; 22(23):4787-94.

14. Corapcioglu F, Liman T, Aksu G, Topcu S. A case report with type II pleuropulmonary blastoma: successful treatment with surgery and chemotherapy. *Turkish Journal of Pediatrics*. 2009; 51(1): 78-81.

15. Gonullu G, Evernsel T, Kurt E, Aydin S, Bayram S, Aydin F, Yilmazbayhan D, Manavoglu O. Pleuropulmonary blastoma in an adult patient: Report of a case. *Turkish Journal of Cancer*. 2007; 37(4):158-161.