

The Correlation of Ovarian Masses and Risk of Oophorectomy in Pediatric Patients

Imen Abid MD ¹, Mohamed Zouari MD ^{1,*}, Mohamed Jallouli MD ¹, Sondes Sahli MD ², Aicha Bouden MD ², Rabiaa Ben Abdallah MD ³, Fatma Trabelsi MD ³, Asma Jabloun MD ³, Awatef Charieg MD ⁴, Chaima Mrad MD ⁴, Mariam Marzouki MD ⁴, Sana Mosbahi MD ⁴, Aziza Ezzi MD ⁴, Roumayla Mootamri MD ⁵, Mourad Hamzaoui MD ², Nejib Kaabar MD ³, Said Jlidi MD ⁵, Abdellatif Nouri MD ⁵, Riadh Mhiri MD ¹

1. Department of pediatric surgery, Hedi-Chaker Hospital, Sfax, Tunisia
2. Department of pediatric surgery "A", Children Hospital, Tunis, Tunisia
3. Department of pediatric surgery, Habib-Thameur Hospital, Tunis, Tunisia
4. Department of pediatric surgery "B", Children Hospital, Tunis, Tunisia
5. Department of pediatric surgery, Fattouma-Bourguiba Hospital, Monastir, Tunisia

*Corresponding author: Dr. Mohamed Zouari, Address for correspondence: Department of Pediatric Surgery. Hedi Chaker Hospital. 3029 Sfax. Tunisia. E-mail: zouarimohamed.1982@yahoo.fr

Received: 25 March 2017

Accepted: 27 April 2017

Abstract

Background: Ovarian masses requiring surgical intervention are uncommon in the pediatric population. The aim of this study was to report results of a multicentric Tunisian study concerning the clinical practice and the management of pediatric ovarian masses and to identify the factors that are associated with ovarian preservation.

Materials and Methods: Between January 2000 and December 2015, 98 pediatric patients (<14 years) were surgically treated for ovarian masses at the five pediatric surgery departments in Tunisia.

Results: Ninety-eight patients were included in this study. The mean age of the patients at time of surgery was 8.46 ± 4.87 years. Sixty-three ovarian masses (64.3%) were non-neoplastic lesions, 24 (24.5%) were benign tumors, and 11 (11.2%) were malignant neoplasms. Conservative surgery (ovarian preserving surgery) was successfully performed in 72.4% of the benign lesions whereas only three patients (27.3%) with malignant tumors underwent ovary-sparing tumor resection ($p < 0.001$). The mean diameter of the tumors in the patients who underwent oophorectomy was significantly larger than that in the patients who underwent conservative surgery (7.8 ± 3.9 cm vs. 5.7 ± 2.9 cm, respectively, $p = 0.001$).

Conclusion: In the present study, the risk factors for oophorectomy were a malignant pathology and large tumor size. In accordance with the Gynecologic Cancer Intergroup consensus, it is recommended that surgical management of ovarian masses in children should be based on ovarian preserving surgery.

Key words: Children, Oophorectomy, Ovarian Mass, Ovarian Preservation

Introduction

Ovarian masses requiring surgical intervention are uncommon in the pediatric population (1). The estimated incidence of ovarian neoplasms in childhood is 2.6 cases per 100,000 girls per year, and malignant ovarian tumors account for approximately 1% of all pediatric malignancies (2). The presence of an ovarian mass in children is a diagnostic and therapeutic challenge. The signs and symptoms can mimic many abdominopelvic medical or surgical diseases (3). Most ovarian masses in

children are functional cysts or benign tumors; however, thorough investigation is nevertheless called for to rule out malignancy (4). The aim of this study was to report results of a multicentric Tunisian study concerning the clinical practice and the management of pediatric ovarian masses and to identify the factors that are associated with ovarian preservation.

Materials and Methods

Between January 2000 and December 2015, 98 pediatric patients (<14 years) were surgically treated for ovarian masses

at the five pediatric surgery departments in Tunisia. The study was carried out in accordance with the Declaration of Helsinki of the World Medical Association and was approved by the Committees of Medical Ethics at all collaborating institutions (HCH00001741). The pathology databases at the Children's Hospital (Tunis), Habib Thameur Hospital (Tunis), Fattouma Bourguiba Hospital (Monastir), and Hedi Chaker Hospital (Sfax) were used to identify all patients who had ovarian tissue submitted during the study period. From this search, 106 patients were identified. Eight patients had incomplete records and were thus not evaluable. Inclusion required that study subjects have complete medical records, with operative reports, and pathologically evaluated tissue samples.

After reviewing the pathology reports, the medical records of these patients were reviewed retrospectively. Specific data collected on each patient included the age at operation, presenting symptoms and signs, the levels of beta human chorionic gonadotropin (β HCG) and alpha-fetoprotein (α FP), and the results of ultrasound scans, computed tomography (CT) scans and Magnetic resonance imaging (MRI) scans. All operative reports were reviewed; the size of all masses was collected as documented at surgery or in the pathology record.

Statistical analysis was performed using SPSS, version 20.0. The χ^2 test was used to compare the proportions of the groups, while the unpaired Student's t-test was performed to compare the variables of the patient groups. P values <0.05 were considered to be statistically significant.

Results

Ninety-eight patients were included in this study. The mean age of the patients at time of surgery was 8.46 ± 4.87 years. Figure 1 shows the distribution of patients according to age. Sixty-two patients (63.3%) were pre menarche while 36 (36.7%) were post menarche. The primary

presenting symptoms and signs that led to a visit to the doctor included abdominal pain (72.4%), abdominal/pelvic mass (9.2%), and precocious puberty (3.1%). Fourteen patients (14.3%) had a cystic abdominal mass detected on prenatal ultrasound scan. Ultrasonography was performed in 92 (93.9%) patients to define the size of the lesion and the gross morphologic nature of the tumor. Only 22 (22.4%) patients had abdominal computed tomography scans, and nine patients (9.2%) had MRI scans. Tests for serum tumor markers including α FP and β HCG were performed in 53 cases and 48 cases, respectively. No patients with nontumorous masses had abnormal serum α FP or β HCG levels. One patient with benign tumor had a markedly elevated α FP level. Among patients with malignant tumors, 54.5% had abnormal α FP levels and 27.2% had abnormal β HCG levels.

Thirty-five (35.7%) patients underwent emergent surgery owing to the suspicion of ovarian torsion. The other patients underwent elective surgery. Sixty-three ovarian masses (64.3%) were non-neoplastic lesions, 24 (24.5%) were benign tumors, and 11 (11.2%) were malignant neoplasms (Table I). There was no difference in the age of presentation between patients who had benign neoplasms (8.52 ± 5.1 years) and those who had malignant tumors (8.09 ± 2.8 years; $p=0.325$). However, there was a significant difference in tumor size between patients who had benign neoplasms (5.61 ± 2.5 cm) and those with malignant tumors (11.45 ± 4.6 cm; $p<0.001$).

Patients underwent a range of procedures including salpingo-oophorectomy ($n=13$), ovarian cystectomy ($n=59$), tumorectomy ($n=12$), oophorectomy ($n=13$). One patient with metastatic ovarian neuroblastoma underwent a total abdominal hysterectomy and bilateral salpingo-oophorectomy. Oophorectomy or salpingo-oophorectomy was performed in 24 (27.6%) patients with a benign mass and in eight (72.7%) patients with a malignant mass ($p<0.001$).

A laparoscopic resection was performed in 26 patients (26.5%), laparoscopic converted to open occurred in nine patients (9.2%) and open procedure in 65 (66.3%). No malignant mass was removed with laparoscopy. The histopathological examinations showed 35 ovarian tumors including 18 cases of mature teratoma, five cases of cystadenoma, five cases of juvenile granulosa cell tumor, two cases of dysgerminoma, two cases of immature teratoma (grade 3), one case of Yolk sac tumor, one case of borderline cystadenoma and one case of metastatic tumors (Nephroblastoma).

Conservative surgery (ovarian preserving surgery) was successfully performed in 72.4% of the benign lesions whereas only three patients (27.3%) with malignant tumors underwent ovary-sparing tumor resection ($P < 0.001$). The median tumor size (based on largest diameter) was 6 cm (range: 1-20 cm). The mean diameter of

the tumors in the patients who underwent oophorectomy was significantly larger than that in the patients who underwent conservative surgery (7.8 ± 3.9 cm vs. 5.7 ± 2.9 cm, respectively, $p = 0.001$).

Overall, there were 26 patients who had ovarian torsion. Twenty-one of 26 ovarian torsions were managed conservatively, while oophorectomy was reserved for five non-resectable tumors. There was no significant association between torsion and oophorectomy ($p = 0.268$).

Three cases of malignant tumors received postoperative chemotherapy.

One patient with a dysgerminoma and another patient with an immature teratoma exhibited recurrence 3 years after surgery; however, the recurrent tumors were completely resected with ovary-sparing tumor resection and the patients achieved a second remission. All girls were alive and disease-free after a median follow-up of 96 months (range 16-198 months).

Table I: Pathologic findings for 98 patients undergoing surgery for an adnexal mass.

Pathologic diagnosis	number	% of total
Non-neoplastic lesions	63	64.3
Simple ovarian cyst	53	54.1
Corpus luteal cyst	5	5.1
Follicular cyst	5	5.1
Benign neoplasms	24	24.5
Mature teratoma	18	18.4
Cystadenoma	5	5.1
Borderline cystadenoma	1	1
Malignant neoplasms	11	11.2
Juvenile granulosa cell tumor	5	5.1
Dysgerminoma	2	2
Immature teratoma	2	2
Yolk sac tumor	1	1
Metastatic tumors (Nephroblastoma)	1	1

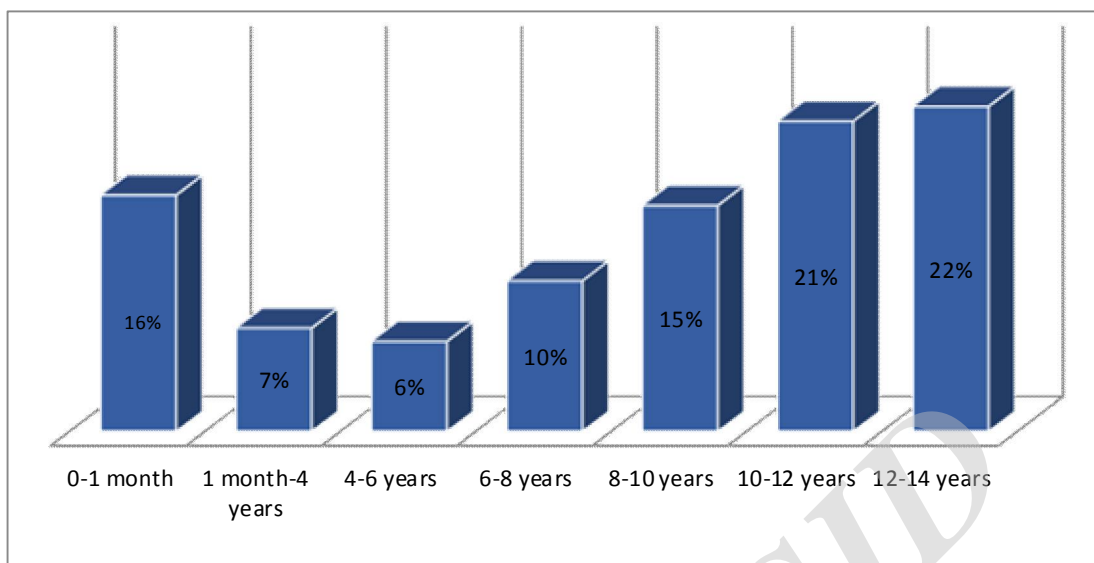


Figure 1. Distribution of patients according to age

Discussion

Ovarian masses are rare in childhood. Amongst pediatric patients undergoing surgery for ovarian masses, the incidence of malignancy ranges from 4%-20%, accounting for 1% of all pediatric cancers (5-8). Symptoms that may be linked to the diagnosis of ovarian lesions are varied and not specific, including acute abdominal pain, mass effect, and precocious puberty (4). Ultrasound (US) scan is the gold standard for the diagnosis of ovarian masses (9, 10). On ultrasound, malignant tumors appear as complex soft tissue masses with ill-defined irregular borders and central necrosis, septations, and papillary projections (10). In elective situations, a CT scan or MRI analysis should be performed to improve adnexal mass characterization and localization (4, 11). Pelvic MRI is especially helpful in correctly suggesting a benign nature in adnexal masses, especially in indeterminate ultrasound cases (12).

In the present case series, α FP was raised in 7 cases and 6 turned out to have malignant tumors. Papic et al., (2014), in their retrospective analysis of 150 girls

with an ovarian mass managed operatively, found that α FP and β HCG were highly associated with malignancy, no benign masses were positive for these markers in this study(13). However, other reports showed that the rate of benign lesions associated with the rise of tumor markers varies from 3.4% to 20.7% (2, 7, 14-19). Additionally, certain malignant masses such as pure germinomas may not demonstrate any elevated tumor markers (20, 21).

Ovarian masses in pediatric patients could be managed by either laparotomy or laparoscopy, similarly to those in adult women (1, 22). If there is a surgical indication, surgery must conform to oncologic standards and must be as conservative as possible to preserve future fertility (1, 4, 13, 23, and 24). In the present study, the oophorectomy rate was higher in patients with a tumor size >6 cm and the tumor size was significantly larger in the patients who underwent oophorectomy than in those who underwent ovarian preserving surgery. Chabaud-Williamson et al., (2011) mentioned the importance of size of

ovarian tumors (25). They reported that it is easier to find a dissection plane between the native ovary and the teratoma in patients with ovarian teratomas of less than 8 cm in size. Therefore, they suggested that ovary-sparing surgery should be attempted whenever possible for ovarian tumors which meet all criteria for localized mature teratoma. According to the report of Ozcan et al., (2013), ovary-sparing surgery can be safely performed in acute cases and incidental ovarian teratomas (26). In their experience, they did not experience any malignant development. Therefore, they recommended ovary-sparing surgery as the first-line treatment for pediatric ovarian teratomas (26).

Germ cell tumors were the most common malignant ovarian tumor in this cohort of patients, comprising 45.5% of all tumors. This result is in accordance with the literature data (27). Because of this different histological distribution, the overall prognosis of ovarian cancer in children is excellent compared with that in adults (28-30). Since most tumors are unilateral and diagnosed as stage I disease, fertility-sparing surgery appears to be safe (31). In case of FIGO (International Federation of Gynecology and Obstetrics) stage II disease or higher, surgery has to be extended, keeping in mind that the uterus usually can be preserved in case of a bilateral tumor (31). The long-term risk of metachronous contralateral or ipsilateral recurrences requires annual ultrasound monitoring for many years after ovary-sparing surgery or oophorectomy (25).

In the present case series, ovarian torsion occurred in 26 cases (26.5%). None of these cases was associated with ovarian malignancy. Ovarian torsion is a rare problem that must be considered in the differential diagnosis of any pediatric female patient presenting with abdominal pain or a pelvic or abdominal mass. Conservative treatment for ovarian torsion consists in detorsion at first, and if an ovarian mass is associated, simultaneous

or following enucleation of the lesion is recommended (7, 32, 33). In cases of ovarian torsion, ovarian conservation was accomplished in 80.8% of patients. There was no significant association between torsion and oophorectomy ($p=0.268$). In accordance with these findings, current recommendations advocate ovarian preserving surgery, regardless of how ischemic or necrotic the ovary appears intra-operatively (1, 7, 33-36).

Conclusion

In the present study, the risk factors for oophorectomy were a malignant pathology and large tumor size. In accordance with the Gynecologic Cancer Intergroup consensus, it is recommended that surgical management of ovarian masses in children should be based on ovarian preserving surgery. Long-term follow-up is needed to fully assess the effects of ovary conserving surgery on future fertility and ovarian function in this population.

Conflict of interest

The authors declare that there is no conflict of interest.

References

1. Eskander RN, Bristow RE, Saenz NC, Saenz CC. A retrospective review of the effect of surgeon specialty on the management of 190 benign and malignant pediatric and adolescent adnexal masses. *J Pediatr Adolesc Gynecol* 2011; 24(5):282-5.
2. Al Jama FE, Al Ghamdi AA, Gasim T, Al Dakheel SA, Rahman J, Rahman MS. Ovarian tumors in children and adolescents-a clinical study of 52 patients in a university hospital. *J Pediatr Adolesc Gynecol* 2011; 24(1):25-8.
3. Oue T, Uehara S, Sasaki T, Nose S, Saka R, Yamanaka H, Ueno T, Tazuke Y, Okuyama H. Treatment and ovarian preservation in children with ovarian tumors. *J Pediatr Surg* 2015; 50(12):2116-8.

4. Cartault A, Caula-Legriél S, Baunin C, Le Mandat A, Lemasson F, Galinier P, Pienkowski C. Ovarian masses in adolescent girls. *Endocr Dev* 2012; 22:194-207.
5. Quint E, Smith Y. Ovarian surgery in premenarchal girls. *J Pediatr Adolesc Gynecol* 1999; 12: 27-9.
6. Kirkham YA, Lacy JA, Kives S, Allen L. Characteristics and management of adnexal masses in a Canadian pediatric and adolescent populations. *J Obstet Gynaecol Can* 2011; 33:935-943.
7. Oltmann SC, Garcia N, Barber R, Huang R, Hicks B, Fischer A. Can we preoperatively risk stratify ovarian masses for malignancy? *J Pediatr Surg* 2010; 45:130-4.
8. von Allmen D. Malignant lesions of the ovary in childhood. *Semin Pediatr Surg* 2005; 14:100-5
9. Servaes S, Victoria T, Lovrenski J, Epelman M. Contemporary pediatric gynecologic imaging. *Semin Ultrasound CT MR* 2010; 31:116.
10. Liu H, Wang X, Lu D, Liu Z, Shi G. Ovarian masses in children and adolescents in China: analysis of 203 cases. *J Ovarian Res* 2013; 6:47.
11. Anthony EY, Caserta MP, Singh J, Chen MY. Adnexal masses in female pediatric patients. *AJR Am J Roentgenol* 2012; 198(5):W426-31.
12. Marro A, Allen LM, Kives SL, Moineddin R, Chavhan GB. Simulated impact of pelvic MRI in treatment planning for pediatric adnexal masses. *Pediatr Radiol* 2016; 46(9):1249-57.
13. Papic JC, Finnell SM, Slaven JE, Billmire DF, Rescorla FJ, Leys CM. Predictors of ovarian malignancy in children: overcoming clinical barriers of ovarian preservation. *J Pediatr Surg* 2014; 49(1):144-7; discussion 147-8.
14. Spinelli C, Pucci V, Buti I, Liserre J, Messineo A, Bianco F, Ugolini C. The role of tumor markers in the surgical approach of ovarian masses in pediatric age: a 10-year study and a literature review. *Ann Surg Oncol* 2012; 19:1766-73.
15. Morowitz M, Huff D, von Allmen D. Epithelial ovarian tumors in children: a retrospective analysis. *J Pediatr Surg* 2003; 38(3):331-335; discussion 5.
16. Rousseau V, Massicot R, Darwish AA, Sauvat F, Emond S, Thibaud E, Nihoul-Fékété C. Emergency management and conservative surgery of ovarian torsion in children: a report of 40 cases. *J Pediatr Adolesc Gynecol* 2008;21(4):201-206.
17. Ruttenstock EM, Saxena AK, Schwinger W, Sorantin E, Hoellwarth ME. Pediatric ovarian tumors—dilemmas in diagnosis and management. *Eur J Pediatr Surg* 2010; 20(2):116-120.
18. Aggarwal A, Lucco KL, Lacy J, Kives S, Gerstle JT, Allen L. Ovarian epithelial tumors of lowmalignant potential: a case series of 5 adolescent patients. *J Pediatr Surg* 2009; 44(10):2023-2027.
19. Stankovic Z, Djuricic S, Djukic M, Jovanovic D, Vasiljevic M. Epithelial ovarian tumors and CA125 in premenarchal girls. *Eur J Gynaecol Oncol* 2006; 27(6):597-599.
20. Göbel U, Schneider DT, Calaminus G, Haas RJ, Schmidt P, Harms D. Germ-cell tumors in childhood and adolescence. GPOH MAKEI and the MAHO study groups. *Ann Oncol* 2000; 11:263-71.
21. Stankovic ZB, Djukic MK, Savic D, Lukac BJ, Djuricic S, Sedlecki K, Zdravkovic D. Pre-operative differentiation of pediatric ovarian tumors: morphological scoring system and tumor markers. *J Pediatr Endocrinol* 2006; 19:1231-8.
22. Berger-Chen S, Herzog TJ, Lewin SN, Burke WM, Neugut AI, Hershman DL, Wright JD. Access to conservative surgical therapy for adolescents with benign ovarian masses. *Obstet Gynecol* 2012; 119:270-5.
23. Baert T, Storme N, Van Nieuwenhuysen E, Uyttebroeck A, Van Damme N, Vergote I, Coosemans A. Ovarian cancer in children and adolescents: A rare disease that needs more attention. *Maturitas*.2016; 88:3-8.

24. Takeda A, Imoto S, Nakamura H. Management of pediatric and adolescent adnexal masses by gasless laparoendoscopic single-site surgery. *Eur J Obstet Gynecol Reprod Biol* 2014; 181:66-71.
25. Chabaud-Williamson M, Netchine I, Fasola S, Larroquet M, Lenoir M, Patte C, Bénifla JL, Coulomb-L'herminé A, Grapin C, Audry G, Auber F. Ovarian-sparing surgery for ovarian teratoma in children. *Pediatr Blood Cancer* 2011; 57(3):429-34.
26. Özcan R, Kuruoğlu S, Dervişoğlu S, Eliçevik M, Emir H, Büyükcinal C. Ovary-sparing surgery for teratomas in children. *Pediatr Surg Int* 2013; 29(3):233-7.
27. Prat J. Pathology of cancers of the female genital tract. *Int J Gynaecol Obstet* 2015; 131 Suppl 2:S132-45.
28. Van Nieuwenhuysen E, Lambrechts S, Lambrechts D, Leunen K, Amant F, Vergote I. Genetic changes in nonepithelial ovarian cancer. *Expert Rev Anticancer Ther* 2013;13(7):871-82.
29. Andrés MM, Costa E, Cañete A, Moreno L, Castel V. Solid ovarian tumours in childhood: a 35-year review in a single institution. *Clin Transl Oncol* 2010; 12(4): 287-91.
30. Mangili G, Sigismondi C, Gadducci A, Cormio G, Scollo P, Tateo S, Ferrandina G, Greggi S, Candiani M, Lorusso D. Outcome and risk factors for recurrence in malignant ovarian germ cell tumors: a MITO-9 retrospective study. *Int J Gynecol Cancer* 2011; 21(8): 1414-21.
31. Ray-Coquard I, Brown J, Harter P, Provencher DM, Fong PC, Maenpaa J, Ledermann JA, Emons G, Rigaud DB, Glasspool RM, Mezzanzanica D, Colombo N. Gynecologic Cancer InterGroup (GCIG) consensus review for ovarian sex cord stromal tumors. *Int J Gynecol Cancer* 2014; 24(9 Suppl 3): S42-7.
32. Huchon C, Fauconnier A. Adnexal torsion: a literature review. *Eur J Obstet Gynecol Reprod Biol* 2010; 150(1):8-12.
33. Galinier P, Carfagna L, Delsol M, Ballouhey Q, Lemasson F, Le Mandat A, Moscovici J, Guitard J, Pienkowski C, Vaysse P. Ovarian torsion. Management and ovarian prognosis: a report of 45 cases. *J Pediatr Surg* 2009; 44:1759-65.
34. Tsafirir Z, Azem F, Hasson J, Solomon E, Almog B, Nagar H, Lessing JB, Levin I. Risk factors, symptoms, and treatment of ovarian torsion in children: the twelve-year experience of one center. *J Minim Invasive Gynecol* 2012; 19:29-33.
35. Geimanaite L, Trainavicius K. Ovarian torsion in children: management and outcomes. *J Pediatr Surg* 2013; 48:1946-53.
36. Bertozzi M, Riccioni S, Valoncelli C, Appignani A. The Diagnosis and Management of Ovarian Cysts in Children. *J Pediatr Adolesc Gynecol* 2017; 30(2): 265.