

## Glioblastoma Multiforme in a nine-year-old girl: a case report

Hossein Esfahani MD<sup>1,\*</sup>, Arash Dehghan MD<sup>1</sup>, Ghazal Sami MD<sup>1</sup>, Nika Eskandari MD<sup>1</sup>

1. Besat Hospital, Hamadan university of medical sciences, Hamedan, Iran.

\*Corresponding author: Dr Hossein Esfahani, MD, Besat Hospital, Hamadan university of medical sciences, Hamedan, Iran.  
E-mail: hesfehani@yahoo.com.

Received: 06 September 2016

Accepted: 22 February 2019

### Abstract

Brain tumors are the most common solid tumors in childhood. Glioblastoma multiform (GBM) is the second most common primary brain tumor in adults. It usually affects the cerebral hemispheres of adults at the 6th or 7th decade of life. In comparison to adult population, GBM is rare in pediatrics and accounts for approximately 3% of all pediatric brain tumors. Pediatric glioblastoma was defined as patient age younger than 21 years at the time of craniotomy. The prognosis seems to be better in childhood. This report documented a GBM was located in the frontal lobe of a 9 year old girl who was diagnosed in Hamedan University of Medical Sciences in 2016. Magnetic resonance imaging (MRI) showed a huge well enhancing mass in left frontal lobe (47 ×35 mm ). This mass was surrounded by vasogenic edema and was extended to medial aspect of right frontal lobe through corpus callosum. The patient underwent a left frontal craniotomy, and gross total tumor removal was performed. Pathology findings revealed neoplastic transformation of glial cells associated with vascular necrosis and neovascularization.

**Key words:** Brain neoplasm, Craniotomy, Glioblastoma, Pediatric

### Introduction

Glioma is a tumor that arises from glial or supportive tissue of the brain. Astrocytoma is one kind of glioma. Sometimes these two terms "glioma" and "astrocytoma" are used interchangeably (1). The World Health Organization (2007) grading system designed three lesions of diffusely infiltrating astrocytic tumors, including diffuse astrocytoma (grade II), anaplastic astrocytoma (grade III), and glioblastoma multiform (grade IV) (2). Glioblastoma multiform (GBM) is a high-grade glioma that is difficult to treat in children. High-grade gliomas (HGGs) account for 3% to 7% of primary brain tumors in children. GBM includes low differentiated cells with high mitotic activity. Common sites for glioblastoma in children are the cerebellum, cerebral hemispheres, and the thalamus or hypothalamus (1-3). As expected, survival rates are poor in patients with HGGs, but recent data support aggressive surgical resection when it is feasible. Here, we presented a rare

occurrence of glioblastoma in frontal lobe of a 9-year-old girl and discuss magnetic resonance imaging and histopathologic findings (4).

### Case report

A 9-year-old girl was presented with a 12-month history of occasionally headache. She complained of last month progressive headache with nausea and vomiting. She had no history of head trauma, previous hospitalization, specific drug use, or familial disease. Her neurologic examination was normal. Papilledema was found in eye examination that was caused by increased intracranial pressure. A complete blood cell count indicated an overall increase in the number of WBCs. The magnetic resonance imaging (MRI) showed pituitary gland with normal size and signal intensity. There was no detectable mass, abnormal signal intensity, or contrast enhancement in infratentorial areas. The MRI showed a huge well

enhancing mass in left frontal lobe ( 47 ×35 mm ). This mass was surrounded by vasogenic edema that and expanded to medial aspect of right frontal lobe through corpus callosum. There was mild edema in floor of left temporal lobe without associated contrast enhancement (Figure1). The patient underwent a left frontal craniotomy for surgical resection of the mass, and gross total tumor removal was performed. Histopathologic findings showed a neoplastic transformation of glial cells, which was associated with vascular neof ormation, and necrosis with nuclear palisading. Neoplastic astrocyte cells with hyperchromatic and pleomorphic nuclei that had atypia and mitotic figures were found by microscopic examination (Figure2). These findings and the presence of necrosis, confirmed the diagnosis of glioblastoma multiforme. The patient was died before the start of treatment.

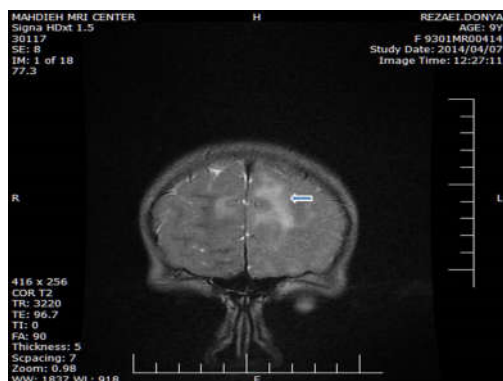

Figure1. Pre-operative magnetic resonance imaging (MRI) reveals a huge well enhancing mass in left frontal lobe (47 × 35 mm).

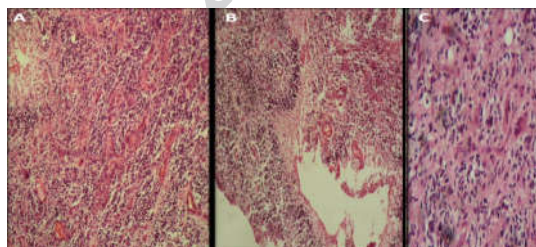


Figure2. Hematoxylin and Eosin staining revealed of biopsy, revealed Glioblastoma multiforme with typical endothelial proliferation (A), high mitotic rate (B), and necrosis (C).

## Discussion

Pediatric high-grade gliomas (HGGs) include Anaplastic astrocytoma (AA), anaplastic oligodendrogliomas, and GBM. Malignant gliomas are rare in children. There are variety of signs and symptoms in children with HHGs that mainly depend on their age and the tumor site. If tumors be close to the cerebral cortex, we may see seizures as the pioneer of the onset. Other common clinical manifestations comprise headache, hemiparesis, visual problems, nausea, vomiting, ataxia, gait disturbance, and vertigo. In addition, signs of intracranial hypertension may be found in some cases due to an obstruction of the cerebro-spinal fluid (CSF) pathways. Neurological impairments are characteristically quick and may range from days to months. The average duration of symptoms in supratentorial glioblastoma is 8.5 weeks (1, 2). Brain tumors cannot be prevented. The causes of these tumors are unknown .Maybe some abnormalities in the genes of different chromosomes are effective in the development of tumors (4, 5). Glioblastoma is often associated with an amplification of the epidermal growth factor receptor (EGFR) gene and deletion of the phosphate and tensin homolog (PTEN) gene. In contrast, pediatric glioblastoma more often demonstrates p53 alterations and rarely exhibits EGFR amplification or PTEN deletion (3-6). Although these gliomas may occur in any anatomical site within the central nervous system, the majority of these tumors have been supratentorial, including frontal, parietal and temporal. GBM is the most common primary brain tumor in the adult population, but GBMs along with AAs account for 20% of pediatric supratentorial brain tumors (2, 3). Even in the best condition and under best treatment (surgery and adjuvant therapy), the estimated survival rate is about 6 to 16 months (7). The pathogeny and prognosis of cerebellar glioblastomas are not completely elucidated because of their

scarcity. Based on the clinical and genetic data, there are two subsets of GBM. The secondary glioblastoma usually happens in younger people and it is related to TP 53 mutation (65%) but the primary type often affects elderly people and it is characterized by heterozygosity 10 q (70%) (8). In the present case, the first clinical manifestation was severe headaches following by nausea and vomiting. On MRI with contrast, high grade gliomas showed a huge well enhancing mass; low grade gliomas frequently do not enhance with contrast, or slightly enhance (5,9). However, only the examination of tumors specimen under a microscope can confirm the exact diagnosis (6-10). Histopathologic findings showed a neoplastic tissue with mitotic activity, endothelial proliferation, high cellularity, nuclear pleomorphism, and necrosis in this study. These pathologic features confirmed GBM. The treatment of malignant gliomas is still a challenge, particularly in children. Chemotherapy and radiotherapy, far from being satisfactory treatment options, are associated with a significant rate of morbidity. Children older than 3 years with supratentorial neoplasms undergo multiple procedures such as surgical resection, radiation therapy and chemotherapy which promote the length of survival but do not seem to be useful to change the inexorable course of the disease (4-11).

### Conclusion

In conclusion glioblastoma multiforme is a rare brain tumor in childhood. It has a better prognosis than glioblastoma in adults. Complete resection is the most significant prognostic factor in these patients. Further study is needed to help improve the quality of life and prognosis in children with glioblastoma multiforme.

### Acknowledgements

The authors gratefully thank the members of pathology and hematology/oncology

department of Besat Hospital for their help in reporting this case.

### Conflicts of interest

The authors declare no conflict of interest.

### References

1. Cage TA, Mueller S, Haas-Kogan D, Gupta N. High-Grade Gliomas in Children. *Neurosurg Clin N Am* 2012;23(3):515-523.
2. Louis D, Ohgaki H, Wiestler O, Cavenee W, C. Burger P, Jouve A. The 2007 WHO Classification of Tumours of the Central Nervous System. *Acta Neuropathol* 2007; 114(2): 97-109.
3. Perkins SM, Rubin JB, Leonard JR, Smyth MD, El Naqa I, Michalski JM. Glioblastoma in children: a single-institution experience. *Int J Radiat Oncol Biol Phys* 2011; 80(4):1117-21.
4. Borgo MC, Pereira JL, Lima FB, Brandão RA, Carvalho GT, Costa BS. Glioblastoma multiforme in childhood: a case report. *Clinics* 2010;65(9):923-5.
5. Tamber MS, Rutka JT. Pediatric supratentorial high-grade gliomas. *Neurosurg Focus* 2003;14(2):e1.
6. Mahvash M, Hugo HH, Maslehaty H, Mehdorn HM, Stark AM. Glioblastoma Multiforme in Children: Report of 13 Cases and Review of the Literature. *Pediatr Neurol* 2011; 45(3):178-80.
7. Morais N, Mascarenhas L, Soares-Fernandes J P, Silva A, Magalhães Z, Moreira A. Primary spinal glioblastoma: A case report and review of the literature. *Oncol Lett* 2013; 5(3):992-996.
8. El Maaqili MR, Hossini A, El Fatemi N, Gana R, Saïdi A, Jiddane M. Primary glioblastoma of the cerebellum in a 19-year-old woman: a case report. *J Med Case Rep* 2012; 329(6):1-5.
9. Broniscer A, Gajjar A. Supratentorial high-grade astrocytoma and diffuse brainstem glioma: two challenges for the pediatric oncologist. *Oncologist* 2004; 9(2):197-206.

10. Pollack IF. Brain Tumors in Children. *N Engl J Med* 1994; 331:1500-1507.
11. Winters JL, Wilson D, Davis DG. Congenital glioblastoma multiforme: a report of three cases and a review of the literature. *J Neurol Sci* 2001; 188(2):13-9.

Archive of SID