

TOXIC EFFECTS OF HYDROALCOHOLIC EXTRACT OF KIWI (*ACTINIDIA CHINENSIS*) ON HISTOLOGICAL STRUCTURE OF THE MALE SPRAGUE-DAWLEY RAT REPRODUCTIVE TISSUES*

F. DEGHANI¹, T. TALAEI-KHOZANI^{1**}, M. R. PANJEHSHAHIN² AND Z. PANAHI³

¹Department of Anatomy, Medical School, Shiraz Medical Sciences University, Shiraz, I. R. of Iran

²Medical and Natural Products Chemistry Research Center, Shiraz Medical Sciences University, Shiraz, I. R. of Iran

³Shiraz Medical Sciences University, Shiraz, I. R. of Iran
Email: talaeit@sums.ac.ir

Abstract – Hormonally active agents are widespread in the environment and exist in the human diet. There is insufficient knowledge regarding the influence of phytochemicals on the pathophysiology of the male reproductive system. Kiwi is a rich source of phytochemicals such as flavones (with estrogenic activity), serotonin and vitamin C. These components can influence the hormones and interfere with reproductive activities. Therefore, the objective of this project was to determine whether extract of kiwi could change the structure of male reproductive tissues. So, 40 male rats were divided into four groups. Three experimental groups were fed with 75, 100 and 150 mg/kg of kiwi extract and control groups with solvent for 50 days. Then, rats were sacrificed and their testis, ductus deferens, seminal vesicle, prostate and epididymidis were removed, fixed, processed and stained with H & E and Acridine Orange. The specimens were studied under light and fluorescent microscopes. Histological observations revealed some changes in the structure of testes, but not in the other parts of male reproductive tissues. Some spermatocytes have become fusiform and the number of these cells has been increased, dose dependently. There were many spermatocytes at the metaphase stage, among 100 and 150 mg/kg treated groups; Some of the mitotic figures, sperm, most of the spermatogonia and spermatocytes stained red with Acridine Orange, which indicates denaturation of DNA strands. A few fragmented nuclei were also observed in the 150mg/kg treated group. In conclusion, it seems that extract of kiwi can change the spermatocyte cytoarchitecture and affects the spermatogonia and spermatozoa. It may exert dual effects on the proliferating cells, such as spermatogenesis lineage. In low concentrations it could induce proliferation, and in high concentrations, it may lead to cell death and nucleus fragmentation. The extract may elongate the period of the metaphase.

Keywords – *Actinidia Chinensis*, testis, reproductive tissues, phytoestrogen

1. INTRODUCTION

Plant foods, in addition to their traditional value, contain non-nutritional phytochemicals that may exert long-term health promoting effects in humans [1]. The decline in human sperm quality over recent decades may be related to an increase in exposure to environmental endocrine disruptors [2]. The potential reproductive benefits and/or toxicity of most of the environmental agents to which animals and humans are daily exposed to is not known. Kiwi (*Actinidia Chinensis*) is used extensively as a fruit in Iran. It is a rich source of vitamin C, E [3], fructose, galactose, minerals, isoflavones [1], flavonoid [4] and serotonin [5].

*Received by the editor May 29, 2004 and in final revised form July 4, 2005

**Corresponding author

Flavonoid and isoflavones, which are important phytochemicals in kiwi extract, are the major class of phytoestrogens [6]. Phytoestrogen are naturally plant-derived compounds that are functionally and structurally similar to endogenous estrogen, such as estradiol [7]. Various studies have demonstrated the health benefits of phytoestrogens in conditions such as vasomotor symptoms [7], and postmenopausal health risk [8-10], as well as anticarcinogenic, neuroprotective and cardioprotective activity [11], prostatic health [7] and bone promoting properties [12, 13]. Men have a low concentration of estrogen in the blood stream, but it can be extraordinary high in semen and rete testis fluid. It is well known that male reproductive tissues express estrogen receptors [14]. Meanwhile, serotonin has been found in gonads and accessory reproductive organs of several species [15]. The role of serotonin in the male reproductive system was also studied by many investigators [16-21]. Kiwi, with its serotonin content may have some effects on male reproductive tissues.

Knowing this, it is essential to investigate the effects of the phytochemicals of kiwi on various reproductive organs.

2. MATERIALS AND METHODS

Forty Sprague Dawley male rats (purchased from the animal house of Shiraz University of Medical Sciences), were acclimated to the laboratory condition for one week, prior to the experiments. They were maintained in a controlled temperature (22-24°C) and a light and dark period (14 hours of lightness, 10 hours of darkness). Rats were given food and tap water ad libitum.

Kiwi extraction was obtained using a percolating method. For hydroalcoholic extraction of kiwi, fresh fruit was obtained from a commercial supplier during the summer, peeled, sliced and dried in an open shadow. The dried fruit was then powdered. One hundred grams of powder was put into a percolator and 80 mL of 50% ethanol was added to the powder over three days. The flow rate of solvent was 5mL/kg/min. The extract solution was collected and the solvent was evaporated. Four hundred and seventy-nine samples of semisolid extract were obtained and the appropriate amounts were mixed with saline to obtain different concentrations.

All rats were divided into four groups and given daily gavage administration of 1 ml of solvent (water) or 75, 100 and 150 mg/kg/ day of hydroalcoholic extract of kiwi fruit for fifty days.

Histological studies

The rats were dissected on the 50th day under deep anesthesia, and their right testis, epididymidis, ductus deferens, seminal vesicle and prostate were removed and fixed with buffered formalin. The specimens were sectioned (5 µm thickness) and stained with H&E. Some sections were randomly stained with acridine orange and studied under a fluorescent microscope.

3. RESULTS

The histological observations revealed structural changes in testes, but not in the other parts of the reproductive tissues. Spermatocytes in seminiferous tubules became fusiform and the number of these cells has been increased dose dependently, so that the fusiform spermatocyte cells were mostly observed in 150 mg/kg treated groups (Figs. 1 & 2). There were some spermatocytes at metaphase stages. The number of these cells in the metaphase stage was dose dependent (Fig. 3). But, only a few spermatocytes of the control groups were at this stage.

A few cells with fragmented nuclei such as those found in apoptotic cells were observed in the treated group with 150mg/kg of kiwi extract (Fig. 4).

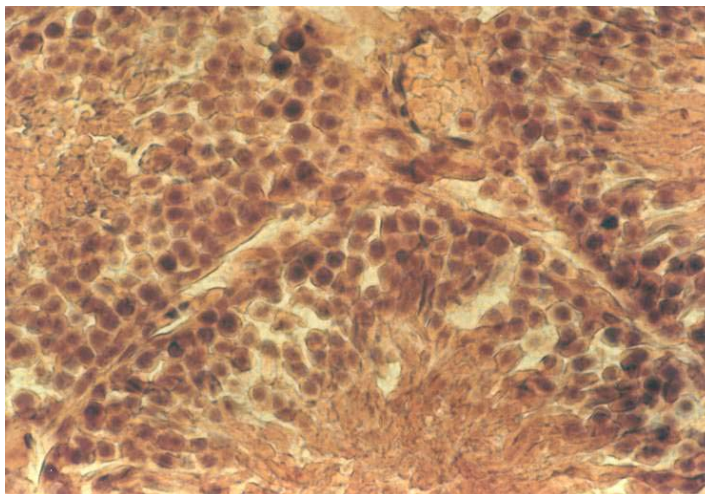


Fig. 1. Testis of the control group. The spermatogenesis lineage are normal (H & E staining, 400X)

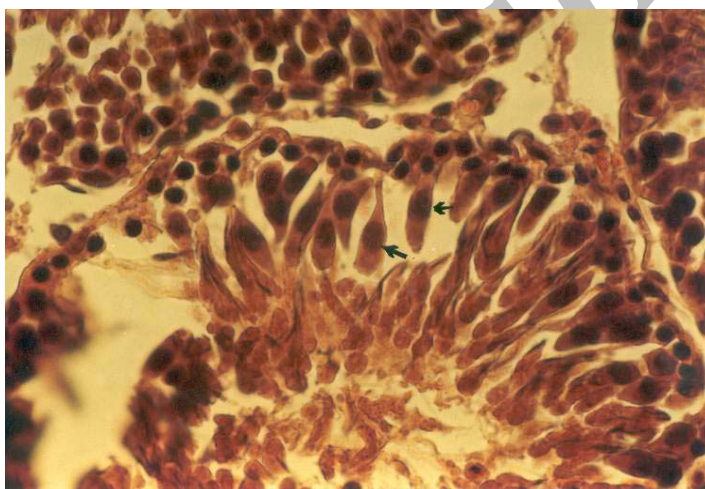


Fig. 2. Testis of the rat treated with 150 mg/kg of kiwi extract. The spermatocytes (arrows) are fusiform (H & E, 400X)

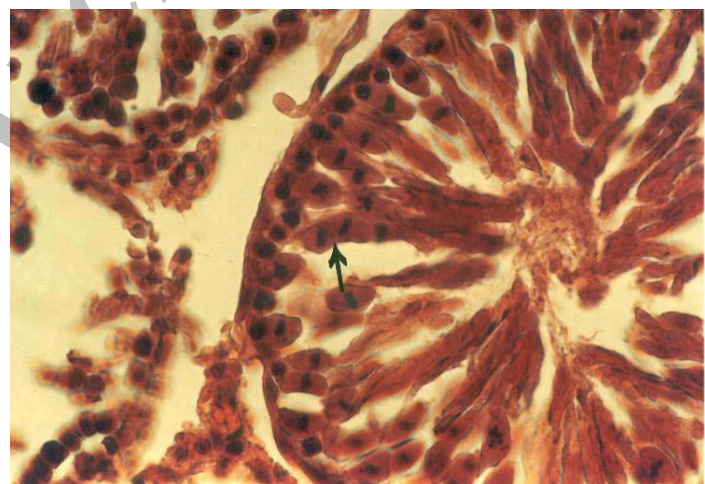


Fig. 3. Testis of the rat treated with 150mg/kg. Spermatocyte (arrow) are in metaphase stage (H & E, 400X)

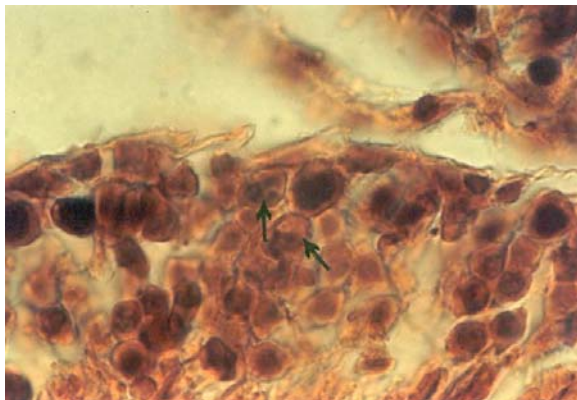


Fig. 4. One seminiferous tubule. Arrows show fragmented nucleus which may indicate apoptosis (H & E, 1000X)

Some nuclei of the spermatogenesis lineage in high dose treated groups were stained yellow to orange by Acridine Orange, which indicate the partial denaturation of DNA (Fig. 5). All sperm nuclei were stained green in the control group (Fig. 6). Some of the mitotic figures and most of the spermatogonia and spermatocytes stained yellow, which indicate partial denaturing of DNA in all groups. Both in experimental and control groups, the cells showed intense nuclear fluorescence. The same reaction is observed in apoptosis.

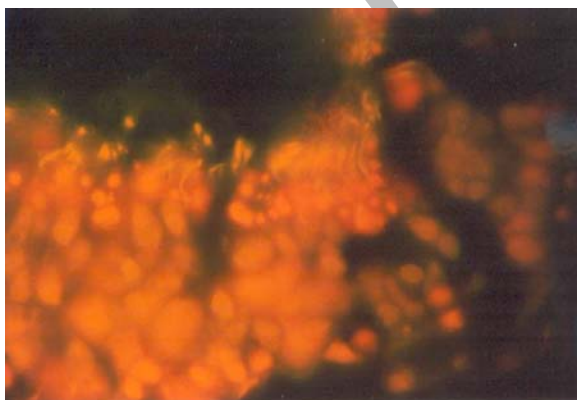


Fig. 5. A seminiferous of a rat treated with 150mg/kg of kiwi extract. The sperm stained yellow (Acridine Orange, 1000X)

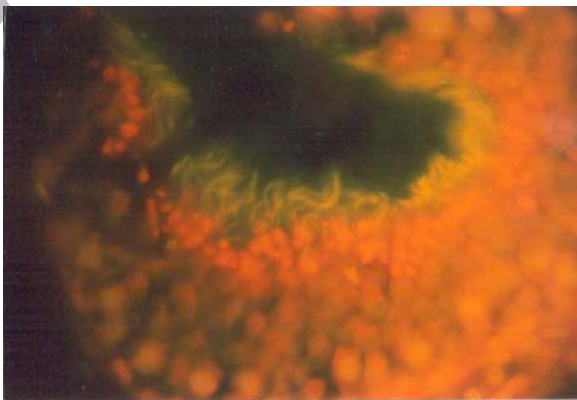


Fig. 6. A normal seminiferous tubule with sperms having normal green florescent nuclei (Acridine Orange, 1000X)

4. DISCUSSION

Kiwi is a rich source of vitamin C, fructose [1, 3], isoflavones [3], flavonoids [4] and serotonin [5]. There is some evidence which shows the effects of ascorbic acid and fructose on sperm quality [22, 23]. It has been shown that the level of seminal fructose give no information on clinical usefulness in defective sperm formation [22]. The antioxidant properties of vitamin C may have delayed formation of degenerative cells in the testis of turkeys [24]. Regarding the changes in histology of testes, after treatment with kiwi extract, other phytochemicals in the extract may have exerted the effects on testis microscopic structure [25].

It has been suggested that isoflavone genestein manifested a concentration dependent dual effect with regard to growth promotion and inhibition on testicular cells in invitro. Using a low concentration of genestein (<10µg/ml), the testicular cell growth is stimulated and at the concentration of >10-100 µg/ml, genestein progressively and significantly inhibits the growth and proliferation of the cells, and causes apoptosis [26-28].

The increasing number of spermatocytes in the metaphase stage, in all experimental groups, may be related to the low concentration of isoflavones and flavonoid content of kiwi extract; meanwhile a few cells with fragmented nuclei-like apoptotic cells, in 150 mg/kg of the kiwi extraction treated group were also observed. It seems that the concentration of isoflavones reached to the threshold of dual action in this group [25]. However, more research is needed to understand the exact mechanism of the events.

Serotonin is another component that can be found in kiwi [5]. The effects of serotonin on the histological structure of testis were investigated by Hodger et al. [29]. Focal damage ranging in severity from increased degeneration of spermatoc cell profiles to complete loss of the germinal epithelium were observed at 10 mg/kg of serotonin; However, many seminiferous tubule profiles displayed completely normal [29]. Kiwi has 5.8± 0.9 microgram/g of serotonin [5]. Lack of degeneration in a seminiferous tubule, even in the high dose of kiwi extract, may be related to the low concentration of serotonin in the extraction. Besides, absorption of serotonin in the digestive system should also be considered. Therefore, it seems that the changes observed may be more attributed to the phytoestrogen rather than serotonin content of kiwi extraction.

The parameter of chromatin condensation and stability can be a valuable index of sperm quality, reflecting the possible disorders in spermatogenesis and epididymal sperm maturation [30]. The decrease in green fluorescence intensity was caused by changes in the binding of DNA to basic proteins in such a fashion as to impede the access of dye to the DNA double helix [31]. The yellow color of the sperm after using a high dose (150 mg/kg), may be attributed to the partial denaturation and loss of the binding of the DNA to basic protein. Therefore, kiwi can lead to the decline of the sperm quality.

In conclusion, kiwi extract can change the testes histological structure and lead to DNA denaturation and apoptosis. However, to state the mechanism by which kiwi exerts its effects needs more investigation. Although the effects of kiwi extract in human reproductive activities are unknown, regarding these studies, it is better to recommend infertile men or men with reproductive disorders to avoid eating kiwi during treatment.

Acknowledgments- The authors wish to thank the research deputy of Medical Sciences of Shiraz University for financial support, and also animal house personnel F Pirsalami and Arasteh for their excellent technical support.

REFERENCES

1. Muzur, W. & Adiercreutz, H. (1998). Natural and anthropogenic environmental oestrogens: the scientific basis for risk assessment: Naturally accruing oestrogens in food. *Pure & Appl Chem*, 70, 1759-1776.

2. Michell, J. H., Cawood, E., Kinniburgh, D., Provan, A., Collins, A. R. & Irvine, D. S. (2001). Effects of the phytoestrogen food supplement on reproductive health in normal males. *Clin Sci (Lond)*, 100, 613-608.
3. Vaughan, J. & Geissler, C. A. (1998). The new oxford book of food plants. *Oxford University Press Inc*, 116-117.
4. Arts, I. C., Van de Putte, B. & Hollman, P. C. (2000). Catechin contents of foods commonly consumed in the Netherlands. 1. Fruits, vegetables, staple foods, and processed foods. *J Agric Food Chem*, 48, 1746-1751.
5. Feldman, J. M. & Lee, E. M. (1985). Serotonin content of foods: effect on urinary excretion 5-hydroxyindoleacetic acid. *Am J Clin Nutr*, 42, 639-643.
6. Breithofer, A., Graumann, K., Scicchitano, M. S., Karathanasis, S. K., Butt, T. R. & Jungbauer, A. (1998). Regulation of human estrogen receptor by phytoestrogens in yeast and human cells. *J Steroid Biochem Molec Biol*, 67, 421-429.
7. Bagchi, D., Das, D. K., Tosaki, A., Bagchi, M. & Kothari, S. C. (2002). Benefits of resveratrol in human health in normal males. *Drugs Exp Clin Res*, 27, 233-248.
8. Mei, J., Yeung, S. S., Kung, A. W. (2000). High dietary phytoestrogen intake is associated with higher bone mineral density in postmenopausal women. *J Clin Endocrinol Metab*, 86, 5217-5221.
9. Cutler, S. J., Cutler, J. A., Cutler, H. G. (2002). Phytoestrogen in hormone replacement therapy. *Pharmacist*, 27, 56-64.
10. Chiechi, L. M., Secreto, G., D'Amore, M., Fanelli, M., Venturelli, E., Cantatore, F., Valerio, T., Laselva, G. & Loizzi, P. (2002). Efficacy of a soy rich diet in preventing postmenopausal osteoporosis: the menfits randomized trial. *Maturitas*, 30, 42, 295-300.
11. Brzezinski, A. & Debi, A. (1999). phytoestrogens: The natural selective estrogen receptor modulators? *Eur J Obst Gynecol Biol*, 85, 47-51.
12. Arimandi, B. H., Birnbaum, R. S., Juma, S., Barengolts, E. & Kukreja, S. C. (2000). The synthetic phytoestrogen, Ipriflavone and estrogen prevent bone loss by different mechanisms. *Calcif Tissue Int*, 66, 61-65.
13. Viereck, K., Grundker, C., Blaschke, S., Siggelkow, H., Emons, G. & Hofbauer, L. C. (2002). Phytoestrogen genestein stimulates the production of osteoprotegerin by human trabecular osteoblast. *L Cell Biochem*, 84, 725-735.
14. Hess, R. D., Bunick, D., Lee, K. H., Bahr, J., Taylor, J. A., Korach, K. S. & Lubahn, D. B. (1997). A role for estrogens in the male reproductive system. *Nature*, 390, 509-511.
15. Frungieri, M. B., Gonzalez-Calvar, S. I., Rubio, M., Ozu, M., Lustig, L. & Calandra, R. S. (1999). Serotonin in golden hamster testes: testicular levels, immunolocalization and role during sexual development and photoperiodic regression-recrudescence transition. *Neuroendocrinology*, 69, 299-308.
16. Piner, J., Sutherland, M., Millar, M., Turner, K., Newall, D. & Sharpe, R. M. (2002). Changes in vascular dynamics of the adult rat testis leading to transient accumulation of seminiferous tubule fluid after administration of a novel 5-hydroxytryptamine (5-HT) agonist. *Reprod Toxicol*, 16, 141-150.
17. Syed, V., Gomez, E. & Hecht, N. B. (2002). Messenger ribonucleic acids encoding a serotonin receptor and a novel gene are induced in Sertoli cells by a secreted factor(s) from male rat meiotic germ cells. *Endocrinology*, 140, 5754-5760.
18. Arrighi, S. & Domeneghini, C. (1998). Immunolocalization of regulatory peptides and 5-HT in bovine male urogenital apparatus. *Histol Histopathol*, 13, 1049-1059.
19. Piescikowska, I., Lukaszyk, A., Balcerak, M., Filipiak, K., Ludwiczak, H., Butowska, W. & Warchol, J. B. (1996). An implication to the role of testicular serotonergic innervation. An in vitro study on serotonin effects in the control of Leydig cell secretory function. *Folia Morphol (Warsz)*, 55, 414-416.
20. Collin, O., Damber, J. E. & Bergh, A. (1996). 5-Hydroxytryptamine--a local regulator of testicular blood flow and vasomotion in rats. *J Reprod Fertil*, 106, 17-22.

21. Niaraki, M. A. & Subramanian, M. G. (1982). Moghissi KS. Effects of serotonin on reproductive hormone levels and testis morphology in adult male rats. *Proc Soc Exp Biol Med*, 170, 464-470.
22. Andrade Rocha, F. T. (1999). Seminal fructose levels in male infertility: relationship with sperm characteristics. *Int Urol Nephrol*, 31, 107-111.
23. Videla, W., Blanco, A. M., Galli, M. E. & Fernandez-collazo, E. (1981). Human seminal biochemistry: Fructose, ascorbic acid, citric acid, acid phosphatase and their relationship with sperm count. *Andrologia*, 13, 212-214.
24. Neuman, S. L., Orban, J. I., Lin, T. L., Latour, M. A., Hester, P. Y. (2002). The effect of dietary ascorbic acid on semen traits and testis histology of male turkey breeders. *Poult Sci*, 81, 265-268.
25. Panahi Z, (2002). A study of the effects of hydro alcoholic extract of kiwi on sex hormon level, sperm quality and reproductive tissues. Medical University of Shiraz, School of Pharmecy, 167, 49-50.
26. Kumi-Diaka, J., Nguyen, V. & Butler, A. (1999). Cytotoxic potential of the phytochemical genestein isoflavone (4, 5, 7, trihydroxyisoflavone) and certain environmental chemical compounds on testicular cells. *Biol Cell*, 91, 515-523.
27. Kumi Diaka, J., Rodriguez, R., Goudze, G. (1998). Influence of genestein (4, 5, 7, trihydroxyisoflavone) on the growth and proliferation of testicular cell lines. *Biol Cell*, 90, 349-354.
28. Nagao, T., Yoshimura, S., Saito, Y., Nakagoni, M., Usumi, K. & Ono, H. (2001). Reproductive effects of male and female rats of neonatal exposure to genestein. *Rep Toxicol*, 15, 399-411.
29. Hodger, M. P., Khatab, S., Gonzales, G. & De Kretser, D. M. (1995). Acute and short-term actions of serotonin administration on the pituitary-testicular axis in adult rat. *Reprod Fertil Dev*, 7, 1101-1109.
30. Hingst, O., Blottner, S. & Franz, C. (1995). Chromatin condensation in cat spermatozoa during epididymal transit as studied by aniline blue and acridine orange staining. *Andrologia*. 27, 275-279.
31. Golan, R., Vigodner, M., Oschry, Y., Shochat, L. & Lewin, L. M. (2000). Chromatin condensation during spermiogenesis in the golden hamster (*Mesocricetus aureus*): a flow cytometric study. *Mol Reprod Dev*, 56, 105-112.