

EFFECTS OF A JUVENOID PYRIPROXYFEN ON REPRODUCTIVE ORGAN DEVELOPMENT AND REPRODUCTION IN GERMAN COCKROACH (DICTYOPTERA: BLATTELLIDAE)*

H. FATHPOUR^{1**}, A. NOORI, AND B. ZEINALI²

¹Department of Biology, University of Isfahan, Isfahan, I. R. of Iran
Email: isfunibiosys@yahoo.com

²School of Biology, University of Tehran, Tehran, I. R. of Iran
Email: alinoori_55hotmail.com

Abstract – The German cockroach, *Blattella germanica*, is one of the most common pest species, and is a carrier of many pathogen and allergen factors in humans. Thus, regarding public health, the control of this insect is quite important. Dietary use of hormone analogues, especially juvenoids which disrupt reproductive organ development, is a relatively new method to control cockroaches. In this study, the effect of dietary juvenoid pyriproxyfen was investigated on these insects. The control groups received a regular diet with no juvenoid and each of the treatment groups received 10, 30, 50, 100, or 300 ppm of pyriproxyfen in their diets, respectively. For each dose, 15 fifth-instar nymphs were used and the experiment was replicated three times. Each of the experimental repeats had a separate control group. The treatment period was 14 days, then the insects were fed with a regular diet until they emerged into an adult. At this stage, the treated adults were kept with an untreated opposite sex until the formation of the first egg capsule. Use of pyriproxyfen was found to be effective in inducing abnormalities in wing formation such as divergent, curly wing and giant nymphs. Furthermore, dietary use of this juvenoid caused the sterility of the insects due to incomplete development of the internal reproductive organs. Various morphologic abnormalities like deformation and degeneration were observed in the ovaries and accessory glands of sterile insects. Histological investigation of testis and ovaries in infertile insects indicated a degeneration of ovarian follicle cells, defective vitellogenesis, hypertrophy of testis walls, spermatogenesis disorder and a decrease in the numbers of spermatocysts and spermatozoa. The external genitalia of the sterile insects in both sexes were not significantly altered compared with the controls.

Keywords – German cockroach, pyriproxyfen, wing twisting, reproductive organ, sterility

1. INTRODUCTION

Control of the German cockroach, *Blattella germanica*, continues to be a serious problem. In addition to its high reproductive potential [1] and its ability to build up large infectious populations [2], this insect can develop resistance to insecticides to a significant level [3]. Additionally, this insect is the carrier of many pathogen and allergen factors in habitable environments [4]. Therefore, finding new methods to control these insects is very important.

One of the new control methods is the application of insect growth regulators (IGRs) having juvenile hormone (JH) activity, the so called "juvenoids". These compounds induce a variety of reproductive, developmental and morphogenetic effects on the insects [5]. They are also effective on household pests such as houseflies, *Musca domestica* [6] and cockroaches, *Blattella germanica* [7]. In some cases, these juvenile hormone analogues (JHA) induce strong suppression of embryogenesis, metamorphosis and adult

*Received by the editor April 11, 2006 and in final revised form December 11, 2006

**Corresponding author

formation of the insects [8], and are widely used to control pest insects. Juvenile hormone analogs are absorbed through the insect's cuticle and persist in the body during the period of development when JH is usually absent. During the JH sensitive periods, JHAs act like JH, preventing the activation of genetic switches in the developmental program of organs and cells for the formation of embryonic, larval, pupal or adult tissues [9].

Das and Gupta [10], for the first time, reported that cockroaches treated with JHA as nymphs emerged as adultoids. Lim and Yap [11] investigated the contact effect of a JHA, pyriproxyfen, on the 4th-instar nymphs of the German cockroach. They reported the morphogenetic abnormalities and sterility effects of this juvenoid. Pyriproxyfen also induced the formation of large autophagic vacuoles in maturing oocytes, leading to the partial reabsorption of yolk, the degeneration of the nucleus, and lysis of the follicular epithelium [12]. King and Bennett [13] demonstrated that the JHAs, fenoxycarb and hydroprene, induced morphological deformities and induced sterility to adult German cockroaches when applied to the last instar. Juvenoids have also been found to disrupt vitellogenesis in honeybees [14]. In this research, the effects of pyriproxyfen on the reproduction of the German cockroach were studied by the examination of ovaries, testis and external genitalia development.

2. MATERIALS AND METHODS

a) Insect and Chemicals

The source of German cockroaches were houses and apartments in Isfahan. They were reared at room temperature ($25\pm 2^\circ\text{C}$), a relative humidity of $72\pm 3\%$, and were fed by pellet (mouse food). The fifth instar nymphs of the insects were used to investigate the effects of pyriproxyfen (pure pyriproxyfen [4-phenoxyphenyl (RS)-2-(2-pyridyloxy) propyl ether] was a gift of Somitomo Company, Japan). Pyriproxyfen was mixed with the pellet for each set of experiments. For each repeat of the experiments, 90 nymphs were obtained and distributed into six groups of 15 each. The control group received a regular diet and each of the other five groups received 10, 30, 50, 100, or 300ppm pyriproxyfen in the diet, respectively. This compound was dissolved in acetone to prepare the desired concentrations. The dietary treatment period was 14 days and then, all the insects were fed a regular diet until they emerged into adults. The experiments were replicated three times and for each of the repeats a separate control group was utilized.

b) Effects of pyriproxyfen on morphology and reproduction

After the maturation of the treated insects, the appearance of wing twisting and giant nymphs were investigated. In order to study the effects of pyriproxyfen on reproduction, each treated insect was kept with an untreated opposite sex in a separate jar until the formation of the first egg capsule. Then, the fertility or infertility of the capsule was studied.

c) Effects of pyriproxyfen on reproductive organs

To investigate the effects of pyriproxyfen on the internal structure of the ovaries and testes of the insects, these organs were fixed in Bouin's solution (formalin 25%, picric acid 75% and acetic acid 5%) for 12 hours and then dehydrated. The organs were embedded in paraffin, sectioned ($7\mu\text{m}$ thick) and stained with hematoxylin-eosine. Histological abnormalities were studied. Photographs of the sections were taken using an Olympus SZX 12 microscope.

d) Data analysis

The data were analyzed with descriptive statistics using the SPSS package version 13. The statistical methods used are based on the frequency of distribution, Chi square (χ^2) and nonlinear logistic regression.

3. RESULTS

a) Effects of pyriproxyfen on morphology

The morphological changes such as divergence and curly wings, and in some cases the formation of giant nymphs without wings, were observed in both sexes with different doses of pyriproxyfen (Table 1). With the increasing concentrations of pyriproxyfen the percentage of abnormalities were significantly ($P \leq 0.01$) increased in both sexes. At a concentration of 300 ppm, 96.8% of males and 85.7% of females were abnormal (Table 1).

Table1. Phenotypes in an experiment on feeding pyriproxyfen to late-instar German cockroaches

Concentration (ppm)	Male			Female		
	Number ¹	Phenotype ^a	%Abnormality ^b	Number ²	Phenotype ^a	%Abnormality ^b
0	26	26+	0	19	19+	0
10	24	24+	0	21	18+ 3d	14.3%
30	25	19+ 6d	24%	20	14+ 6d	30%
50	24	19+ 5d	20.8%	21	14+ 7d	33.3%
100	24	7+ 14d 3c	70.8%	21	5+ 16d	76.2%
300	31	1+ 15d 7c 8n	96.8%	14	2+ 8d 4n	85.7%

¹The total number of males at each concentration

²The total number of females at each concentration

(The total number of males and females at each concentration = 45)

^a Insects phenotype after treatment: +, normal, d, divergent wing, c, curly wing, n, giant nymph.

^b Percentage based on total number tested at each concentration. The relationship between concentration and %abnormality is significant ($P \leq 0.01$; χ^2 test).

b) Effects of pyriproxyfen on reproduction

The effects of pyriproxyfen on reproduction were investigated regarding the fertility of egg capsules. The sterile egg capsules were wrinkly, discolored, partially developed, and some had no nymphs. However, neither sterile or fertile insects were observed on both normal and abnormal cockroaches, whereas sterile curly wings and nymphoids appeared only at 100 and 300ppm treatments (Table 2). The percentage of sterility was significantly ($P \leq 0.01$) increased in both sexes with the additive concentrations of pyriproxyfen (Table 2). According to the results, the occurrence of female sterility at lower doses of (≤ 30 ppm) pyriproxyfen indicates that females were affected more severely than males.

Table 2. Reproduction in an experiment on feeding pyriproxyfen to late-instar German cockroaches

Concentration (ppm)	Male			Female		
	Number ¹	Sterility ^a	%Sterility ^b	Number ²	Sterility ^a	%Sterility ^b
0	26	26f+	0	19	19f+	0
10	24	23f+ 1s+	4.2%	21	15f+ 1fd 3s+ 2sd	23.8%
30	25	18f+ 5fd 1s+ 1sd	8%	20	12f+ 2fd 2s+ 4sd	30%
50	24	10f+ 9s+ 5sd	58.3%	21	10f+ 1fd 4s+ 6sd	47.6%
100	24	3f+ 1fd 4s+ 13sd 3sc	83.3%	21	3f+ 2fd 2s+ 14sd	76.2%
300	31	1s+ 15sd 7sc 8sn	100%	14	1f+ 1s+ 8sd 4sn	92.9%

¹The total number of males at each concentration

²The total number of females at each concentration (The total number of males and females at each concentration = 45) ^a Numbers of treated adults in reciprocal crosses of treated cockroaches and wild types. s. sterile f. fertile +. normal, d. divergent wing, c. curly wing, n. giant nymph. ^b Percentage based on total number tested at each concentration. The relationship between concentration and % sterility is significant, ($P \leq 0.01$; χ^2 test).

c) Correlation between wing twisting and sterility

The logistic regression analysis of the data revealed no significant differences between sterility and wing twisting of both male and female insects ($P \leq 0.05$). Thus, to study the relationship between abnormality and sterility, all the data were accumulated. The results indicated that the percentage of sterility in abnormal insects was significantly greater than normal ones. Thus, there is a significant ($P \leq 0.01$) correlation between infertile crosses and morphological abnormalities (Table 3).

Table 3. The percentage of sterility in normal and abnormal phenotypes

Concentration (ppm)	Number ¹	Number ²	%Normality Sterile ^a	Number ³	Number ⁴	%Abnormality Sterile ^a
10	42	4	9.5%	3	2	66.7%
30	33	3	9.1%	12	5	41.7%
50	33	13	39.4%	12	11	91.7%
100	12	6	50%	33	30	90.9%
300	3	2	66.7%	42	42	100%

¹ The total number of normal insects (male + female) at each concentration.

² The total number of sterile insects (normal) at each concentration.

³ The total number of abnormal insects at each concentration.

⁴ The total number of sterile insects (abnormal) at each concentration.

^a Percentage based on total number tested at each concentration (male + female).

The relationship between %sterility (normal and abnormal) and concentration is significant, ($P \leq 0.01$; χ^2 test; $R^2=0.653$).

d) Effects of pyriproxyfen on external and internal reproductive organs of female insects

In comparison with the controls, the presence of a juvenoid has led to the incomplete development of ovaries and different abnormalities such as defective and deteriorated ovarioles and partial developed eggs (Fig. 1). In some cases, the external part of the oviduct was extensively wrinkled (Fig. 1, No. 3). Also, the ovarioles were degenerated in some parts at 10 ppm (Fig. 1). Growth and development of the ovaries were completely inhibited with 300-ppm pyriproxyfen (Fig. 1, No. 1). This concentration caused the complete degeneration of the accessory glands, while lower doses were less effective (Fig. 1). Application of pyriproxyfen prevented the normal development of follicle epithelium and caused abnormality, hypertrophy and disruption of this layer. This compound also caused the lysis of the nucleus of the follicle cells. In addition, the absorption of yolk in the eggs of the treated insects was incomplete due to the disruption of the epithelium layer formation. In some cases, the formation of autophagic vacuoles in the vitellus caused the reabsorption and digestion of proteins. Moreover, these vacuoles led to the degeneration of the nucleus of oocytes causing their sterility (Fig. 2).

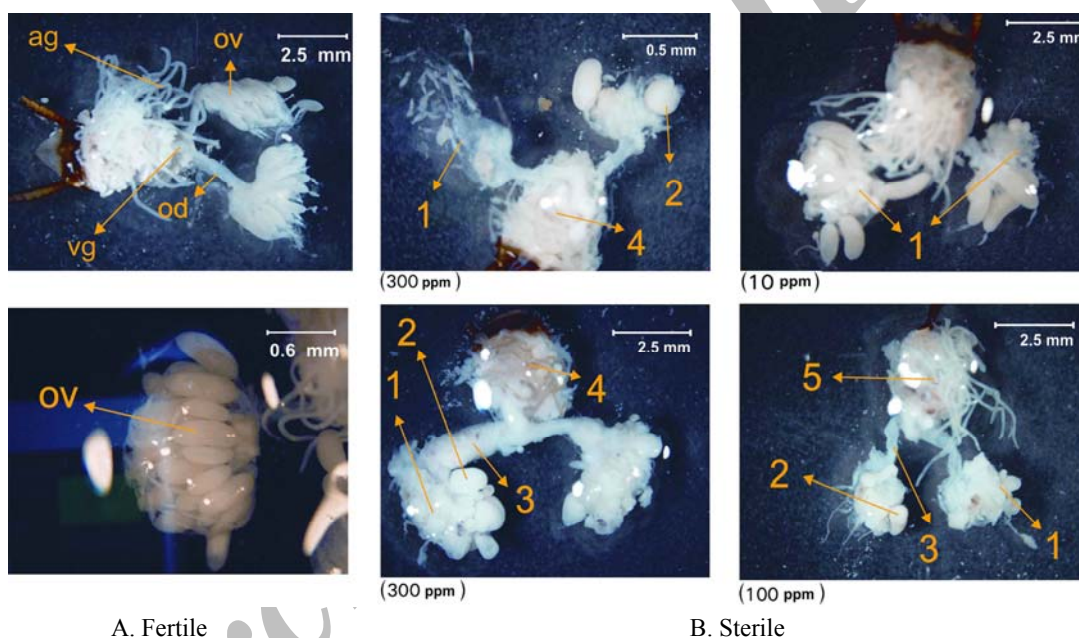


Fig. 1. Internal reproductive system of female German cockroach (ag. accessory gland; od. Oviduct; ov. Ovariole; vg. Vagin; 1. Complete destruction and degeneration of ovarioles; 2. Incomplete development of eggs; 3. Abnormal oviduct; 4. Complete degeneration of accessory glands; 5. Reduction of the accessory gland numbers)

e) Effects of pyriproxyfen on external and internal reproductive organs of males

Pyriproxyfen did not cause any significant morphological alterations on the testis and spermiducts of the sterile male cockroaches in all treatment groups (Fig. 3), although in some cases, abnormal and degenerated accessory glands were observed (Fig. 3). The histological examination of testes of sterile cockroaches showed extreme degeneration and disruption of the testis walls, peritoneum membrane and also the hypertrophy of the epithelium layer. Pyriproxyfen disrupted spermatogenesis, leading to the incomplete development of the sperms (Fig. 4). In some sections of testes, cavities without any cells were observed inside the cysts as well as between different spermatocytes (Fig. 4). As indicated in Fig. 5, pyriproxyfen did not induce any significant structural changes in the external genitalia of either fertile or sterile cockroaches in both sexes, even at 300 ppm.

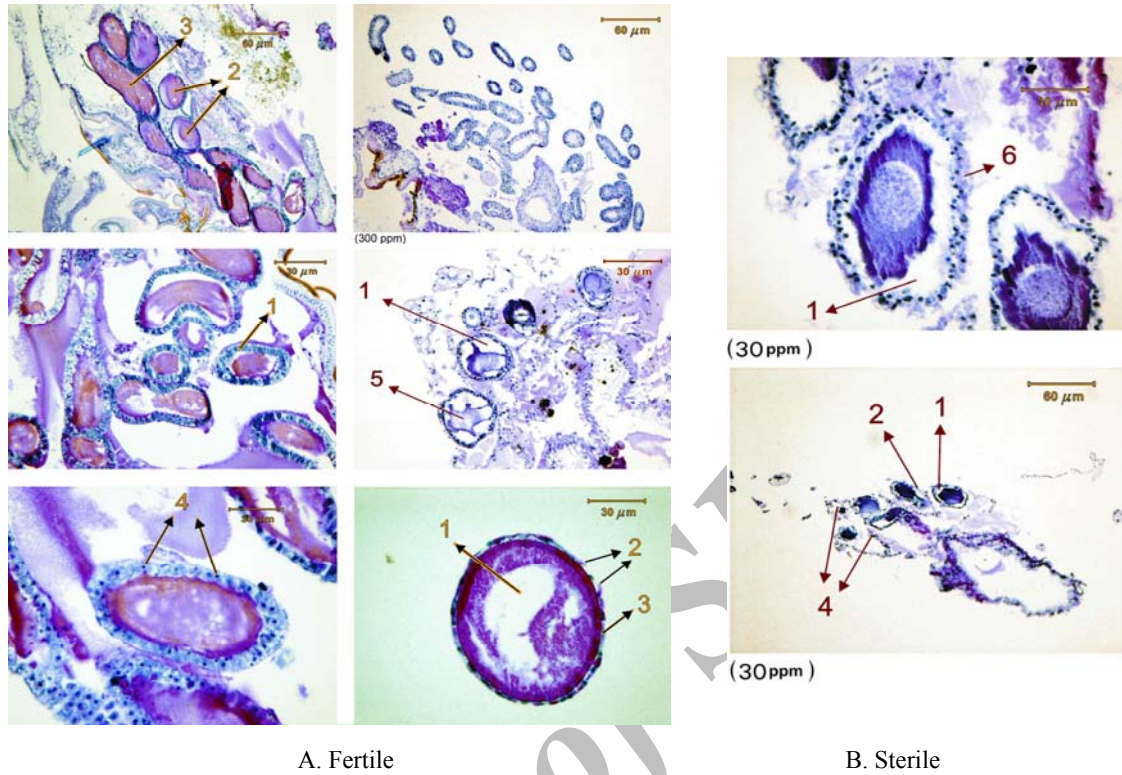


Fig. 2. Internal structure of German cockroach ovaries (A: 1. follicle cells, 2. nucleus of oocyte, 3. vitellus, 4. nucleus of follicle cells; B: 1. defective vitellogenesis and formation of autophagic vacuoles, 2. degeneration of the follicular epithelium, 3. pycnotic of the nucleus of follicle cells, 4. destruction of ovarioles, 5. degenerated nucleus of oocyte 6. abnormal epithelium)

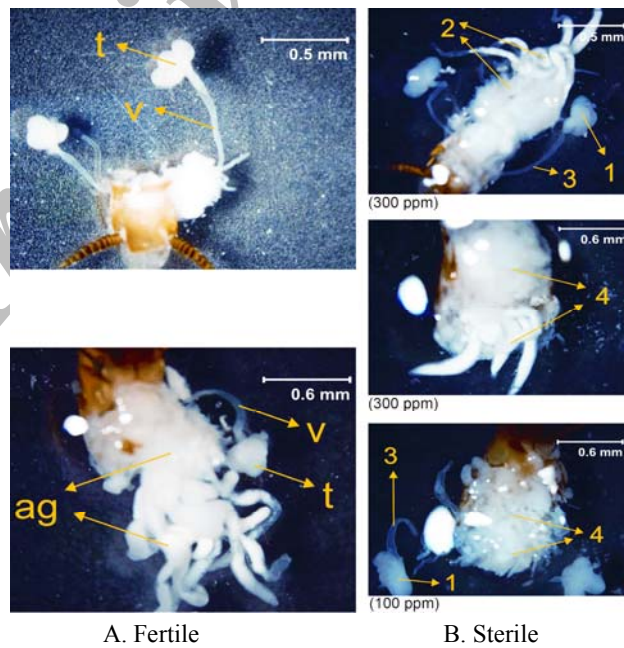


Fig. 3. Internal reproductive system of male German cockroach (t. testis; v. vas deferens, ag. accessory gland, 1. normal testis, 2. normal accessory glands, 3. normal vas deferens, 4. degeneration and destruction of accessory glands)

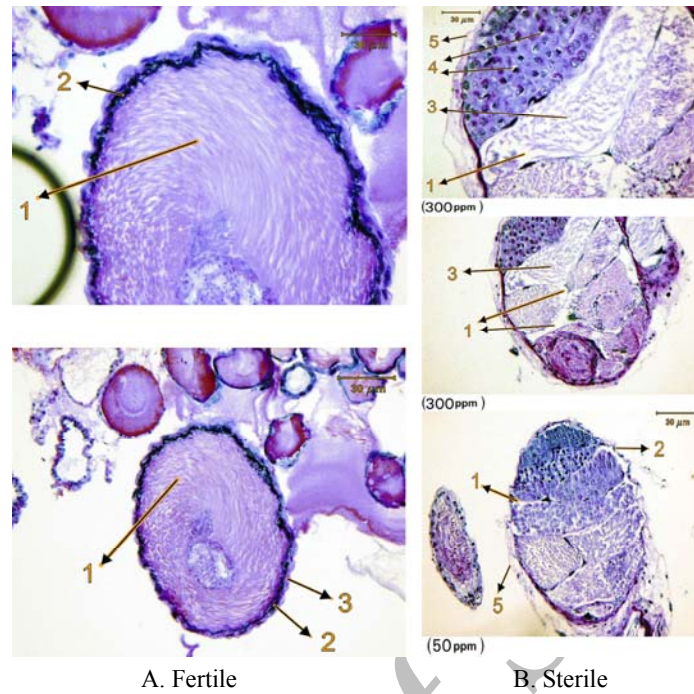


Fig. 4. Internal structure of German cockroach testis (A: 1. adult sperms, 2. testis wall, 3. peritoneum membrane; B: 1. empty cavities, 2. hypertrophy of testis wall, 3. reduction of cell numbers, 4. formation of cavities inside cysts, 5. degeneration of peritoneum membrane)




Fig. 5. Structure of the external genitalia of fertile (top row) and sterile (bottom row) cockroaches (c. cercus, fv. first valvifer, hrp. hooklike right phallomere, lp. left phallomere, mp. median phallomere, ov. ovipositor valve, pp. paraproct, pt. paratergite, sap. supra-anal plate)

4. DISCUSSION

One of the relatively new methods to control cockroaches is applying juvenoid compounds causing physiologic and morphogenetic abnormalities that result in reproductive failure in insects [15]. King and Bennett [13] indicated that cockroaches are more sensitive to juvenoids during the first half of the last-instar of the nymphoid stage. At this stage, ecdysone is released to initiate the development and differentiation of the reproductive organs, leading to metamorphosis [16, 17]. Thus, in this research, the last-instar nymphs were used for all experiments. Divergent wings, giant nymphs, the morphological abnormality of the internal reproductive organs and histological disruption of testis and ovaries were similar to the findings reported by other researchers [18, 11, 19].

Das and Gupta [10] were the first to report that late instars of cockroaches treated with juvenoids emerged as sterile adultoid nymphs. In this study, giant nymphs and the curly wings were sterile from both sexes at 100 and 300 ppm of pyriproxyfen. In addition, with the increasing doses of juvenoid, the percentage of wing twisting was significantly increased ($P \leq 0.01$). These results are also supported by other reports [19, 20].

As shown in Table 2, the low concentrations of pyriproxyfen, i. e. 10 and 30ppm, were more likely to cause the sterility of females compared to males. Ross and Cochran [20] examined the relative effects of individual treatments and also combinations of three IGRs: pyriproxyfen, fenoxycarb, and diflubenzuron on late-instar cockroaches. Those findings are similar to the results of this study.

Application of JHA showed a strong positive correlation between morphogenetic wing twisting and the sterility of cockroaches. Therefore, the probability of sterility in abnormal insects is significantly ($P \leq 0.01$) higher than the controls (Table 3). Similar results were reported earlier [20, 21]. The latter authors also found that apartments treated with pyriproxyfen did not have significant reductions in the number of cockroaches until the percentage of wing twisting was more than 50%. The appearance of nymphoids by using hydroprene also supports the idea of a higher probability of sterility among treated cockroaches [22].

The morphological and histological effects of JHA on the reproductive organs of cockroaches were also investigated in this study. Ovariols, accessory glands and oviducts were degenerated, deteriorated or abnormally developed. In some cases, the development of ovaries and ovariols was completely inhibited. The most important feature of juvenoids was reported as its effects on reproductive organs, causing sterility in the treated insects, leading to their reproductive failure [22].

Pyriproxyfen caused some histological deformities on ovaries including the degeneration of the follicle epithelium, the incomplete deposition of yolk and the presence of empty cavities or autophagic vacuoles in the oocytes. In some ovariols of the treated insects, no vitellus was observed in the oocytes. Similar observations were reported by Masner *et al.* [18] by application of the juvenoid RO8-9801 on *Blattella germanica*. King and Bennett [23] found that fenoxycarb caused physiological abnormalities in the ovaries leading to the production of nonviable oothecae. The application of different hormone analogues to the control, *Thermobia domestica*, leading to the formation of sterile eggs and the inhibition of reproduction was reported by Rohdendorf and Sehnal [24]. In this study, JHA caused the formation of autophagic cavities in the oocytes inducing reabsorption of the yolk, digestion of proteins, degeneration of the nucleus and consequently, infertility of the eggs. These findings are supported by other studies [12, 24].

No significant morphological changes were observed on the testis and spermiduct of the treated sterile males, but histological examinations of the testis of infertile insects indicated hypertrophy of the testis walls, the incomplete development of sperm, and a reduction in the numbers of spermatocyte and spermatozoa. Ross and Cochran [20] also reported similar results by dietary application of pyriproxyfen

and fenoxycarb on the late instar *Blattella germanica*. King and Bennett [25] found that IGRs affect spermatogenesis of the insects. In addition, it was reported that pyriproxyfen prevented the maturity of sperm on *Tribolium castaneum* and *Rhyzopertha dominica* [9].

No significant changes were observed in the morphology of the external genitalia of both sexes, even at the higher treatment dose (300 ppm). Kramer *et al.* [26] reported hydroprene caused a morphological change in the left phallomere of the male genitalia with no changes in the female genitalia, confirming the results of this study. In addition, according to the findings of Ramaswamy and Gupta [27], the treated females and males did not mate due to the effects of JH on their sensillar development.

According to the results of this study and other reports, the application of juvenoids on the German cockroach not only induces morphological deformities, but also causes the sterility of adults. This may be due to the destructive effects of these compounds on reproductive organ development.

Acknowledgements- The authors would like to thank the University of Isfahan for the facilities to perform the experiments and the financial support from the University of Tehran. The authors are also grateful to Dr. J. Moshtaghian for his comments on the final revision of the manuscript.

REFERENCES

1. Willis, E. R., Riser, G. R. & Roth, L. M. (1985). Observation on reproduction and development in cockroaches. *Annual Entomological Society of America*, 51, 53-59.
2. Ross, M. H., Bret, B. L. & Keil, C. B. (1984). Population growth and behavior of *Blattella germanica* (L.) (Orthoptera: Blattellidae) in experimentally established shipboard infestation. *Annual Entomological Society of America*, 77, 740-752.
3. Cochran, D. G. (1989). Monitoring for insecticide resistance in field- collected strains of the German cockroach (Dictyoptera: Blattellidae). *Journal of Economic Entomology*, 82, 336-341.
4. Kopanic, R. J., Sheldon, B. & Wright, C. G. (1994). Cockroaches as vectors of *Salmonella*: laboratory and field trials. *Journal of Food Protection*, 57, 125-132.
5. Liu, T. X. (2003). Effects of a juvenile hormone analog, pyriproxyfen, on *Thrips tabaci* (Thysanoptera: Thripidae). *Pest Management Science*, 59(8), 904-12.
6. Bennett, B., & Rezabova, V. L. (1998). Effects of an analogue of the juvenile hormone on ovarian development and fecundity in the housefly. *Musca domestica*, L. *Institute Entomology*, 186(64), 359-362.
7. Bell, W. J. & Barth, R. H. (1970). Quantitative effects of juvenile hormone on reproduction in the cockroach *Byrsotria fumigata*. *Journal of Insect Physiology*, 13, 2303-2313.
8. Meola, R. W., Dean, S. R. & Bhaskaran, G. (2001). Effects of juvenile hormone on eggs and adults of the Cat flea (Siphonaptera: Pulicidae). *Journal of Medical Entomology*, 38(1), 85-92.
9. Kostyukovsky, M., Chen, B., Atsmi, S. & Shaaya, E. (2000). Biological activity of two juvenoids and two ecdysteroids against three stored product insects. *Insect Biochemical Molecular Biology*, 30(8-9), 891-7.
10. Das, Y. T. & Gupta, A. P. (1977). Effects of three juvenile hormone analogs on the female German cockroach, *Blattella germanica* (L.) (Dictyoptera: Blattellidae). *Experientia*, 30, 1093- 1095.
11. Lim, J. L. & Yap, H. H. (1996). Induction of wing twisting abnormalities and sterility on German cockroach (Dictyoptera: Blattellidae) by a juvenoid pyriproxyfen. *Journal of Economic Entomology*, 89(5), 1161-1165.
12. Meola, R. W., Pullen, S. & Meola, S. (1996). Toxicity and histopathology of the growth regulator pyriproxyfen to adult and eggs of the Cat flea (Siphonaptera: Pulicidae). *Journal of Medical Entomology*, 33(4), 670-679.
13. King, J. E. & Bennett, G. W. (1991). Sensitive developmental period of last-instar German cockroaches (Dictyoptera: Blattellidae) to fenoxycarb and hydroprene. *Journal of Medical Entomology*, 28(4), 514-517.
14. Pinto, L. Z., Bitondi, M. M. & Simoes, Z. L. (2000). Inhibition of vitellogenin synthesis in *Apis mellifera*

- workers by a juvenile hormone analogue, pyriproxyfen. *Journal of Insect Physiology*, 46(2), 153-160.
15. Karhu, R. R. & Anderson, S. H. (2000). Effects of pyriproxyfen spray, powder, and oral bait treatments on the relative abundance of nontarget arthropods of black-tailed prairie dog (Rodentia: Sciuridae) towns. *Journal of Medical Entomology*, 37(4), 612-8.
 16. Olmstead, A. W. & Leblance, G. A. (2003). Insecticidal juvenile hormone analogs stimulate the production of male offspring in the crustacean *Daphnia magna*. *Environmental Health Perspective*, 111(7), 919-24.
 17. Hartfelder, K. (2000). Insect juvenile hormone: from "status quo" to high society. *Brazilian Journal of Medical Biology Research*, 33(2), 157-177.
 18. Masner, P., Hangartner, W. & Suchy, M. (1975). Reduced titers of ecdysone following juvenile hormone treatment in the German cockroach. *Blattella germanica*. *Journal of Insect Physiology*, 21, 1755-1762.
 19. Fathpour, H. & Mir, T. (2003). Effects of juvenile hormone, pyriproxyfen, on German cockroach (Dictyoptera: Epilampridae; *Blattella germanica*). *Research Bulletin of Isfahan University*, 17(1), 87-102.
 20. Ross, M. H. & Cochran, D. G. (1990). Response of late-instar *Blattella germanica* (Dictyoptera: Blattellidae) to dietary insect growth regulators. *Journal of Economic Entomology*, 83(6), 2295-2309.
 21. Koehler, P. G. & Patterson, R. S. (1991). Incorporation of pyriproxyfen in a German cockroach (Dictyoptera: Blattellidae) management program. *Journal of Economic Entomology*, 84(3), 917-921.
 22. Reid, B. L. & Bennett, G. W. (1994). Hydroprene effects on the dynamics of laboratory populations of the German cockroach (Dictyoptera: Blattellidae). *Journal of Economic Entomology*, 87(6), 1537-1546.
 23. King, J. E. & Bennett, G. W. (1990). Comparative sterilizing and ovicidal activity of fenoxycarb and hydroprene in adults and oothecae of the German cockroach (Dictyoptera: Blattellidae). *Journal of Medical Entomology*, 27(4), 642-645.
 24. Rohdendorf, E. B. & Sehnal, F. (1973). Inhibition of reproduction and embryogenesis in the Firebrat, *Thermobia domestica*, by juvenile hormone analogues. *Journal of Insect Physiology*, 19, 37-56.
 25. King, J. E. & Bennett, G. W. (1988). Mortality and developmental abnormalities induced by two juvenile hormone analogs on nymphal German cockroaches (Dictyoptera: Blattellidae). *Journal of Economic Entomology*, 81(1), 225-227.
 26. Kramer, R. D., Koehler, P. G. & Patterson, R. S. (1989). Morphogenetic effects of hydroprene on German cockroach (Orthoptera: Blattellidae). *Journal of Economic Entomology*, 82, 163-170.
 27. Ramaswamy, S. B. & Gupta, A. P. (1981). Effects of juvenile hormones on sense organs involved in mating behaviour of *Blattella germanica* (L.) (Dictyoptera: Blattellidae). *Journal of Insect Physiology*, 27, 601-608.