

Case Report

Middle East Journal of Cancer; January 2018; 9(1): 65-69

Solitary Fibrous Tumor of the Parotid Gland in a Young Female: A Rare Case Report and Review of the Literature

Megha Ralli**, Nisha Marwah*, Mansi Agarwal*, Anshul Sawhney**,
Yashika Bhatia*, Nitesh Kumari*

*Department of Pathology, Pt. B.D. Sharma PGIMS Rohtak, Haryana, India

**Department of Dentistry, UPUMS, Saifai, Etawah, India

Abstract

Solitary fibrous tumor is a rare tumor of the salivary gland. To date, 27 cases have been reported. The clinical and radiological features are the same as other lesions of the parotid gland. Hence, light microscopy and immunostaining is important to confirm the diagnosis. Fine needle aspiration cytology yield depends on the area sampled and can be inconclusive in many cases. Treatment of choice is complete surgical excision with regular long-term follow up. Most cases are benign, however three malignant cases have been reported. Here, we report a case of solitary fibrous tumor in the parotid gland seen in a 14-year old female diagnosed by histopathological examination and immunohistochemistry analysis.

Keywords: SFT, Parotid, Immunohistochemistry (IHC), Mesenchymal, Benign

Introduction

Solitary fibrous tumor (SFT) is a rare mesenchymal tumor first diagnosed by Klemperer and Rabin in 1931 in the pleura.¹ These tumors are seen on serosal surfaces, however in recent years they have been reported in extrapleural sites such as the liver, adrenal glands, skin, and less commonly in the head and neck region, accounting for approximately 6%.² Solitary fibrous tumor of the salivary gland is very rare and only 27 cases have been reported in the English literature until now.³ These

tumors generally present as well-defined, palpable, slowly growing masses. Clinical presentation and radiographic findings are similar to that of other tumors which are more common in the salivary glands. Hence, diagnosis of SFT can be only made according to histological and immunohistochemical (IHC) findings. Extrathoracic SFT has an excellent prognosis due to its benign behavior.⁴ The treatment of choice is complete surgical excision of the lesion. Since recurrence and metastasis can take place after several

♦Corresponding Author:
Megha Ralli, MD
30/32 West Patel Nagar
New Delhi-110008, India
Tel: 07206191047
Email: drmegharalli@gmail.com



Received: January 7, 2017; Accepted: May 27, 2017

years, regular lifelong clinical and imaging follow-up is compulsory.⁵ Here, we have reported a case of SFT in the parotid gland that presented as a painless swelling in a 14-year old female diagnosed by the IHC staining pattern.

Case Report

A 14-year old female presented to the surgery Outpatient department with complaints of pain and swelling in the left parotid region since 3 weeks. Physical examination revealed a fixed, smoothly contoured swelling that measured 6×4 cm with overlying normal skin. There was no cervical lymph node enlargement. There was no facial palsy or any evidence of tumor extension in the pharynx, larynx, or oral mucosa. Fine needle aspiration (FNA) was performed and yielded scant fibrous tissue and lymphocytes. Magnetic resonance imaging revealed a well-defined tumor that measured 6 cm in its greatest dimension in the superficial lobe of the left parotid gland. There was high signal intensity with homogeneous enhancement in T2-weighted images. She was taken to the operating room for local resection of the mass.

The resected specimen was sent to our department for histopathological examination. The mass was well-circumscribed and measured 6×4×2.5 cm. The cut section was homogenous grey-white. Microscopic examination revealed

proliferation of spindle cells arranged in a storiform pattern. The tumor cells had bland nuclei and tapering ends that depicted its benignity (Figure 1). Vessels were normal, which ruled out the histological possibility of a hemangiopericytoma (HPC). Mitosis was 1-2/10 high power field. There were no areas of necrosis, atypical mitosis, bizarre pleomorphic cells or other signs of malignancy. These tumor cells were positive for vimentin, CD34, Bcl-2, and CD99. They were negative for S-100, desmin, SMA, and myogenin (Figures 2, 3, 4). Thus, IHC helped in differentiating SFT from schwannoma, rhabdomyoma, and leiomyoma. CD34 is an important, sensitive marker of SFT and was strongly positive in our case.

Hence, on basis of histological features and IHC, diagnosis of SFT was made. The patient currently remains in followed up with no signs of recurrence.

Discussion

Solitary fibrous tumor of the parotid gland is very rare tumor that generally presents itself as a painless, firm, slow-growing lesion of a few months to few years duration. Symptoms of obstructive sleep apnea are relatively common and may be related to parapharyngeal extension of the tumor. However, facial nerve palsy is rare.³ There is no predilection based on age or gender.

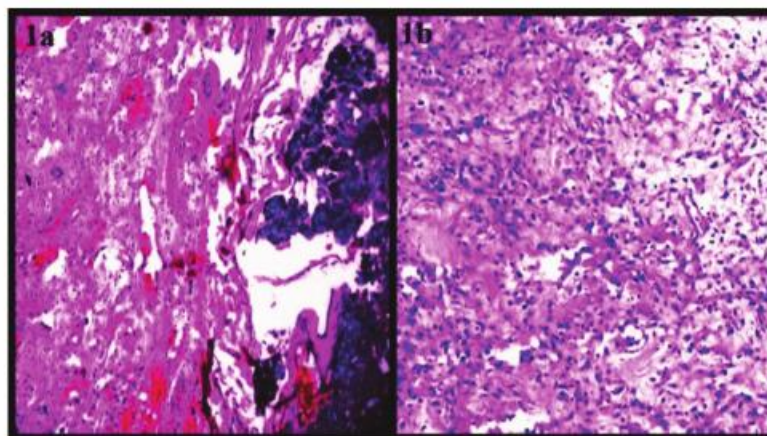


Figure 1. (A) H&E stained section that shows normal salivary gland compressed on one side with spindle cell tumor proliferation on the left (40×). (B) H&E stained section that shows proliferation of spindle cells arranged in a storiform pattern, with bland nuclei and tapered ends (200×).

A review of the literature by Bauer et al. from 1960 to 2011 has shown only 22 reported cases in the parotid region, 3 of which were malignant.⁶ These tumors are benign in nature with a good prognosis.

According to the literature, parotid SFT is equally distributed amongst males and females, and usually presents during middle-aged, although it has been described in young patients.⁵⁻⁸ Magnetic resonance imaging shows that SFTs are homogeneous and isointense to muscle. On T1- and T2-weighted images, they are heterogeneous and mildly hyperintense. They also strongly enhance post-gadolinium in areas of mild hyperintensity on T2-weighted images.⁹ Clinical presentation is similar to tumors such as pleomorphic adenomas, schwannomas, fibrous histiocytomas, and lipomas with nonspecific radiographic findings. Therefore, a diagnosis of SFT can only be performed based on histological and IHC findings.

Clinical differential diagnosis in such cases includes conditions that cause unilateral parotid enlargement, such as salivary gland tumors, mesenchymal neoplasms, lymphomas, Sjögren's syndrome, sarcoidosis, sialadenosis, and infections.¹⁰ Excision is performed in such cases and microscopy reveals round-to-spindle cells arranged in a storiform pattern with bland or vesicular nuclei and tapering cytoplasm in a variably collagenous stroma. In areas of low cellularity, thick collagen bundles separate the tumor cells. Myxoid stromal change along with scattered multinucleated giant cells or a mild lymphoplasmacytic infiltrate may be found. These

may be associated with numerous mid-caliber vessels scattered throughout the tumor along with hyalinized walls. There may be alternate areas of hyper- and hypocellularity. Our case has shown the typical morphology of a fibrous variant of SFT described by Gengler and Guillou.¹¹ Pre-operative diagnosis of this tumor by FNA is challenging because its rarity renders little to no diagnostic suspicion.^{3,4} Further, because the fibrous variant of SFT has alternating hypercellular and hypocellular fibrous areas, FNA interpretation is subject to sampling bias. Sampling of hypercellular areas yields sheets and three-dimensional clusters of monomorphic fusiform spindled cells in a background of capillaries and wispy collagen.⁶ However, sampling of hypocellular fibrous areas yields predominantly stromal collagen, which may be interpreted as non-diagnostic.

Histological features associated with malignancy include high cellularity, pleomorphism, necrosis, high mitotic rate (>6 mitoses/10 high power field in tumors considered malignant), and/or infiltrative margins.⁶⁻⁸ Due to the wide spectrum of histologic features, there is a broad differential diagnosis that includes nodular fasciitis, myoepithelioma, spindle cell carcinoma, spindle cell lipoma, spindle cell melanoma, schwannoma, HPC, dermatofibrosarcoma protuberans, fibrous histiocytoma, meningioma, myofibroblastoma, neurofibroma, monophasic synovial sarcoma, Kaposi sarcoma, and malignant peripheral nerve sheath tumor.⁵⁻⁸ Schwannoma contains Antoni A and B areas which are absent

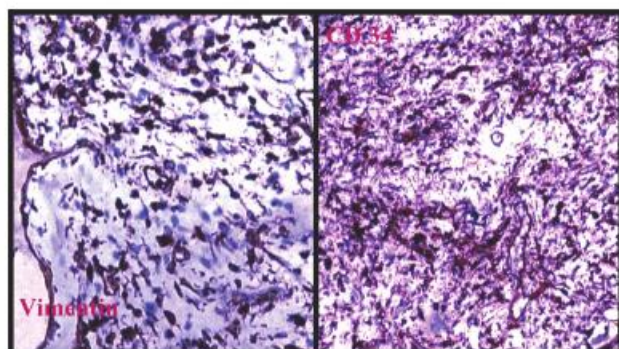


Figure 2. IHC sections that are vimentin and CD 34 positive.

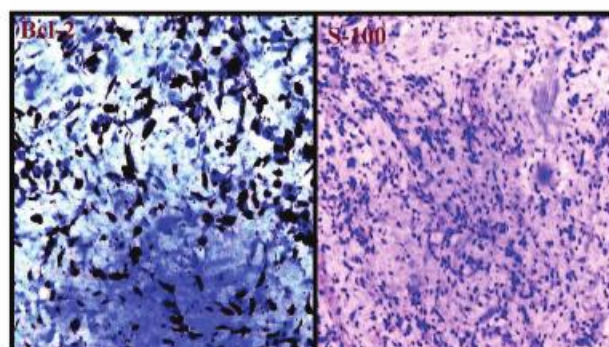


Figure 3. IHC sections that are Bcl-2 positive and S-100 negative.

in SFT. This has helped in differentiating schwannoma from SFT in our case. Dermatofibrosarcoma protuberans can display CD34 reactivity but the pattern of growth and collagen deposition is different and shows more mitotic activity, which we have not observed in this case. To differentiate between SFT and HPC, Gengler and Guillou have stated that most tumors in the past identified as HPC do not derive from pericytes but, instead, constitute a cellular variant of SFT. Thus, it was suggested to utilize the idiom “cellular SFT” to describe the nonpericytic HPCs and “fibrous SFT” to refer to the classic SFT.

IHC plays an important role in distinguishing SFT from this wide range of differentials. The tumor cells typically show positive staining for vimentin, CD34, Bcl-2, and CD99, with negative staining for cytokeratin, EMA, CAM5.2, SMA, desmin, GFAP, CD117, muscle-specific actin, and S-100 protein. The presence of EMA, any keratin or S-100 protein will rule out many common salivary gland tumors such as pleomorphic adenoma. CD34 is a hematopoietic progenitor cell antigen that is strongly positive in

most cases of SFT, though it may not be positive in all cases.¹² CD34 tends to reduce reactivity in malignant SFT when compared to benign tumors.⁴ The majority of carcinomas, melanomas, and lymphomas are negative for CD34. On the basis of strong CD34, Bcl-2, vimentin, and CD99 positivity in our case, we have made a final diagnosis of SFT of the parotid.

Complete local surgical excision with negative microscopic margins is the single most important prognostic factor in SFT. Some authors have documented disease recurrence at other extrapleural sites decades after initial identification of the primary tumor. For this reason, close long-term follow up is recommended.¹³ Patients who have undergone complete tumor resection showed 100% survival at a mean 1.9 years of follow-up.¹⁴ Tumors that cannot be completely excised or which show malignant histological features may respond to radiation and/or chemotherapy.¹¹ Predicting the clinical behavior of SFT remains a challenging clinicopathological problem. Demicco et al. have found that patient age (≥ 55 years), tumor size (> 15 cm), and mitotic activity (≥ 4 per

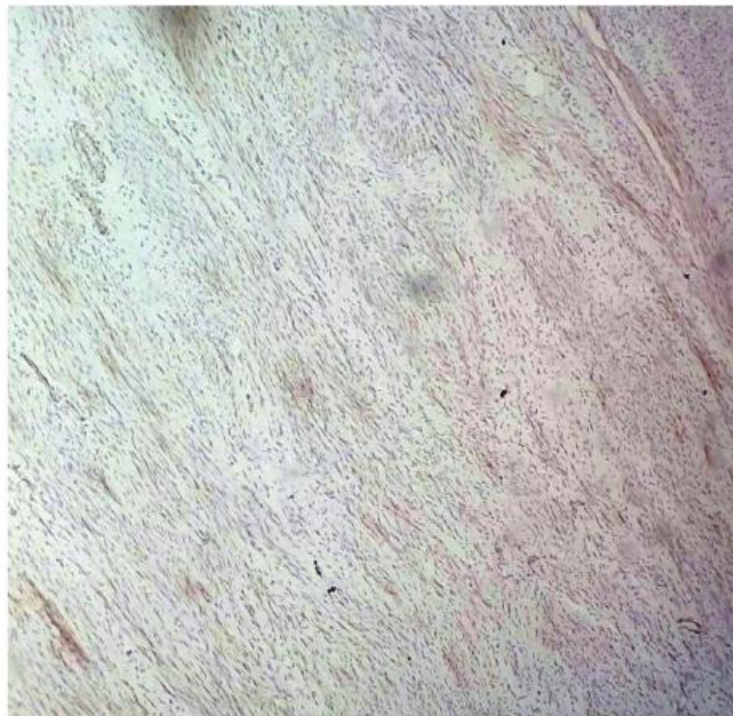

Figure 4. IHC that shows cells negative for desmin (200 \times).

10 HPF) predict the development of SFT metastasis and have devised a risk stratification model that may be clinically useful.^{15,16}

Conclusion

Solitary fibrous tumor is a rare tumor of mesenchymal origin seen in the parotid gland. It should be considered in the differential diagnosis of benign spindle cell tumors in various serosal and extraserosal locations. It has to be differentiated from a wide range of spindle cell lesions; hence, a combination of histological features and IHC is useful. Surgery is the treatment of choice. Due to the unknown prognosis owing to the limited number of cases reported, long-term follow-up is recommended.

Authors' Contribution

All the six authors have contributed to the concept, literature search, data acquisition, data analysis, manuscript editing and review.

Conflict of Interest

No conflict of interest is declared.

References

1. Klemperer P, Coleman BR. Primary neoplasms of the pleura. A report of five cases. *Am J Ind Med.* 1992;22(1):1-31.
2. Gold JS, Antonescu CR, Hajdu C, Ferrone CR, Hussain M, Lewis JJ, et al. Clinicopathologic correlates of solitary fibrous tumors. *Cancer.* 2002;94(4):1057-68.
3. Yu R, Rebello R. Solitary fibrous tumor of the parotid gland: A case report. *Iran J Otorhinolaryngol.* 2015;27(82):401-5.
4. Alonso-Rodríguez E, González-Otero T, Castro-Calvo A, Ruiz-Bravo E, BURGUEÑO M. Parotid gland solitary fibrous tumor with mandibular bone destruction and aggressive behavior. *J Clin Exp Dent.* 2014;6(3):e299-302.
5. Chis O, Albu S. Giant solitary fibrous tumor of the parotid gland. *Case Rep Med.* 2014;2014:950712.
6. Bauer JL, Miklos AZ, Thompson LD. Parotid gland solitary fibrous tumor: a case report and clinicopathologic review of 22 cases from the literature. *Head Neck Pathol.* 2012;6(1):21-31.
7. Messa-Botero OA, Romero-Rojas AE, Chinchilla Olaya SI, Díaz-Pérez JA, Tapias-Vargas LF. Primary malignant solitary fibrous tumor/hemangiopericytoma of the parotid gland. [Article in Spanish] *Acta Otorrinolaringol Esp.* 2011;62(3):242-5.
8. SuárezRoamde L, Ruíz Godoy Rivera LM, Meneses García A, Granados-García M, Mosqueda Taylor A. Solitary fibrous tumor of the parotid region. Report of a case and review of the literature. [Article in English, Spanish] *Med Oral.* 2004;9(1):82-8.
9. Liu Y, Tao X, Shi H, Li K. MRI findings of solitary fibrous tumours in the head and neck region. *Dentomaxillofac Radiol.* 2014;43(3):20130415.
10. Sousa AA, Souto GR, Sousa IA, Mesquita RA, Gomez RS, Jham BC. Solitary fibrous tumor of the parotid gland: Case report. *J Clin Exp Dent.* 2013;5(4):e208-11.
11. Gengler C, Guillou L. Solitary fibrous tumour and haemangiopericytoma: evolution of a concept. *Histopathology.* 2006;48(1):63-74.
12. Brunnemann RB, Ro JY, Ordonez NG, Mooney J, El-Naggar AK, Ayala AG. Extrapleural solitary fibrous tumor: a clinicopathologic study of 24 cases. *Mod Pathol.* 1999;12(11):1034-42.
13. Gold JS, Antonescu CR, Hajdu C, Ferrone CR, Hussain M, Lewis JJ, et al. Clinicopathologic correlates of solitary fibrous tumors. *Cancer.* 2002;94(4):1057-68.
14. Mohammed K, Harbourne G, Walsh M, Royston D. Solitary fibrous tumour of the parotid gland. *J Laryngol Otol.* 2001;115(10):831-2.
15. Witkin GB, Rosai J. Solitary fibrous tumor of the upper respiratory tract. A report of six cases. *Am J Surg Pathol.* 1991;15(9):842-8.
16. Demicco EG, Park MS, Araujo DM, Fox PS, Bassett RL, Pollock RE, et al. Solitary fibrous tumor: a clinicopathological study of 110 cases and proposed risk assessment model. *Mod Pathol.* 2012;25(9):1298-306.