

## Can Clinical Presentation and Ultrasonography Predict the Risk of Malignancy in Thyroid Nodules?

Zahra Davoudi\*, Arezoo Chouhdari\*\*,\*\*\*,  
Hooman Bahrami-Motlagh\*\*\*\*, Karim Bagheri\*

\*Endocrinology Department, Loghman Hakim Hospital, Shahid Beheshti University of Medical Sciences, Tehran, Iran

\*\*Skull Base Research Center, Loghman Hakim Medical Center, Shahid Beheshti University of Medical Sciences, Tehran, Iran

\*\*\*Clinical Research Development Center, Loghman Hakim Hospital, Shahid Beheshti University of Medical Sciences, Tehran, Iran

\*\*\*\*Radiology Department, Loghman Hakim Hospital, Shahid Beheshti University of Medical Sciences, Tehran, Iran

### Abstract

**Background:** Thyroid nodules are frequent occurrences. This study aims to evaluate the risk of malignancy based on the 2015 American Thyroid Association Management: Guidelines for Adult Patients with Thyroid Nodules and Differentiated Thyroid Cancer.

**Methods:** In this cross-sectional study, ultrasonography and clinical manifestations were compared with pathology findings to predict the risk of malignancy in thyroid nodules. Assessment of the ultrasound findings was based on the criteria recommended by The 2015 American Thyroid Association Management Guidelines for Thyroid Nodules. For the evaluation of the association between clinical and ultrasound findings with histopathology results, we used the chi-square and Fisher's exact tests. The relative risk and prediction of malignancy was assessed by multiple logistic regression analysis. Data analysis was performed by the SPSS19. The significance level was set at  $P < 0.05$ .

**Results:** From 130 patients with thyroid nodules, 110 (84.6%) were female. The mean age of participants was  $46.1 \pm 11.5$  years. Histopathology findings showed malignancy in 17.7% of the nodules, all of were papillary thyroid carcinoma. Multivariate logistic regression showed some of the ultrasonography parameters, absence of halo ( $P < 0.001$ , OR=28), taller than wide shape ( $P = 0.001$ , OR=18.3), nodule size more than 4 cm ( $P = 0.04$ , OR=12.1), irregular margin ( $P = 0.001$ , OR=10.06), solid or mixed composition ( $P = 0.002$ , OR=8.1), hypoechoic ( $P = 0.001$ , OR=4.5), lymph node positive ( $P = 0.002$ , OR=4.3), positive calcification ( $P = 0.03$ , OR=2.08), positive internal vascularity ( $P < 0.001$ , OR=1.05), and intermediate/high level of suspicion ( $P = 0.001$ , OR=12) could predict malignancy in patients with thyroid nodules.

**Conclusion:** Based on increasing rate of thyroid cancer, in this study, the new and accurate ultrasound technique is recommended as alternative diagnostic method due non-invasive nature and lower cost used.

**Keywords:** Thyroid nodules, Clinical presentation, Ultrasonography, Malignancy, Pathology

#### Corresponding Author:

Hooman Bahrami-Motlagh, MD  
Imaging Department, Loghman Hakim Hospital, Makhsus Ave.,  
Lashkar cross, South Kargar,  
Tehran, Iran Postal code:  
1333631151  
Tel: +98-9125123198  
Email: HoomanBahrami@gmail.com

## Introduction

Thyroid nodules are a common medical problem in the general population with a prevalence of 10%-70%. Women are more frequently diagnosed, in addition to individuals older than 40 years of age and those with a positive family history of thyroid diseases.<sup>1-4</sup> Thyroid cancer is found in 5%–15% of cases and depends on sex, age, and exposure to other risk factors. The increased use of thyroid, head and neck ultrasound has led to increased diagnosis of asymptomatic thyroid nodules and faster detection of thyroid cancer in adults.<sup>5</sup> Age, positive family history, previous head and neck X-ray, and ultrasound parameters such as microcalcifications, absence of a halo, increased intranodal vascularity, hypoechogenicity, tall shape of a nodule or irregular margins are traditionally associated with increased risk of malignancy in thyroid nodules. However, none of these parameters is sufficient and reliable to detect malignancy in these cases. Only aspiration and pathology results are considered definitive criteria for diagnosis by the physician. Some studies have reported diagnostic sensitivity ranges from 26.5%-87.1% for hypoechogenicity,

54.3%-74.2% for intranodal vascularity, and 26.1%-59.1% for microcalcifications. Specificity ranges were 43.4%-94.3% for hypoechogenicity, 78.6%-80.8% for intranodal vascularity, and 85.5%-95% for microcalcifications.<sup>6,7</sup> Recently, determination of tissue elasticity by ultrasound (elastography) has been proposed to detect malignancy in thyroid nodules.<sup>8</sup> Considering the uncertainty of clinical findings and ultrasound in benign and malignant differentiation in detected thyroid nodules, the aim in this study is to investigate the relationship between clinical manifestation and ultrasound characteristics with pathologic confirmation of malignancy.

## Materials and Methods

In this cross-sectional study, 130 cases of thyroid nodules larger than 1 cm were selected by convenient sampling method from patients who presented to the Endocrinology Ward at Lohman Hakim Hospital, a tertiary university medical center in Tehran, Iran in 2017. Patients were referred by endocrinologists, otolaryngologists, or surgeons in the same hospital due to clinical suspicion of thyroid nodules. We used a data

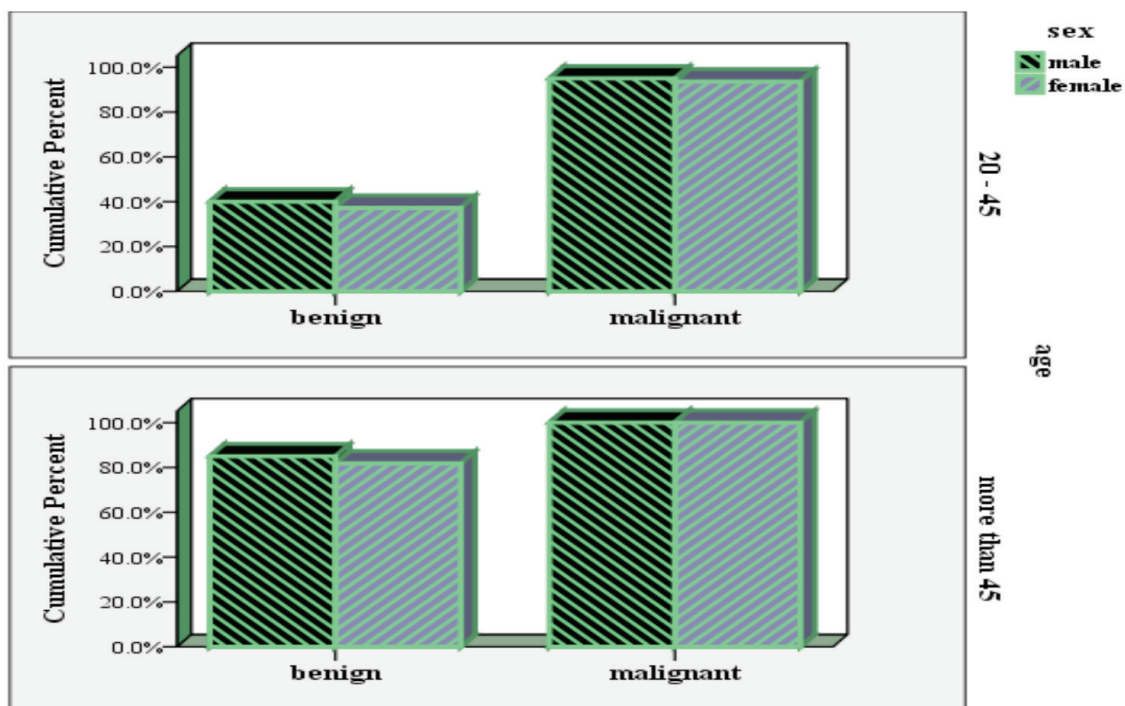


Figure 1. Type of thyroid nodules (pathology finding) based on age and sex.

**Table 1.** The risk for malignancy according to the ultrasound criteria in the 2015 American Thyroid Association Management Guidelines.

Level of suspicion	Shape	Echogenic foci	Margin	Composition	Echogenicity
High suspicion	Taller than wide	Micro calcifications rim calcifications	Irregular, lobulated Extra thyroidal extension	Solid or partially cystic	Hypoechoic
Intermediate suspicion	Not taller than wide	Without micro calcifications	Smooth	Solid	Hypoechoic
Low suspicion	Not taller than wide	Without micro calcifications	Smooth	Solid or partially cystic with eccentric solid areas	Iso/hyperechoic
Very low suspicion	Not taller than wide	Without micro calcifications	Smooth		
Benign	Not taller than wide	Without micro calcifications	Smooth	Spongiform or Partially Cystic Purely cystic	Iso/hyperechoic Anechoic

collection form to gather patients' demographic information such as age, sex, family history, previous thyroid diseases, clinical manifestations (pain, dysphonia, and other findings), and laboratory analyses (Thyroid Stimulating Hormone (TSH), Anti-thyroid peroxidase Antibody (anti-TPO antibody)). Nodules greater than 1 cm were aspirated under ultrasound-guided fine needle aspiration (FNA). A single radiologist performed the ultrasonography with a superficial probe (8-12 Hz) and the FNA. Next, we assessed the relationship between clinical manifestation and ultrasound findings with pathology characteristics for malignancy. Thyroid nodules were assessed according to the criteria from the 2015 American Thyroid Association Management: Guidelines for Adult Patients with Thyroid Nodules and Differentiated Thyroid Cancer and, based on the aggregated ultrasound parameters, each nodule was assigned a level of suspicion for malignancy (Table 1).<sup>9</sup> All patients provided their oral consent to participate in the study. The Ethical Committee of Shahid Beheshti University of Medical Sciences, Tehran, Iran approved this study.

### Statistical analysis

Mean  $\pm$  standard deviation values were used for descriptive results. Qualitative data were recorded as numbers and percents. The chi-square and

Fisher's exact tests were used to evaluate the association between variables. Finally, multivariate logistic regression was used to predict the possible factors for malignancy in the thyroid nodules. We used the Statistical Package for the Social Sciences, version 19 for total analysis.  $P < 0.05$  was considered significant for all tests.

### Results

Out of the 130 cases with one or multiple thyroid nodules at Loghman Hakim Hospital, 110 (84.6%) were female. The mean age was  $46.1 \pm 11.5$  years. All 23 (17.7%) discovered malignant thyroid nodules were papillary thyroid carcinoma (PTC) and there were 107 (82.3%) benign cases. None of the patients mentioned any history of radiotherapy or radiation exposure. Among 23 malignant thyroid nodules, 20 of the nodules were in females. Figure 1 shows that the relative frequency of malignancy was almost equal in both sexes (18% females and 15% males).

We observed an association between pathology findings (malignant/benign) and pain ( $P = 0.04$ ), dysphonia ( $P = 0.001$ ), and family history of cancer ( $P = 0.001$ ) as demographic characteristics, in addition to nodule size  $\geq 4$  cm ( $P < 0.001$ ), hypoechogenicity ( $P < 0.001$ ), microcalcifications ( $P < 0.001$ ), irregular margins ( $P < 0.001$ ), absence of the halo sign ( $P < 0.001$ ), taller than wide shape ( $P < 0.001$ ), positive internal vascularity ( $P < 0.001$ ),

**Table 2.** Association between demographic, clinical manifestation, ultrasound, and laboratory tests with pathology results of patients with thyroid nodules (univariate analysis).

Variables	Pathology		P-value	Variables	Pathology		P-value
	Benign	Malignant			Benign	Malignant	
	Number (%)			Number (%)			
<b>Age (years)</b>			0.09	<b>Echogenicity</b>			<0.001 *
20-45	49 (45.8)	15 (65.2)		Hypoechoic	21 (19.6)	23 (100)	
>45	58 (54.2)	8 (34.8)		Hyper/iso/mixed	86 (80.4)	0 (0)	
<b>Sex</b>			0.7	<b>Calcification</b>			<0.001 *
Male	17 (15.9)	3 (13)		Micro	3 (2.8)	15 (65.2)	
Female	90 (84.1)	20 (87)		Macro	22 (20.6)	2 (8.7)	
				None	82 (76.6)	6 (26.1)	
<b>Pain</b>			0.04 *	<b>Margin</b>			<0.001 *
Yes	28 (26.2)	11 (47.8)		Regular	102 (95.3)	4 (17.4)	
No	79 (73.8)	12 (52.2)		Irregular	5 (4.7)	19 (82.6)	
<b>Dysphonia</b>			0.001 *	<b>Halo</b>			<0.001 *
Yes	23 (21.5)	17 (73.9)		Yes	104 (97.2)	4 (17.4)	
No	84 (78.5)	6 (26.1)		No	3 (2.8)	19 (82.6)	
<b>Family history of thyroid cancer</b>			0.001 *	<b>Shape</b>			<0.001 *
Yes	3 (2.8)	7 (30.4)		Taller than wide	1 (0.9)	8 (34.8)	
No	104 (97.2)	16 (69.6)		Not taller than wide	106 (99.1)	15 (65.2)	
<b>Size (cm)</b>			<0.001 *	<b>Lymph nodes</b>			<0.001 *
1-2	54 (50.5)	5 (21.7)		Yes	32 (29.9)	15 (65.2)	
2-4	44 (41.1)	9 (39.1)		No	75 (70.1)	8 (34.8)	
>4	9 (8.4)	9 (39.1)		<b>Level of suspicion</b>			<0.001 *
<b>Composition</b>			0.002 *	Very low/low	96 (89.7)	1 (4.3)	
Solid	50 (46.7)	20 (87)		Intermediate/high	11 (10.3)	22 (95.7)	
Cystic/spongiform	9 (8.4)	0 (0)		<b>TSH</b>			0.08
Mixed	48 (44.9)	3 (13)		<0.5 or >4	11 (64.7)	96 (85)	
<b>Internal vascularity</b>			<0.001 *	0.5-4	6 (35.3)	17 (15)	
Yes	14 (13.1)	17 (73.9)		<b>Anti-TPO</b>			0.03 *
No	93 (86.9)	6 (26.1)		Yes	33 (30.8)	2 (5.7)	
				No	74 (69.2)	21 (91.3)	

\*: Indicates statistical significance.

positive lymph nodes ( $P<0.001$ ), and solid composition ( $P=0.002$ ) in ultrasonography parameters. We observed that 95.7% of the cases were considered malignant according to pathology and were also intermediate and high grade according to ultrasound findings. A significant association existed between anti-TPO and pathology findings ( $P=0.03$ ). Thus, 91.3% of the malignant nodules were negative for anti-TPO (Table 2). Multiple logistic regression analysis predictive factors for malignancy in patients with thyroid nodules according to ultrasound parameters included: absent halo sign ( $P<0.001$ ; OR=28; 95% CI: 16.3-36), taller than wide shape ( $P=0.001$ ; OR=18.3; 95% CI: 5.2-25.5), nodule size > 4 cm ( $P=0.04$ ; OR=12.1; 95% CI: 3.2-18), irregular margins ( $P=0.001$ ; OR=10.06; 95% CI:

1.9-15.5), solid or mixed composition ( $P=0.002$ ; OR=8.1; 95% CI: 3.5-12.6), hypoechoic ( $P=0.001$ ; OR=4.5; 95% CI: 2.2-16.1), lymph node ( $P=0.002$ ; OR=4.3; 95% CI: 1.6-11.3), calcification ( $P=0.03$ ; OR=2.08; 95% CI: 1.12-10.5), internal vascularity ( $P<0.001$ ; OR=1.05; 95% CI: 3.2-20.05), and intermediate/high level of suspicion ( $P=0.001$ ; OR=12; 95% CI: 6.5-25) as seen in Table 3.

## Discussion

We assessed 130 thyroid nodules in patients who presented to the Endocrinology Department of Loghman Hakim Hospital in 2017. From these, 23 (17.7%) were malignant PTC.

Thyroid cancer is the most common thyroid malignancy, which is increasing.<sup>10,11</sup> The reasons

**Table 3.** Prediction of malignancy in patients with thyroid nodules (multiple logistic regression).

Variables	OR (95% CI)	P-value
<b>Size</b>	12.1 (3.2-18)	0.04
>4		
≤4 (reference)		
<b>Halo</b>	28 (16.3-36)	<0.001
No		
Yes (reference)		
<b>Shape</b>	18.3 (5.2-25.5)	0.001
Taller than wide		
Not taller than wide (reference)		
<b>Internal vascularity</b>	1.05 (3.2-20.05)	<0.001
Yes		
No (reference)		
<b>Calcification</b>	2.08 (1.12-10.5)	0.03
Yes		
No (reference)		
<b>Composition</b>	8.1 (3.5-12.6)	0.002
Solid		
Mixed		
Cystic/spongiform (reference)		
<b>Echogenicity</b>	4.5 (2.2-16.1)	0.001
Hypoechoic		
Hyper/iso/mixed (reference)		
<b>Margin</b>	10.06 (1.9-15.5)	0.001
Irregular		
Regular (reference)		
<b>Lymph nodes</b>	4.3 (1.6-11.3)	0.002
Yes		
No (reference)		
<b>Level of suspicion</b>	12 (6.5-25)	0.001
Intermediate/high		
Very low/low (reference)		

for the increased incidence rate can be attributed to improved diagnostic methods and changes in risk factors.<sup>12,13</sup> According to a number of studies, approximately 5%-15% of thyroid nodules are malignant;<sup>14,15</sup> however, the prevalence of this cancer is increasing in the United States and most industrialized countries.<sup>16</sup> In the current study, the presence of surgical, ENT, and endocrinology clinics in one location and their collaboration

could increase the referral of patients with thyroid nodules to the thyroid clinic and account for an increased incidence in additional malignancies. Concern expressed by first-degree relatives of patients about thyroid cancer might have caused an increase in referrals to physicians for diagnostic measures and increase the incidence of thyroid cancer. The results indicated that pain, dysphonia, and positive family thyroid cancer history were associated with malignant thyroid nodules. None



of the patients had a history of radiotherapy. In other studies, clinical manifestations suggestive of malignant nodules included age below 20 and over 60 years, male gender, radiotherapy history, rapid growth of the nodule, changes in speaking and swallowing, as well as a family history of thyroid cancer and related syndromes.<sup>17</sup> We did not observe any difference between gender and malignancy in the thyroid nodules as in the recent study by Hegedüs et al.<sup>18</sup> None of the cases were less than 20 years of age. A comparison of patients less or equal to 45 years of age with those older than 45 years showed no significant difference in the number of benign or malignant nodules, as in a study by Abu-Ghanem et al. in Israel.<sup>19</sup> which is similar to our survey, evaluated the relationship between clinical manifestations and sonography for FNA in terms of malignant risk. They pointed clinical presentation and sonography findings could not predict malignant or benign nodules.<sup>19</sup> In this study, size greater than 4 cm had a significant association with thyroid malignancy, which was similar to other studies in this area.<sup>20,21</sup> Recently, Papini et al. conducted a study in Italy and reported that no significant relationship existed between larger non-palpable nodules and increased risk of thyroid malignancy<sup>23</sup> similar to another study.<sup>24</sup> In some studies, higher TSH levels increased thyroid cancer risk; whereas, there was not a significant association between malignant nodules and TSH.<sup>25,26</sup> There was a significant association between negative anti-TPO and thyroid nodule malignancy; 91.3% malignant nodules were negative for anti-TPO. This indicated an association of benign thyroid disease with positive anti-TPO levels. In the current study, all patients with thyroid nodules greater than 1 cm underwent FNA. However, according to the ATA 2015 guidelines, FNA should be performed on patients who have intermediate and high-risk thyroid nodules that are 1 cm and more in size.<sup>27</sup> According to ultrasound results in other studies, the highest specificity for thyroid cancer in the nodules is the presence of microcalcifications, hypoechoic appearances in the parenchyma, and irregular margins.<sup>28-30</sup> In the current study, the

lowest OR in positive findings was related to internal vascularity, which supported the results of a study by Moon HJ et al.<sup>31</sup> In the current study, there was a significant association between pathology findings and level of suspicion according to sonography results. Hence, 95.7% of patients who had features of malignancy according to their pathology results had intermediate or high-level suspicions of cancer. Hypoechoic appearance, microcalcifications, irregular margins, vascularity, absence of a halo, taller than wide, positive lymph nodes, and solid composition according to sonography results were significant for thyroid nodules associated with malignancy (Univariate analysis). In addition to assessing the aggregated ultrasound features, our study predicted malignancy. We found that absence of halo and taller than wide had the most pronounced effect of any of the predictors examined in the course of this study. The second solitary ultrasound predictor of malignancy was irregular margins and solid or predominantly solid composition, which supported much of the literature.<sup>29-32</sup> The absence of halo facing has been considered in the older literature; whereas, taller than wide manifestation is known as a high-risk nodule pattern in the new ATA criteria.<sup>33,34</sup> In this study, different features of echogenic foci, the radiologist's opinion, and quality of the ultrasound device might indicate a lower OR for microcalcifications. Therefore, it is better to exclude patients with inadequate imaging from the study. The small sample size is a major limitation of our analysis because of the low numbers of malignant cases.

## Conclusion

Based on the results of this study, there is an increasing incidence of thyroid cancer in thyroid nodules. Despite the small sample size, we have found a significant association between clinical and ultrasound findings with FNA of malignant nodules, especially with the absence of a halo, taller than wide, the appearance and severity of the solid composition, and irregular margins. We recommend more studies to be conducted according to ATA2015 criteria and enroll larger

sample sizes. These studies should perform FNA of the thyroid nodules and genetic studies on malignant nodules, especially in cases that have positive family history, which could generalize results of this study to the 2015 American Thyroid Association Management Guideline.

### Acknowledgment

The authors would like to thank the Clinical Research Development Center (CRDC) of Loghman Hakim Hospital, Shahid Beheshti University of Medical Sciences, Tehran, Iran for their support, cooperation, and assistance throughout this study.

### Conflict of Interest

None declared.

### References

1. Remonti LR, Kramer CK, Leitão CB, Pinto LC, Gross JL. Thyroid ultrasound features and risk of carcinoma: a systematic review and meta-analysis of observational studies. *Thyroid*. 2015;25(5):538-50. doi: 10.1089/thy.2014.0353.
2. Rezaei-Delui H, Davachi B, Rahroh M. Incidence of ultrasonographically-detected thyroid nodules in persons between 10-70 years with no previous thyroid disease. *Iran J Otorhinolaryngol*. 2004;16(3):7-13.
3. Wong KT, Ahuja AT. Ultrasound of thyroid cancer. *Cancer Imaging*. 2005;5:157-66.
4. Siadati S, Moazezi Z, Bayani MA, Mirzapour A, Nikbaksh N, Ghaemian N, et al. The diagnostic value of fine needle aspiration as compared to pathology results in diagnosis of thyroid nodules: A 22-year follow-up study. *J Babol Univ Med Sci*. 2015;17(9):39-43.
5. Smith-Bindman R, Lebda P, Feldstein VA, Sellami D, Goldstein RB, Brasic N, et al. Risk of thyroid cancer based on thyroid ultrasound imaging characteristics: results of a population-based study. *JAMA Intern Med*. 2013;173(19):1788-96. doi: 10.1001/jamainternmed.2013.9245.
6. Remonti LR, Kramer CK, Leitão CB, Pinto LC, Gross JL. Thyroid ultrasound features and risk of carcinoma: a systematic review and meta-analysis of observational studies. *Thyroid*. 2015;25(5):538-50. doi: 10.1089/thy.2014.0353.
7. Rago T, Scutari M, Santini F, Loiacono V, Piaggi P, Di Coscio G, et al. Real-time elastosonography: useful tool for refining the presurgical diagnosis in thyroid nodules with indeterminate or nondiagnostic cytology. *J Clin Endocrinol Metab*. 2010;95(12):5274-80. doi: 10.1210/jc.2010-0901.
8. Gharib H, Papini E, Garber JR, Duick DS, Harrell RM, Hegedüs L, et al. American Association of Clinical Endocrinologists, American College of Endocrinology, and Associazione Medici Endocrinologi Medical Guidelines for clinical practice for the diagnosis and management of thyroid nodules--2016 Update. *Endocr Pract*. 2016;22(5):622-39. doi: 10.4158/EP161208.GL.
9. Haugen BR, Sawka AM, Alexander EK, Bible KC, Caturegli P, Doherty GM, et al. American Thyroid Association guidelines on the management of thyroid nodules and differentiated thyroid cancer task force review and recommendation on the proposed renaming of Encapsulated Follicular Variant Papillary Thyroid Carcinoma without invasion to Noninvasive Follicular Thyroid Neoplasm with Papillary-Like Nuclear Features. *Thyroid*. 2017;27(4):481-3. doi: 10.1089/thy.2016.0628.
10. Castro MR, Gharib H. Thyroid fine-needle aspiration biopsy: progress, practice, and pitfalls. *Endocr Pract*. 2003;9(2):128-36.
11. Ferlay J, Steliarova-Foucher E, Lortet-Tieulent J, Rosso S, Coebergh JW, Comber H, et al. Cancer incidence and mortality patterns in Europe: estimates for 40 countries in 2012. *Eur J Cancer*. 2013;49(6):1374-403. doi: 10.1016/j.ejca.2012.12.027.
12. Pellegriti G, Frasca F, Regalbuto C, Squatrito S, Vigneri R. Worldwide increasing incidence of thyroid cancer: update on epidemiology and risk factors. *J Cancer Epidemiol*. 2013;2013:965212. doi: 10.1155/2013/965212.
13. Davies L. How understanding thyroid cancer in Belgium can help us mitigate the problem of increasing incidence. *J Clin Endocrinol Metab*. 2013;98(10):3977-9. doi: 10.1210/jc.2013-3505.
14. Pathak KA, Leslie WD, Klonisch TC, Nason RW. The changing face of thyroid cancer in a population-based cohort. *Cancer Med*. 2013;2(4):537-44. doi: 10.1002/cam4.103.
15. Yassa L, Cibas ES, Benson CB, Frates MC, Doubilet PM, Gawande AA, et al. Long-term assessment of a multidisciplinary approach to thyroid nodule diagnostic evaluation. *Cancer*. 2007;111(6):508-16.
16. Wang CC, Friedman L, Kennedy GC, Wang H, Kebebew E, Steward DL, et al. A large multicenter correlation study of thyroid nodule cytopathology and histopathology. *Thyroid*. 2011;21(3):243-51. doi: 10.1089/thy.2010.0243.
17. Davies L, Welch HG. Current thyroid cancer trends in the United States. *JAMA Otolaryngol Head Neck Surg*. 2014;140(4):317-22. doi: 10.1001/jamaoto.2014.1.
18. Hegedüs L, Bonnema SJ, Bennedbaek FN. Management of simple nodular goiter: current status and future perspectives. *Endocr Rev*. 2003;24(1):102-32.
19. Abu-Ghanem S, Cohen O, Lazutkin A, Abu-Ghanem

- Y, Fliss DM, Yehuda M. Evaluation of clinical presentation and referral indications for ultrasound-guided fine-needle aspiration biopsy of the thyroid as possible predictors of thyroid cancer. *Head Neck*. 2016;38 Suppl 1:E991-5. doi: 10.1002/hed.24143.
20. Espinosa De Ycaza AE, Lowe KM, Dean DS, Castro MR, Fatourechi V, Ryder M, et al. Risk of malignancy in thyroid nodules with non-diagnostic fine-needle aspiration: a retrospective cohort study. *Thyroid*. 2016;26(11):1598-604.
  21. McCoy KL, Jabbour N, Ogilvie JB, Ohori NP, Carty SE, Yim JH. The incidence of cancer and rate of false-negative cytology in thyroid nodules greater than or equal to 4 cm in size. *Surgery*. 2007;142(6):837-44; discussion 844.e1-3.
  22. Campanella P, Ianni F, Rota CA, Corsello SM, Pontecorvi A. Quantification of cancer risk of each clinical and ultrasonographic suspicious feature of thyroid nodules: a systematic review and meta-analysis. *Eur J Endocrinol*. 2014;170(5):R203-11. doi: 10.1530/EJE-13-0995.
  23. Papini E, Guglielmi R, Bianchini A, Crescenzi A, Taccogna S, Nardi F, et al. Risk of malignancy in nonpalpable thyroid nodules: predictive value of ultrasound and color-Doppler features. *J Clin Endocrinol Metab*. 2002;87(5):1941-6.
  24. Alexander EK, Hurwitz S, Heering JP, Benson CB, Frates MC, Doubilet PM, et al. Natural history of benign solid and cystic thyroid nodules. *Ann Intern Med*. 2003;138(4):315-8.
  25. Frates MC, Benson CB, Doubilet PM, Kunreuther E, Contreras M, Cibas ES, et al. Prevalence and distribution of carcinoma in patients with solitary and multiple thyroid nodules on sonography. *J Clin Endocrinol Metab*. 2006;91(9):3411-7.
  26. Boelaert K, Horacek J, Holder RL, Watkinson JC, Sheppard MC, Franklyn JA. Serum thyrotropin concentration as a novel predictor of malignancy in thyroid nodules investigated by fine-needle aspiration. *J Clin Endocrinol Metab*. 2006;91(11):4295-301.
  27. Haymart MR, Repplinger DJ, Levenson GE, Elson DF, Sippel RS, Jaume JC, et al. Higher serum thyroid stimulating hormone level in thyroid nodule patients is associated with greater risks of differentiated thyroid cancer and advanced tumor stage. *J Clin Endocrinol Metab*. 2008;93(3):809-14.
  28. Haugen BR, Alexander EK, Bible KC, Doherty GM, Mandel SJ, Nikiforov YE, et al. 2015 American Thyroid Association Management guidelines for adult patients with thyroid nodules and differentiated thyroid cancer: The American Thyroid Association guidelines task force on thyroid nodules and differentiated thyroid cancer. *Thyroid*. 2016;26(1):1-133. doi: 10.1089/thy.2015.0020.
  29. Kwak JY, Han KH, Yoon JH, Moon HJ, Son EJ, Park SH, et al. Thyroid imaging reporting and data system for US features of nodules: a step in establishing better stratification of cancer risk. *Radiology*. 2011;260(3):892-9. doi: 10.1148/radiol.11110206.
  30. Moon WJ, Jung SL, Lee JH, Na DG, Baek JH, Lee YH, et al. Benign and malignant thyroid nodules: US differentiation--multicenter retrospective study. *Radiology*. 2008;247(3):762-70. doi: 10.1148/radiol.2473070944.
  31. Moon HJ, Kwak JY, Kim MJ, Son EJ, Kim EK. Can vascularity at power Doppler US help predict thyroid malignancy? *Radiology*. 2010;255(1):260-9. doi: 10.1148/radiol.09091284.
  32. Salmaslioglu A, Erbil Y, Dural C, İşsever H, Kapran Y, Ozarmağan S, et al. Predictive value of sonographic features in preoperative evaluation of malignant thyroid nodules in a multinodular goiter. *World J Surg*. 2008;32(9):1948-54. doi: 10.1007/s00268-008-9600-2.
  33. Brito JP, Gionfriddo MR, Al Nofal A, Boehmer KR, Leppin AL, Reading C, et al. The accuracy of thyroid nodule ultrasound to predict thyroid cancer: systematic review and meta-analysis. *J Clin Endocrinol Metab*. 2014;99(4):1253-63. doi: 10.1210/jc.2013-2928.
  34. Reading CC, Charboneau JW, Hay ID, Sebo TJ. Sonography of thyroid nodules: a "classic pattern" diagnostic approach. *Ultrasound Q*. 2005;21(3):157-65.