

## Case Report

Middle East Journal of Cancer; January 2020; 11(1): 105-108

# A Surprise Visitor at Cesarean Section: Gastrointestinal Stromal Tumor of the Uterus

Simon Raif Marcos\*, Bhanu Pratap Singh\*\*, Devesh Sanjeev Ballal\*\*,  
Faris Alaswad\*\*\*, Shakeel Akhtar\*\*\*\*, Gabriel Rodrigues\*\*

\*Department of Obstetrics and Gynecology, NMC Specialty Hospital, Dubai, UAE

\*\*Department of General Surgery, Kasturba Medical College, Manipal Academy of Higher Education, Manipal, India

\*\*\*Department of General Surgery, NMC Specialty Hospital, Dubai, UAE

\*\*\*\*Department of Pathology, NMC Specialty Hospital, Dubai, UAE

## Abstract

Gastrointestinal stromal tumors (GISTs) are rare mesenchymal tumors that almost always arise from the GI tract and account for 0.1-3% of GI tumors. During pregnancy, GIST is highly unusual given the predilection of this tumor to appear in the fifth to seventh decade of life. The finding of GISTs outside the GI tract is also rare as the cell of origin of these tumors is believed to be the interstitial cell of Cajal, found only in the GI tract. Extra intestinal GISTs have been reported with a few cases arising from the uterus or metastatic to the ovary; however, an asymptomatic uterine GIST occurring at pregnancy as an incidental finding during cesarean section has not been reported so far. We present a 32-year-old lady who underwent an emergency caesarean section and was found to have a GIST of the uterus. The tumor was excised in toto and she started imatinib therapy postoperatively. At the end of three years of close follow-up, she has done well with no evidence of recurrence.

**Keywords:** GIST, Tumour, Pregnancy, Excision, Imatinib

## Introduction

Gastrointestinal stromal tumors (GISTs) are the most common mesenchymal tumors of the GI tract that originate from the interstitial cells of Cajal, primarily in the stomach and small intestine.<sup>1</sup> Their morphologies vary from spindle cell to epithelioid and are immunopositive for KIT (CD117) and/or DOG1 in

essentially all cases.<sup>2</sup> The majority of the GISTs though localized at presentation, can be recurrent or metastasized to the liver and their growths are driven by oncogenic mutations in either of two receptor tyrosine kinases: KIT (75% of cases) or PDGFRA (10%).<sup>3,4</sup> Although surgery is the definitive treatment, using tyrosine kinase inhibitors

### \*Corresponding Author:

Gabriel Rodrigues, MS, DNB,  
MNAMS, FRCS  
Department of General Surgery,  
Kasturba Medical College,  
Manipal Academy of Higher  
Education, 576104, Manipal,  
India  
Tel: +919448501301  
Email: gabyrodricks@gmail.com



Received: November 12, 2018; Accepted: July 8, 2019

(TKIs) such as imatinib, sunitinib, and regorafenib are effective in controlling unresectable disease. Adjuvant therapy with imatinib is commonly used to reduce the likelihood of disease recurrence after primary surgery.<sup>5</sup>

### Case report

A full-term 32-year-old Moroccan lady who had her regular antenatal checks done outside and abdominal scan reports that revealed a normally developing fetus in utero, was taken up for an emergency caesarean operation for fatal distress. At operation, a fleshy tumor was found on the anterior uterine surface (Figure 1).

The caesarean operation was uneventful and a normal baby was delivered. Rest of the uterus, ovaries and abdominal cavity (intestine and liver) was normal. The tumor was excised in toto and abdomen closed as usual. Patient made a good postoperative recovery and was discharged. The excised specimen was soft and fleshy and the cut section showed a brownish, vascular spindle like tumor stroma (Figure 2).

Final histopathology revealed a tumor composed of spindle cells arranged in short fascicles and whorls with pale eosinophilic fibrillary cytoplasm, ovoid nuclei, syncytial cell borders and paranuclear vacuolization, findings that were consistent with a diagnosis of uterine GIST (Figure 3A). Immunohistochemistry (IHC) confirmed the diagnosis (Figure 3B and 3C).

The patient was referred to a medical

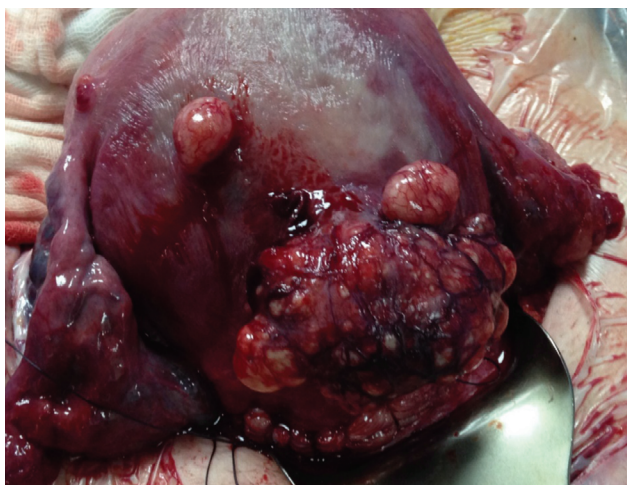
oncologist and the patient oral imatinib was started. She has been kept under close follow-up and at the end of three years the patient was fine.

### Discussion

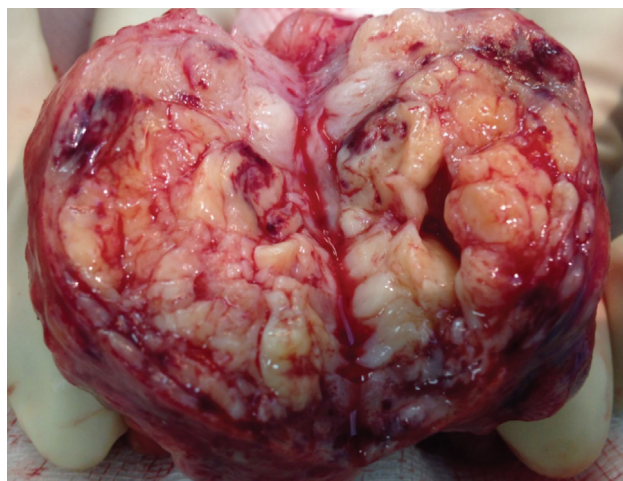
Historically GISTs were thought to be smooth muscles or neuronal tumors. This was disputed due to the lack of IHC markers in other tumors of muscular or neural origins. The term GIST was introduced in 1983, when Mazur and Clark described a series of nonepithelial spindle cell neoplasms, displaying a wide range of differentiation.<sup>6</sup>

GISTs occur in the intestine, most commonly in the stomach (50-60%), followed by small intestine (20-30%), large bowel (10%), and the esophagus (5%).<sup>1</sup> Only 5% of GISTs occur outside these sites, such as in the mesentery, retroperitoneum or omentum and are thought to arise from Interstitial Cells of Cajal (ICC) and stain positive for CD117/CD34/vimentin.<sup>2</sup> ICC are responsible for peristalsis and are the only cells that exhibit this type of IHC. The cell of origin of extraintestinal GISTs is uncertain as ICC are only found in the intestine. ICC originate from common intestinal mesenchymal precursor cells that also give rise to smooth muscles, explaining the morphological resemblance of GISTs to smooth muscle tumors. In addition, this may explain how GISTs occur outside the bowel.<sup>7</sup>

Virtually all GISTs (94%) stain positive for CD117 and express c-kit receptor tyrosine kinase.



**Figure 1.** Fleshy tumor on the anterior uterine surface.



**Figure 2.** Cut section showing a fleshy, brownish, vascular tumor stroma.

Additionally, mutations in PDGFR  $\alpha$  are described. Both genes for c-kit and PDGFR  $\alpha$  are located on chromosome 4. Moreover, GISTs stain positive for CD34 in 60%-80% and smooth muscle actin in 20%-40% of cases.<sup>4</sup> On the other hand, mesenchymal tumors of the uterus such as leiomyosarcomas rarely express c-kit and may do so only focally (fewer than 5% of cells) and also usually express desmin which is seldom found in GISTs.<sup>8</sup> There are numerous other neoplasms that express CD117 such as melanoma, dermatofibrosarcoma protuberans, liposarcoma, and fibrosarcoma. Likewise, there are other tumors that have similar morphologies; however, do not express the CD117 such as neuronal and muscular tumors. The combination of characteristic histological features and IHC helps to differentiate GISTs from the other tumors.<sup>2, 4</sup>

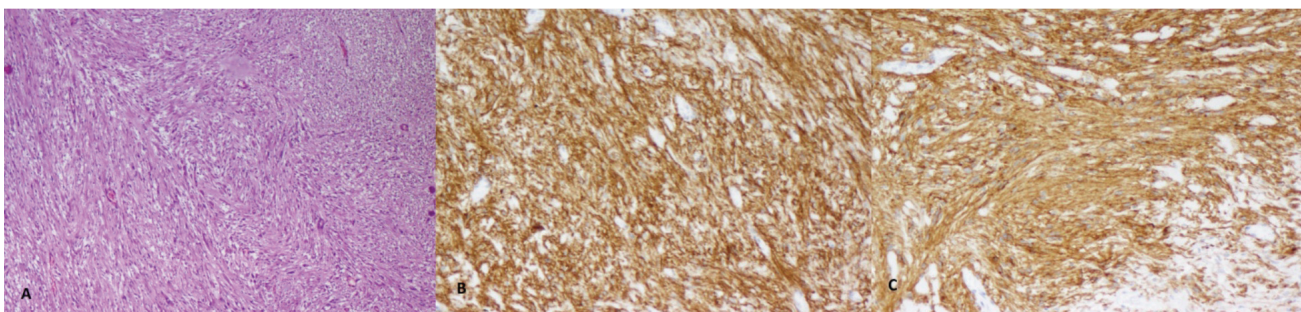
GISTs may be clinically silent, incidentally found on imaging, or may be presented by a varied range of symptoms, depending on site of the tumor. The most dramatic presentation of GISTs is often bleeding which can lead to large amounts of hematemesis, melena, or even frank bleed PR. Intraperitoneal bleed due to tumor rupture is also a known complication.<sup>9</sup>

On Ultrasonography, GISTs appear as well-defined polylobulated masses with predominantly solid component. There may be occasional areas of calcifications, cystic degeneration, or necrosis.<sup>10</sup> Macroscopically, GISTs are grey-white tumors arising from the muscularis. They may grow either endophytically or exophytically and are well-circumscribed unencapsulated tumors. Histologically there are three types of GISTs: spindle cell, epithelioid, and mixed. The older

classification of GISTs into benign or malignant has been abandoned. Currently, GISTs are categorized as per their risk of aggressive behavior into very low-risk, low-risk, intermediate-risk and high-risk based on tumor size and mitotic count. This newer classification is since all GISTs have at least some malignant potential.<sup>11</sup>

The management of GISTs is predominantly surgical. Complete surgical excision is paramount to treatment with incomplete resection and is associated with recurrence and a median survival of less than 20 months. However, wide margins are unnecessary due to minimal local invasion and the rarity of lymph nodal metastasis precludes the need for formal lymphadenectomy.<sup>12</sup> These tumors are not very responsive to conventional chemotherapy. The use of targeted therapy in the form of the TKI imatinib mesylate revolutionized the treatment of GISTs.<sup>5</sup> While is used for unresectable and metastatic disease initially, the use of imatinib has now expanded to all high-risk cases based on tumor size (>5cm), mitotic count (>5/50 hpf), c-kit exon 11 mutations, and tumor rupture during surgery. Imatinib is recommended as per the FDA guidelines for any GIST with high-risk of recurrence for a period of three years.<sup>13</sup> The role of imatinib in the neoadjuvant setting is slightly less clear. Usually, a preoperative course of 6-12 months of imatinib is advocated with frequent assessment of response by imaging.<sup>4</sup> The decision of imatinib continuation length and time of operation must be made for each patient.

Recurrence or metastasis after complete excision is common, occurring in around two third of all GISTs with most recurrences occurring



**Figure 3.** A: Photomicrograph showing a tumor composed of fascicles of spindle cells (H&E, 4 $\times$ ); B: Spindle cells showing immunoreactivity to DOG1 (20 $\times$ ); C: Spindle cells showing immunoreactivity to CD117 (20 $\times$ ).

within the first two years, though cases of recurrence occurring even after 10 years of excision have been reported.<sup>3,4</sup>

## Conclusion

GIST is a common GI tumor and extraintestinal GISTs are reported in the literature. Although a few cases of uterine GISTs and ovarian metastases from GIST have been reported, an asymptomatic uterine GIST occurring at pregnancy as an incidental finding has not been reported so far. Though surgery is the treatment of choice, metastatic tumors are treated with imatinib to decrease the tumor load followed by surgery.

## Informed consent

Written informed consent was obtained from the patient.

## Conflict of Interest

None declared.

## References

1. Goel N, Malik R, Rathi B, Bhaskaran S, Rajaram S, Mehta S, et al. Pregnancy with metastatic gastrointestinal stromal tumor (GIST) on imatinib chemotherapy: an oncologist's nightmare and obstetrician's dilemma. *J Gastrointest Cancer*. 2013;44(1):115-7.
2. Haloob N, Slessor AA, Haloob AR, Khan F, Bostanci G, Abdulla A. An elective combined caesarean section and small bowel GIST resection during the third trimester of pregnancy: Report of a case. *Int J Surg Case Rep*. 2013;4(1):121-4.
3. Igras ET, Fosh BG, Neuhaus SJ. Maternal GIST in twin pregnancy: Case report of a rare and complex management challenge. *Gynecol Oncol Case Rep*. 2012;2(4):133-5.
4. Lanzafame S, Minutolo V, Caltabiano R, Minutolo O, Marino B, Gagliano G, et al. About a case of GIST occurring during pregnancy with immunohistochemical expression of epidermal growth factor receptor and progesterone receptor. *Pathol Res Pract*. 2006;202(2):119-23.
5. Zarkavelis G, Petrakis D, Pavlidis N. Gastrointestinal stromal tumors during pregnancy: a systematic review of an uncommon but treatable malignancy. *Clin Transl Oncol*. 2015;17(10):757-62.
6. Mazur MT, Clark HB. Gastric stromal tumors. Reappraisal of histogenesis. *Am J Surg Pathol*. 1983;7(6):507-19.
7. Takekawa Y, Kimura M, Sakakibara M, Yoshii R, Yamashita Y. Histopathological and cytological findings in a case of gastrointestinal stromal tumor presenting in the pelvic cavity. *Rinsho Byori*. 2007;55(6):535-9.
8. Erdogan G, Bassorgun CI, Pestereli HE, Simsek T, Karaveli S. C-kit protein expression in uterine and ovarian mesenchymal tumours. *APMIS*. 2007;115(3):204-9.
9. Wingen CB, Pauwels PA, Debiec-Rychter M, van Gemert WG, Vos MC. Uterine gastrointestinal stromal tumour (GIST). *Gynecol Oncol*. 2005;97(3):970-2.
10. Bohnc S, Budimir I, Hrabar D, Babić N, Budimir I Jr, Nikolić M, et al. Abdominal ultrasound – the leading method in duodenal gist diagnostics. *Acta Clin Croat*. 2017;56(1):183-7. doi: 10.20471/acc.2017.56.01.26.
11. Zhao B, Zhang J, Mei D, Zhang J, Luo R, Xu H, et al. The assessment of different risk classification systems for gastrointestinal stromal tumors (GISTs): the analytic results from the SEER database. *Scand J Gastroenterol*. 2018;24:1-9.
12. Wada R, Arai H, Kure S, Peng WX, Naito Z. "Wild type" GIST: Clinicopathological features and clinical practice. *Pathol Int*. 2016;66(8):431-7.
13. Akbulut S, Ciftci F, Dirican A. Laparoscopic management of giant gastrointestinal stromal tumor masquerading as infected mesenteric cyst. *Ann Ital Chir*. 2018;89:342-6.