

Tanaffos(2002)1(1), 55-60

©2002 NRITLD, National Research Institute of Tuberculosis and Lung Disease, Iran

Primary Tracheal Synovial Cell Sarcoma: Case Report

Mir-Afsharieh SA¹, Arab M², Mohammadi F¹, Bahadori M¹

¹Department of Clinical Anatomical Pathology, ²Department of Thoracic Surgery, NRITLD, Shaheed Beheshti Medical University, TEHRAN-IRAN

ABSTRACT

Synovial sarcoma is malignant soft tissue with varying of mesenchymal and epithelial differentiation. This tumor usually occurs in paraarticular region and uncommonly within the articular cavity of upper and lower extremities. On rare occasions it occurs in areas without any apparent relationship to synovial structures such as abdominal wall, tongue, and parapharyngeal region. Primary tracheal tumors are relatively uncommon estimated 2.7 new cases per million per year. Sarcomas are rarely seen as a primary tracheal tumor. Only one case of primary synovial sarcoma of trachea was reported.

We report a case of primary synovial sarcoma of trachea in a 10 years old female. The patient underwent tracheal resection. The tumor was composed of spindle shaped cells in fascicular pattern and a few cystic structures. The tumor cells showed positive reaction for epithelial membrane antigen (EMA) and cytokeratin.

(Tanaffos 2002;1(1):55-60)

INTRODUCTION

Synovial cell sarcoma is a malignant soft tissue tumor with varying degrees of mesenchymal and epithelial differentiation. This tumor is usually occurred in para-articular regions and uncommonly within the joint cavity of extremities. It is rarely encountered in areas with no apparent relationship to synovial structures such as abdominal wall, tongue and parapharyngeal region. Primary tracheal tumors are relatively -- uncommon estimated 2.7 new

cases per million per year(7). We present a case of primary synovial sarcoma of trachea and review its clinical, radiological, and pathological aspects.

CLINICAL SUMMARY

A 10-year old girl, was admitted for severe dyspnea, respiratory distress and stridor with the diagnosis of upper respiratory obstruction. She had experienced progressive dyspnea for one year and was being treated for asthma. An episode of dyspnea was developed 3 years ago, when she was intubated with the probable diagnosis of croup. Then a few days later, symptoms relieved and she was discharged.

Correspondence to :Mir-Afsharieh SA
Tel.:+98-21-2803454 ;fax:+98-21-2285777
E-mail address:abbasmirafshar@hotmail.com

Archive of SID

The results of the physical examination were remarkable for respiratory distress (using accessory muscles, with suprasternal retraction). Bronchoscopy revealed a glossy smooth red mass in the right lateral wall of trachea, extending to 1.5cm below the true vocal cords and also occupying nearly 90% of the lumen.

Computed tomography demonstrated a 3.5 – 4 cm intratracheal mass without any extension outside the tracheal wall with its distal extension 4.5cm above the carina. There was no evidence of lymphadenopathy (Fig1).

At this stage, biopsy and resection were performed through bronchoscopy to reduce the obstruction and obtain pathologic specimens were taken. Pathologic studies revealed spindle cell tumor.

The patient underwent tracheal resection through a transverse cervical incision. Surgeon cut the thyrioid isthmus and tumoral mass was thyrioid isthmus and tumoral mass was explored. The mass was located at the beneath of the right-lobe. Specimens were obtained from the adjacent thyrioid tissue, the upper margin (cricoid), and the lower margin (trachea) were sent to pathology department for frozen section, however, all the four samples were revealed to have no tumoral involvement. About 3.5 cm of trachea was resected and end-to-end anastomosis

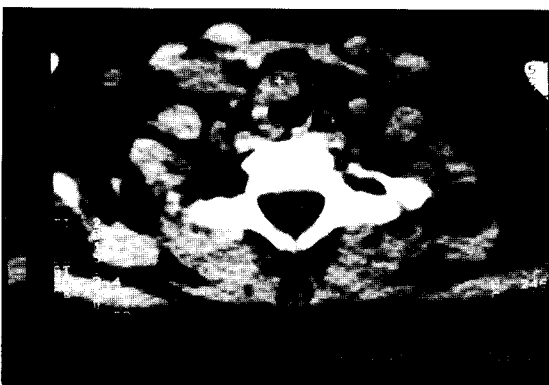

Fig 1. Ct scan shows an intratracheal mass

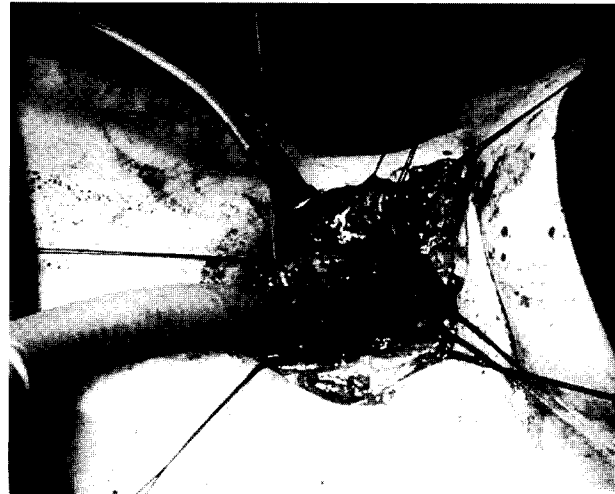


Fig 2. Surgical exposure of tumor

of trachea and cricoid was performed (Fig2). The patient recovered uneventfully and was discharged on the 7 th postoperative day.

PATHOLOGIC FINDINGS

-Macroscopy

A resected sample of trachea had 2 cm length, with an external diameter of 1.8cm. On section a grayish cream, solid tumor was observed, protruding into the lumen, and measured 2 x 1.5x 1 cm .

- Microscopy

The tumor consisted of spindle-shaped cells with a fascicular pattern and a few cystic structures (Fig3-4) . The spindle-shaped cells were compact, and they also have vague cytoplasmic borders and hyperchromic nuclei (Fig5). Few mitoses were dispersely visible (Fig6).

Tumoral invasion was observed in both tracheal mucosa and among mucosal glands. The surface of the tumor was ulcerated and granulation tissue was formed; meanwhile, tumor was not extended outside the trachea. Immunohistochemical staining, demonstrated a diffuse strong positivity for epithelial membrane antigen (EMA) (Fig7) and a focal positivity for



Fig.3



Fig.4



Fig.5



Fig.6



Fig.7



Fig.8

cytokeratin (Fig8) in tumoral cells. These findings suggest the diagnosis of synovial cell sarcoma.

DISCUSSION

Chronic obstruction of upper airways which is frequently mistaken for asthma and chronic obstructive pulmonary diseases, is resulted from different causes such as granulomatous infections, ectopic thymic or thyroid tissue, thyroglossal cysts, joint disorders like rheumatoid arthritis, immunologic disorders like Wegner's granulomatosis, vascular disorders like aortic aneurysm, and tumors. Squamous cell carcinoma, tracheal submucosal tumors, plasmacytoma, lymphoma, Kaposi sarcoma, thyroid cartilage condroma; pulmonary, thyroid, esophageal and metastatic carcinomas are the neoplastic causes of airway obstruction (3).

Smith described the first synovial cell sarcoma in 1927(6). Synovial cell sarcoma is a rare soft tissue tumor that comes fourth after malignant fibrohistiocytoma, liposarcoma, and rhabdomyosarcoma. It occurs primarily in the para-articular regions of the extremities, (85-95%) usually associated with tendon sheaths, bursae and joint capsules. It is uncommon in joint cavities and rarely encountered in areas with any apparent relation to synovial structures such as the abdominal wall and tongue. About 5-15% of synovial sarcomas arise in the head, neck and trunk. Macroscopically, synovial sarcomas are usually well defined, lobulated, and commonly invested by a thin pseudocapsule. On section, they are yellow to gray-white with necrotic, hemorrhagic, cystic, and calcified regions (2).

Micriscopically they can be classified into the (a) classic biphasic; (b) monophasic with spindle

shaped cells; (c) monophasic epithelial type; and (d) poorly differentiated type (2).

The classic biphasic type is recognized by the coexistence of both epithelial and spindle-shaped cells. Epithelial cells are less atypical with relatively well-defined cytoplasmic borders, and abundant acidophilic cytoplasm. They are disposed in cellular islands, glandular structures cryptic spaces and papillary structures. Spindle-shaped cells are characterized by fascicular, storiform or sometimes myxoid patterns. They have hyperchromic nuclei and small amounts of, pale-staining cytoplasm.

Poorly differentiated synovial sarcomas are composed of round cells with hyperchromic nuclei and scant cytoplasm. They are arranged in cellular sheets resembling those of round-cell malignancies, such as Primary Neuroectodermal Tumor (PNET) (2,6). Collagen synthesis, hyalinisation and calcification are other characteristic features that are present in sarcomas (4).

Immunohistochemical studies reveal positivity for epithelial membrane antigen (EMA) and low molecular weight of cytokeratin. Electron microscopy revealed epithelial cells which contain rough and smooth endoplasmic reticulum, mitochondria, prominent Golgi apparatus, intermediate filaments, tonofilaments, microvilli on the ductal surface of cells, and cell-basal lamina junctional complex (2,6). Balanced translocation of t(X:18)(p11;q11) and linked gene, SYT-SSX, can be found in most cases of synovial sarcoma (2,6).

The head and neck region is the second most common site of synovial sarcoma, accounting for up to 9% of all cases. Most of these tumors seem to originate in the paravertebral connective tissue and manifest as a retropharyngeal mass near the carotid bifurcation (6). Synovial sarcomas have been rarely reported in soft palate, maxillofacial region, mandibular angle, and esophagus. Most cases of head and neck synovial sarcomas occur in young adults.

The only report of primary tracheal synovial cell sarcoma was described in the departments of cardiothoracic surgery and pathology in medical college of Wisconsin, USA (8). The patient, a 20-year old man, was brought to the emergency department with respiratory distress, stridor and wheezing. Despite systemic steroid administration, no improvement was revealed. Progressive dyspnea, stridor, intermittent hemoptysis, coughing episodes, and weight loss more than 15 kg developed over a three-month period and a three-year history of controlled asthma were other clinical features. Bronchoscopy revealed a smooth tracheal tumor extending to 3cm below the true vocal cords.

Computed tomography demonstrated a 3cm intratracheal mass extending outside the tracheal wall. Metastatic work up of the chest, abdomen, pelvis and also bone scan were negative. Tracheal resection followed by radio-chemotherapy was performed (8).

Pulmonary metastasis has been reported in some 40% of patients with head and neck synovial cell sarcomas, a mean of 30 months after resection. Meanwhile, delay in diagnosis and narrow surgical margins for resection have been shown to worsen prognosis (8).

The diagnosis of synovial cell sarcoma is according to the classic biphasic morphology of tumor cells and positivity for cytokeratin and epithelial membrane antigen (EMA) (2,6).

Invasive fibrous tumor of tracheobronchial tree is the most important differential diagnosis of synovial cell sarcoma that could be simply distinguished according to the mitotic figures, cystic structures and immunohistochemical staining for cytokeratin and EMA (6,9).

Total resection of tumor without lymphadenopathy is the optimal treatment for synovial sarcoma of head and neck is wide surgical excision of the tumor without lymphadenectomy. Radiotherapy has been shown to improve local control of the tumor (8).

Considering the local recurrence of the tumor and appearance of metastases as late as 62 months after resection, long-term follow up with neck and chest CT is strongly recommended.

REFERENCES

- 1- Amble FR. Head and neck synovial cell sarcoma. *Otolaryngol Head Neck surg* 1992; 107: 631-7.
- 2- Enzinger FM. *Soft tissue tumor*. Mosby; 1995: 757-87.
- 3- Fraser. *Diagnosis of disease of the chest*. Vol 3. 4th ed. Philadelphia: Saunders; 2021-2054.
- 4- Jernstorm P. Synovial sarcoma of the pharynx: report of a case. *Am J Clin Pathol* 1954;24:957-61.
- 5- Mathisen DJ. *The Trachea*. 1996:875-899.
- 6- Plich BZ. *Head and neck surgical pathology*. Baltimore: Lippincott Williams Wilkins; 424-426
- 7- Roth JA. Synovial sarcoma of the neck: A follow up study of 24 cases. *Cancer* 1975; 35:1243-53.
- 8- Sykes AT. Primary tracheal synovial cell sarcoma: A first report. *J Thoracic Cardiovas Surg* 1997;114(4):678-680.
- 9- Hasleton P. Invasive fibrous tumor of the tracheobronchial tree. In: Spencer S, editors. *Pathology of the lung*. New York; McGraw-Hill: 1996;949-950.

گزارش یک مورد سارکوم سینوویال اولیه تراشه

دکتر سیدعباس میرافشاریه^۱، دکتر مهرداد عرب^۲، دکتر فروزان محمدی^۱، دکتر مسلم بهادری^۲
^۱استادیار،^۲استاد بخش پاتولوژی کلینیکال و آناتومیkal،^۳متخصص جراحی توراکس مرکز آموزشی، پژوهشی و درمانی سل و
بیماریهای ریوی، دانشگاه علوم پزشکی شهید بهشتی

سارکوم سینوویال، معمولاً در مناطق اطراف مفصلی بوجود می‌آید. فضای مفصلی اندام مکران ناشایعی برای این تومور می‌باشد. در موارد نادری، سارکوم سینوویال در مناطقی که با ساختمان‌های سینوویال ارتباط ندارند مانند دیواره شکم، زبان و ناحیه پارافارنژیال دیده شده است. تنها یک مورد سارکوم سینوویال اولیه تراشه در دنیا تا کنون گزارش شده است. مقاله حاضر به معرفی دومین مورد سارکوم سینوویال اولیه تراشه در یک دختر ۱۰ ساله پرداخته است.