

Tanaffos (2003) 2(6), 7-24

©2003 NRITLD, National Research Institute of Tuberculosis and Lung Disease, Iran

Surgical Treatment of Pulmonary Metastasis

Azizollah Abbasi Dezfouli, Mojtaba Javaherzadeh, Abolghasem Daneshvar Kakhki, Mehrdad Arab, Mohammad Behgam Shadmehr

Department of Thoracic Surgery, NRITLD, Shaheed Beheshti University of Medical Sciences and Health Services, TEHRAN-IRAN

SUMMARY

The first surgical resection of single lung metastases was reported by Weinlechner in 1882. This metastatectomy was done for a discrete pulmonary metastases which was discovered during resection of a chest wall sarcoma (1). The patient died on the first day after surgery. One year later, Kronlein performed same operation successfully (2). During surgery of a recurrent sarcoma of the chest wall in an 18-year-old girl, he noticed a pulmonary metastases in the size of a walnut. He removed it with a wedge resection and the patient survived for 7 years later but unfortunately died due to a second recurrence. In spite of this successful metastatectomy, there was a long period of suspicion about metastatectomy among physicans. It was considered that the presence of metastasis indicates spreading of the disease so that, surgery is not useful. In spite of this belief, many efforts were done for surgical treatment of patients with pulmonary metastases (3,4). The advent of chemotherapy during 1960-70 caused an important impact on the treatment of pulmonary metastases. The majority of patients suffering from different malignancies survived for a longer period of time by this method, and some of them referred with solitary and removable pulmonary metastasis. In addition, the surgical methods were improved, and postoperative mortality was decreased.

Nowadays, pulmonary metastasectomy is a part of treatment in most malignancies, and controversies are only with regard to operation indication and selection of patients. This procedure had good results in numerous reports (5-10). Nevertheless, the total cure rate is around 20%, and successful results have been reported mainly in selected patient groups. Thus, we do not recommend metastasectomy as a routine procedure in all patients who have metastases. With good selection of patients and surgical approaches, nearly one third of all patients presenting with pulmonary metastases as the only site of the disease may benefit from resection of their metastases. (Tanaffos 2003; 2(6): 7-24)

E-mail address: Abbasidezfouli@nritld.ac.ir

INTRODUCTION

The history of metastatectomy in Iran:

Thoracic surgeons have removed pulmonary metastatic tumors individually in recent years. Developing oncology and multimodality therapy for malignancies in our country caused increasing

number of patients who were selected for pulmonary metastatectomy. To our knowledge, no review articles have been published in Iran. Most of the reports have either been medical thesis (1-8 Persian) or case reports (9-10 Persian). Some discussions

Correspondence to: Abbasi Dezfouli A

Tel: +98-21- 2280161, Fax: +98-21-2285777

regarding pulmonary metastatectomy have been considered in native lectures and congresses (11-Persian). As the thoracic surgeons have actively participated in the treatment of pulmonary metastatic cancers, we hope that noticeable articles and researches would be presented in our country.

Basic Mechanisms of metastasis

The best definition for metastasis may be “derangement of balance between tumor and host”. In fact, metastasis is caused by interaction of tumor and host cells. It presents when a series of reactions occurs. These reactions include tumor growth, producing a network of new vessels within tumor, invasion, transmission of tumor cells into the vessels, survival of detached cells, ceasing and emission of wandering tumor cells from the vessels, attachment and multiplication of separated cells in other place, and finally repeating of metastasis in the new tumor (11-13).

Metastasis is a well-developed event and acts selectively in different tissues. Alive metastatic cells have different immunological, biological, and antitoxic characteristics comparing with primary tumor cells; they overcome host defense mechanism. For early recognition, prevention, and effective therapy of metastases, this phenomenon must be assessed at the genetic and molecular level.

Various diagnostic and therapeutic aspects of pulmonary metastasis are shown in table 1 and will be discussed in this review.

Table 1. Various diagnostic and therapeutic aspects of metastatectomy in pulmonary metastasis.

1- Clinical symptoms
2- Radiologic findings
3- Bronchoscope
4- VATS *
5- Surgical precedures
6- Characteristics of various matakstastic tumors (osteosarcoma, soft tissue sarcoma, germ cell tumors, melanoma,tumors of colon, breast, kidney, ...)

7- Researching methods

8- Therapeutic outcome and staging

* VATS= Video-Assisted Thoracoscopic Surgery

1. Clinical symptoms:

Pulmonary metastases rarely cause clinical symptoms, and diagnosis is usually based on chest X-ray during follow-up of a patient whose primary tumor is under treatment. The pain is usually not present except in case of pleural involvement. Few patients may have symptoms like dyspnea, cough and hemoptysis. Pneumothorax is rarely seen and is due to tearing of pulmonary parenchyma in peripheral metastatic nodules (14). If a patient has history of treatment of a cancer specially sarcoma, we should consider pulmonary metastasis.

The presence of clinical symptoms in pulmonary metastases is often due to disease progression and inability of complete pulmonary metastasectomy. When diffuse involvement of bronchus, pleura, mediastinum, pericardium and other important organs inside the thorax exist, these signs and symptoms will present.

2. Radiological findings

The classical radiological finding in chest X-ray is detecting one or more pulmonary nodule with distinct and soft margin which is located mainly in periphery. In fact, in most cases pulmonary metastases are detected by simple chest X-ray (15-17). These images can be observed more clearly in computed tomography scan (CT-Scan) (18,19). Detection of multiple pulmonary nodules in chest X-ray in a patient with cancer usually confirms metastasis. Unfortunately, radiological characteristics of these nodules are not specific, and in the absence of history of cancer, there would be differential diagnosis with other pulmonary diseases. However, many researchers have attempted to find similar characteristics for confirming metastatic nodules with regard to their size, degree of growth, number,

characteristic of margin, calcification, cavitation, and type of distribution in the lung (20-27).

Other radiological findings of pulmonary metastases in chest X-ray, other than presence of peripheral nodules, may be as follows: reticulonodular images, enlargement of mediastinal or hilar lymph nodes, pleural effusion, a large mass, cavity with thick wall and atelectasis in a part of lung. The sensitivity of chest X-ray for diagnosing small metastatic nodules is low, while the majority of pulmonary metastases are small (less than 1 cm) (27-30). On the other hand, in the smaller pulmonary nodules, there is less possibility of metastasis.

A study showed that the possibility of metastasis in nodules larger than 2.5cm is more than smaller ones (31). In a study which was conducted on postmortem examination of patients that had died due to different reasons, only 48% of pulmonary metastatic nodules had been recognized in the radiography before death (32). Although CT-scan is more sensitive in detecting pulmonary nodules than simple X-ray; however, it is less specific (33-35). CT-scan not only detects more numbers of nodules but also demonstrates other characteristics related to metastasis like presence of adenopathy in mediastinum, invasion to the vessels and bronchi, and ability to resect the lesion. Even CT-scan does not recognize real number of metastases, and usually during operation more numbers are detected rather than those in reported CT-scan. In the patient whose CT-scan has multiple metastases and is candidate for surgical operation, spiral CT-scan is better than conventional CT-scan for more accurate determination of true number of metastases (36).

The role of MRI (magnetic resonance imaging) in evaluation of pulmonary metastatic nodules is not clearly understood. For detection of vascular involvement in tumors which are near mediastinum and skeletal involvement in tumors adjacent to the vertebral column, MRI has more diagnostic value

comparing to CT-scan. However, sensitivity of MRI is not different from CT-scan.

The ability of PET (positron emission tomography) in diagnosis of pulmonary metastasis is similar to CT-scan; however, the former can reveal the presence of metastasis in other parts of human body in addition to detection of tumor recurrence in primary focus. It seems that PET-scan is more specific than CT-scan in diagnosis of metastases. Some researchers believe that PET-scan should be a part of diagnostic and therapeutic strategy in all patients afflicted by pulmonary metastases (37).

3. Bronchoscopy:

In a patient with small and peripheral pulmonary nodules, bronchoscopy usually does not show abnormal findings. Therefore, it is better to delay bronchoscopy in these patients to be done at the time of operation and under general anesthesia.

However, if the patient has signs and symptoms of an endobronchial involvement (like atelectasis, hemoptysis and cough), bronchoscopy is necessary before surgery to assess accurately endobronchial lesion for size, location, and extent of involvement. Then, we can adjust, based on these data, the surgical program in order to determine kind of operation, type of incision, amount of pulmonary resection, necessity of bronchoplasty, and sleeve-resection. The prevalence rate of endobronchial and endotracheal metastases is about 2-5% (38). Nevertheless, if direct invasions from pulmonary parenchymal tumors or lymph nodes into the bronchi are considered as endobronchial metastasis, this rate will reach to 30-50% (39). The tumors which may invade bronchi more than others include tumors of colon, breast, kidney, urinary tract, melanoma, and sarcoma (40,41). The patients with endobronchial metastases usually have symptoms like cough and hemoptysis.

4. VATS:

Thoracoscopy has an important diagnostic role in a number of patients with pulmonary metastasis. It can be useful in evaluating causes of pleural effusions (42), and determining extent of lesion in a patient

with border- line condition to operate or doubt in total resectability of the lesion (43).

Thus, sometimes bilateral thoracoscopy is necessary to assess total resectability of a lesion. The therapeutic role of the VATS in pulmonary metastases is controversial, the reasons may be as follows:

1- Some nodules have small size and have not been recognized with imaging techniques including CT-scan, but they are found during open surgery with palpation by surgeon's hand; some of these tumors may be missed with VATS.

2- The resection of large number of nodules in VATS is more difficult than with open surgery and the time of operation would be longer. The best condition for using VATS as a therapeutic procedure is for a peripheral metastatic nodule with small size (figure 1). However, the most sensitive way to find other metastases which had been missed by imaging techniques is palpation of the lung by the hand of surgeon.

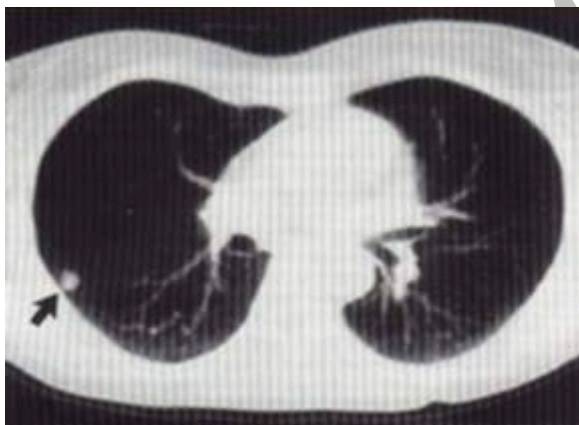


Figure 1. The patient had osteosarcoma of the extremities 5 years ago and now is candidate for the surgery because of a pulmonary nodule in the right lower lobe.

5- Surgical procedures:

The aim of surgery in pulmonary metastatectomy is removal of all existing tumors and suspicious lesions. For this purpose, we must avoid from limited incisions and palpate the whole of lung during

thoracotomy and look for the metastasis. Also, both mediastinum and lymph nodes should be assessed. If only a part of tumor remains, the outcome is not good for the patient (44). Furthermore, the most important role of the surgeon in evaluation and selection of the patient is answering two important questions

1. Regarding to general condition of the patient, can he or she tolerate operation?
2. Is extension of the lesions appropriate to remove all of them in one or several surgical procedures?

In few cases, despite impossibility for removing tumor totally, the surgical operation is performed to increase response of chemotherapy. Even removing a part of a huge germ cell tumor may have a positive effect on the response to chemotherapy (45).

SURGICAL INCISION

The incisions used for metastatectomy include midsternotomy, clamshell, standard postero-lateral thoracotomy or its modified forms, and VATS. To remove pulmonary metastases, one should apply an incision which provides availability to whole lung and mediastinum. The best exposure to these regions is through a “standard postero-lateral thoracotomy” incision.

Today, we are able to apply lateral incision instead of postero-lateral one along with protection of chest wall muscles by using double lumen endotracheal tubes and surgical staplers. Serratus anterior and latissimus dorsi muscles are not divided in this incision, and are mobilized by broad flaps making submusculo-cutaneously. Ginsberg from Memorial Sloan- Kettering cancer center of New York and some other researchers recommend vertical transaxillary thoracotomy incision with protection of the chest wall muscles, without using musculocutaneous flaps (46-48). The location of

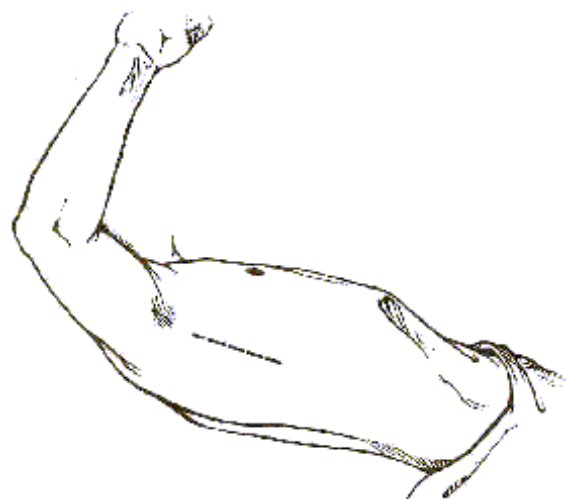surgical incision will be hidden under arm in this procedure (49). Figure 2, demonstrate the steps of this operation.

In this incision, the patient is placed in lateral decubitus position and the arm is put in 90° abduction. A vertical incision is made in midaxillary line. If needed, its length would be longer (figure 2-A). Subsequently, subdermal tissues and superficial fascia are cut, so posterior margin of serratus anterior muscle and anterior margin of latissimus dorsi muscle are exposed (figure 2-B). Then, latissimus dorsi muscle is lifted and pulled back, and serratus anterior muscle is pulled up and forward so

appropriate intercostal space will be exposed in order to enter the chest (figure 2-C).

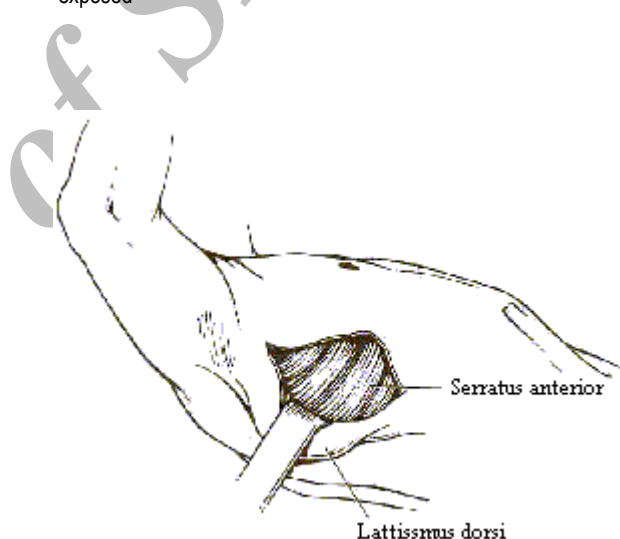
No subdermal flap is made in this incision and an extra ecarteur is used for pulling aside the muscle (figure 2-D). The 5th or 6th intercostal space is usually chosen for penetrating into the pleural space. One can explore thorough out the lung and mediastinum and do segmental resections through each these two spaces. Furthermore, anatomic resections (lobectomy, pneumonectomy) may also be performed. The longer vertical cutaneous incision, would expose more portion of the intercostal space.

Figure 2 (A-D): Thoracotomy with vertical cutaneous axillary incision

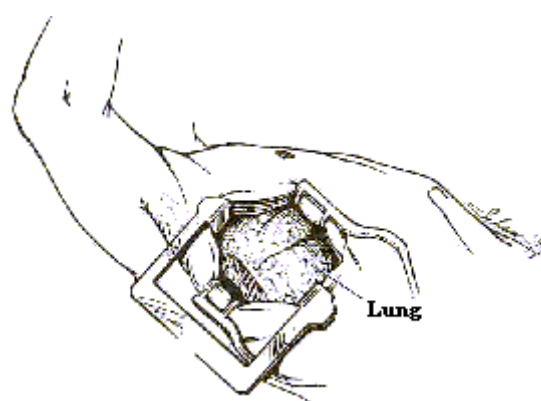
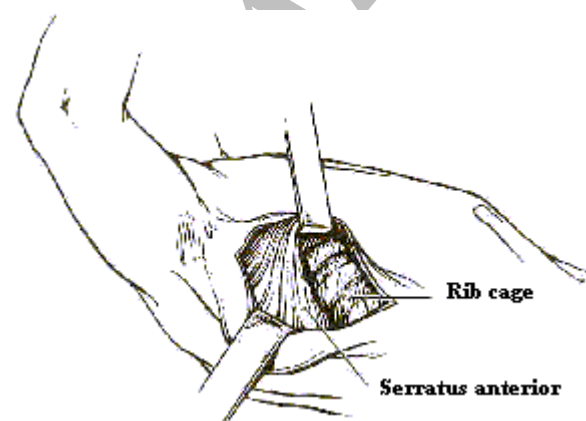


A. Cutaneous incision. The more length of cutaneous incision, the more exposed intercostal space.

C. By pushing aside chest wall muscles, intercostal spaces will be exposed



B. The chest wall muscles are exposed.



At first, the side of the thorax with more involvement would be explored. If the metastases are removable, the opposite site should be searched at the same time or in another situations: this exploration is recommended even with negative radiologic examinations (in some of the tumors like germ cell tumor which has good sensitivity to chemotherapy, surgical exploration of the opposite site is not necessary, if imaging evaluations are negative). Post operative chemotherapy is usually performed after metastasectomy; however, it is controversial.

MIDSTERNOTOMY INCISION

This method is preferred to operate both sides of the chest at the same time, but approaching to the posterior parts of the lung is not easy. Therefore, the patients who has multiple lesions in the posterior parts of the lung can not be operated through this type of incision. Bilateral transverse thoracotomy incision with cutting the sternum, horizontally at the midline (clamshell incision), causes better approach on the lower and posterior parts of the lung rather than midsternotomy incision, but in comparison to lateral incisions this accessibility is less.

Nowadays, many researchers suggest bilateral thoracotomy in two stages with one to three weeks interval. The author also believes that this procedure should be used for patients with bilateral multiple lesions.

VATS is not recommended for metastasectomy. We cannot palpate lung with this procedure, in addition, some of the metastases may not be detected which is in contrast with principles of metastasectomy. Furthermore, resection of multiple tumors is more difficult and takes a longer time in VATS comparing to open surgical procedures. Some of the researchers recommend using VATS accompanying with open but restricted incisions like

D. 5th or 6th intercostal spaces are chosen to enter into the intrapleural space. An extra ecarteur is applied for pulling away the skin.

partial midsternotomy or limited thoracotomy. Thus, they can not only palpate the lung through the open incision and find small nodules but also perform resection using VATS (50,51). At present, open thoracotomy procedure with invasive approach for detection and removing all metastases is a standard method and VATS or minimal access procedures are used infrequently (52).

THE EXTENSION OF RESECTION

Most metastatic lesions are removed by nonanatomic resections (wedge resection), but sometimes lobectomy or pneumonectomy is required because of the large size of tumor or its location at the center of a pulmonary lobe. Before performing such resection, the surgeon should evaluate the patient's respiratory condition and lung compliances accurately. Extensive pulmonary resections especially in cases with pleural and mediastinal involvement not only cause higher rates of morbidity and mortality but also does not support good results regarding total resection of tumor and the patient survival.

Intact surgical margin surrounding the tumor: The growing pattern of metastatic pulmonary tumors is "growing in its own place". In contrast with bronchogenic tumors, they do not grow via blood and lymphatic vessels. Therefore, anatomic resections like lobectomy and pneumonectomy are not required and only removing small margin of the tumors (less than 2cm) is adequate. Most of the surgeons consider that surgical margin of 5-10 mm would be enough. Due to probability of micrometastases around the metastatic tumors, it is recommended to evaluate the margins of pulmonary metastases after tumor resection with frozen section. Lobectomy or pneumonectomy is required, if metastases is large and located in central parts of the pulmonary lobe. As a whole, if the metastasis is less than 3 cm and

located in outer one-third of the pulmonary parenchyma, it might be removed by a wedge resection (53). However, if the size of tumor is more than 3-4 cm, and located in the more central parts of the lung, lobectomy is necessary. Of course, sometimes more greater tumors are completely in the periphery and can be removed by wedge resection.

By using some newer technologies, we may avoid lobectomy in deep or large tumors. Among these, laser-assisted pulmonary resection (LAPR) is used for resection of large tumors (54-57) and cavitary ultrasonic aspirator (CUSA) used to resect deep small tumors (58,59). A useful practical procedure called precision resection is used for surgical resection of pulmonary metastasis. In this method, pulmonary parenchyma is cut by cauterization, laser or Argon in distance of 5-10mm from surrounding the tumor and all of the mass is removed. Via this incision the cut vessels and bronchi are ligated by metallic clips or sutures. In this type of incision, the tumor is usually removed as a cone which its base is located on the pleural surface, and the apex directed toward the pulmonary parenchyma.

This procedure may be more useful for metastasectomy of the multiple nodules rather than surgical staplers or traditional method of placing clamp, cutting, and suturing (60).

6- Characteristics of various metastatic tumors:

Pulmonary metastases has been reported of 20 to 54 percent in autopsy of the patients died from extrathoracic cancers (61-63). When a pulmonary metastatic tumor is diagnosed in a patient, the most common causes are cancer of breast, colon, kidney, uterus, prostate, and oropharynx, respectively (61,63, 64). On the other hand, the malignancies with favor to cause metastasis in the lung, include choriocarcinoma, osteosarcoma, tumors of the testis, melanoma and Ewing's sarcoma (64,65), but as these cancers have much lower prevalence, pulmonary metastases caused by them are seen with lower frequency in general population.

OSTEOSARCOMA

Nowadays, pulmonary metastasectomy is an important part of therapeutic strategy in patients afflicted by osteosarcoma. About 10-20% of these cases have detectable metastasis during distant regions on initial diagnosis; more than 85% of these metastases are pulmonary (66). The survival of patients with osteosarcoma has been increased by combination therapies (multi modality), including chemotherapy and conservative surgery (limb saving surgery). However, the patients with coincidence of osteosarcoma and pulmonary metastasis or those involved by metastase later may be cured if we could be resected the whole primary and metastatic tumors.

At present, the best way for screening of the patients with osteosarcoma in order to find pulmonary metastases is using chest CT-scan with contrast. Magnetic resonance imaging (MRI) does not have more advantage than CT-scan; in addition, the role of PET-scan is still unclear. The whole body bone scan is not also useful in the follow-up because its sensitivity is high and specificity is low. A study showed that in 66 positive bone scans performed during follow up of the patients, only seven cases had recurrent tumor (67). However, if the patient has confirmed pulmonary metastasis, the whole body scan should be done before metastasectomy.

SOFT TISSUE SARCOMA

Like osteosarcoma, metastases in these tumors are restricted to the lung (68). If we are able remove all metastases surgically, curing or increasing survival of the patients is possible; the principles of metastasectomy in these patients are similar to those with osteosarcoma and have been summarized in table 2. Occasionally, there are some indications for incomplete resection of pulmonary metastasis, including definite diagnosis of a suspected lesion and evaluation of residual radiologic abnormalities after chemotherapy.

In case of appropriate conditions for metastasectomy, high survival may be expected in about one-third of the patients. Furthermore, if recurrency presents after pulmonary metastasectomy, we can still resect the lesion for a longer life time (69).

Table 2. Indications for metastasectomy in sarcoma

-
- 1- The primary tumor must be eradicated
 - 2- All nodules be resectable in one operation or staged operations.
 - 3- The residual respiratory volume sufficient after surgery.
 - 4- No other extrathoracic metastasis is present.
-

There are some conditions which have better prognosis, including low number of metastases (>4, preferably one), long interval between diagnosis of primary tumor and metastasis (<36 months), appropriate histology (mean survival of 33 months for malignant fibrous histiocytoma vs 17 for other sarcomas), long doubling time (> 40 days), and the presence of pathology on one side of the chest (70-73).

Pre or postoperative chemotherapy is not efficient in the control of metastases but is effective on controlling of micro metastases; thus, it is better to be done (74). However, prospective clinical studies are not yet available for comparing benefit of chemotherapy (salvage chemotherapy) before metastasectomy of sarcomas with the surgery alone.

COLORECTAL CARCINOMA

About 2% of colon tumors relapse exclusively in lungs (75,76). Resection of colorectal metastases is indicated, if the patients have other indications for metastasectomy as follows: the patient can tolerate the operation, all lesions are removable, and the primary tumor is under control. The difference between indications of metastasectomy in colon tumors and sarcoma is that the metastasis is not necessary to be restricted to the lungs. In other words, if resectable metastases caused by colorectal carcinoma are present simultaneously in lung and

liver the surgery and concomitant resections of liver and lung metastases will be indicated (77,78). Adjuvant and neoadjuvant therapies in a patient with pulmonary metastasis due to colorectal tumor have not had noticeable results (79-82) and are not recommended now. The measuring of CEA (carcinoembryogenic antigen) during follow up of the patients with metastases causing by colorectal tumors is indicated; it seems that the patients who have pulmonary metastasis with normal CEA, the prognosis is better after metastasectomy comparing to those with higher CEA (83-85). Thus, the higher CEA, the worse prognosis. Endobronchial metastases are seen in patients with metastatic colorectal tumors more than other tumors. A total resection is not possible usually in these patients and treatments are rather palliative including bronchoscopy and laser, for opening obstructed bronchus, controlling infection and hemoptysis.

METASTASIS OF RENAL TUMORS

About half of patients undergoing nephrectomy due to renal cell carcinoma, will be afflicted by metastasis later.

Generally, metastasectomy will be required when metastases are restricted to the lung and there are appropriate indications like completely resectable lesions. Some reports indicated that if the metastasis is single, and interval between nephrectomy and presence of metastasis are long, the more survival is expected with metastasectomy (87). Additionally, pulmonary lymph nodes and mediastinal involvement are occasionally seen concurrently with pulmonary metastasis. Therefore, evaluation of lymph nodes is recommended before and during the operation. In patients with pulmonary metastasis due to renal tumor and have the necessary criteria for metastasectomy, five year survival rate has been reported about 36% (87,88).

BREAST CANCER

Intrathoracic metastases arising from the breast cancer contain main part of the patients referring for

surgical consultation due to tumor metastases in the chest. Most patients have diffuse pulmonary and pleural involvements (like pleurisy) and only require palliative surgical treatment, including discharge of fluid via chest tube, pleurodesis, and pleurectomy.

About 20% of the women with breast cancer have pulmonary and pleural metastases during the period of disease and most of them require palliative surgical interventions. If we notice that about 10% of the women would be afflicted by breast cancer during their life, so we can conclude that of each thousand women, twenty would be consulted surgically due to pleural involvement and signs of pleurisy. Nevertheless, there are few numbers of the patients having indications for metastasectomy because of pulmonary metastases arising from breast cancer.

Another important note regarding the metastases of breast cancer is a difficult differentiation between metastasis and primary pulmonary tumor. Detection of a pulmonary nodule in a patient with history of breast cancer may indicate a metastatic lesion, a primary pulmonary tumor or a benign lesion. Synchronous or metachronous presentation of this nodule does not have a significant effect on the diagnosis, even time interval between primary tumor and presentation of nodule is not helpful. Some nodules which have been revealed 15 years later in the lung, had been metastatic. In contrast, occasionally we may observe pulmonary tumor and breast cancer concurrently (89,90).

On the other hand, since the breast cancer metastasize from different ways in various regions, extensive clinical assessments should be performed to detect metastasis in other places, if a solitary metastatic nodule exists in the lung. These evaluations include CT-scans of brain, abdomen and pelvis and the whole body radioisotope scan. If the warning signs are present, more diagnostic imaging examinations should be performed like MRI of vertebral column, PET, etc.

Anyway, if the metastasis of breast cancer is present simultaneously in other regions, metastasectomy is forbidden, but if it is restricted to the lungs and is resectable, the surgical treatment is indicated. However, combination therapies (multimodality) like chemotherapy, hormonotherapy and immunotherapy are still preferred by some oncologists because despite of all assessments, the extension and number of lesions during metastasectomy are more than that of expected in preoperative evaluations. Thus, we suggest that the opposite site of the chest be explored during metastasectomy of the breast cancer or using incisions with capability of bilateral exploration.

GERM CELL TUMORS

About seventy percent of patients with pulmonary metastasis arising from seminoma have complete response to chemotherapy; meaning that not only lungs become clear radiologically, but also tumor markers reach to the normal limits. Even those not responding to initial chemotherapy, are improved in 25% of cases with final chemotherapy (salvage chemotherapy); however, despite normalized tumor markers after chemotherapy, radiologic images are not cleared in a remarkable number of patients. There is no way to be assured whether the remaining radiologic images are alive tumor (or scar tissues). Since resection of remaining tumor is useful for these patients, they contain the main group of the patients with germ cell tumor referring to the surgeon for exploration and resection of the lesions. Chemotherapy is not efficient in a few numbers of the patients, and the levels of tumor marker remain high after chemotherapy. In such cases, the common belief is against the surgery, however, few studies have shown that even in these patients, metastasectomy sometimes causes improvement especially if the tumor is unilateral and resected totally (91).

The resected pulmonary metastases in patients with non-seminoma tumor and normal tumor markers, have viable tumor only in 20% of the resected specimens and in others either fibrosis, necrosis or mature teratoma have been observed (92-94). The status of seminoma is controversial. The remaining radiologic tumors after treatment of seminoma have less alive tumor rather than nonseminoma tumors (95,96). The tumor markers value is not also clear. Today, the removal of remaining radiologic tumors after chemotherapy of seminoma vs. follow-up alone remains controversial. Furthermore, due to employing radiotherapy in the treatment of seminoma, resection of related tumors is more difficult than that of nonseminomas. Some researchers have recommended to perform biopsy alone and avoidance of total resection. The others, with attention to more possibility of alive tumor in the remaining tumors with larger size, have suggested that the tumors more than 3 cm be resected or at least surgical biopsy be performed (97).

METASTASIS OF MELANOMA TO THE LUNG

The data have demonstrated that in patients with low number of pulmonary metastases and other favorable prognostic criteria (i.e. long doubling time and long interval between primary tumor and pulmonary metastasis), total resection of pulmonary metastases, caused by melanoma, is effective. Additionally, more survival and cure have been observed in these patients rather than those who have not undergone metastasectomy (98,99). In fact, in a patient with pulmonary metastases due to melanoma and no metastasis in other places, other therapies like immunotherapy and chemotherapy have not significant effect on the patients' cure. The reason is low complete response to different drug therapies. Recently, biologic therapies (biochemotherapy) like

interferon- alpha (IFN- α) and interleukin-2 (IL-2) have been added to chemotherapy regimens to increase the rate of complete response. Unfortunately, the responses rate have been low. In spite of this fact, metastasectomy causes the best chance for curing of pulmonary metastatic melanoma in patients with mentioned appropriate criteria. It also has a complementary role in the treatment of the patients with incomplete response to chemotherapy.

7- Researching aspects

For better treatment of metastases, investigation has been continuing in different fields, including production of systemic drugs for more effective chemotherapy, perfusion the whole lung or part of it by anticancer drugs, genetic interventions for suppressing or eradicating tumor cells, amplification of immune system, employment of better surgical methods with less complications and making an appropriate staging system for pulmonary metastatic cancers. It seems that the most effective development in the treatment of pulmonary metastases would be possible when the better systemic treatment is available. At present, adjuvant and neoadjuvant therapies have not an important role in controlling of metastases either those removed by the surgery or non-resectable ones. The newer antimetastasis drugs like metallo-proteinase inhibitors and synthesized antibodies against vessel endothelial growth factor are favorable in the above mentioned therapies. The administration of intra-arterial anti neoplasm drugs and subsequently inducing a high tissue level of drug substrate in the lung without producing toxic complications in other regions has been employed more in animals with favorable results (106-108).

To date, the best results in the treatment of pulmonary metastases have been achieved with surgery accompanying with resection of the metastases. Thus, we must use this therapeutic method in appropriate patients who take advantage of

this operation. The complications of the surgery are low in hands of experienced surgeons and the mortality rate has been reported below 2% (109-112). However, less than one-third of the patients can be cured with metastasectomy; thus, we should not operate the patients having high risk for the surgery, the spread tumor metastasis, and other inappropriate conditions which decrease the chance for operation.

8- Therapeutic outcome and staging

The selection of appropriate patient for metastasectomy is rather difficult. In numerous studies, different risk factors have been considered for the treatment outcome of the disease, but most of them have been studied small number of patients, thus, we cannot expect definite and valuable results. The only exception is about germ cell tumors because of its known reliable criteria for the treatment outcome. In 1991, thoracic surgery centers established "International Registry of Lung Metastase" (IRLM) in eighteen regions of Europe and North America, 5206 patients with pulmonary metastasis reviewed retrospectively with regard to prognostic variables and results of surgical resection using the three variables, resectability, disease-free interval, and number of metastasis, registry classified patients into prognostic groups that could serve as a staging system. Table 3 shows staging resulted from these evaluations.

Table 3. Staging of pulmonary metastases for determination of surgical outcome

Stage 1= resectable, absence of another risk factor *

Stage 2= resectable, presence of one risk factor

Stage 3= resectable, presence of two risk factors

Stage 4= non- resectable

* Risk factors: 1- time interval until tumor recurrency< 36 months

2- multiple metastases

Germ cell tumors and willm's tumor have not been considered in this staging (113). The surgical outcome, based on this categorization, has been summarized in figure 3.

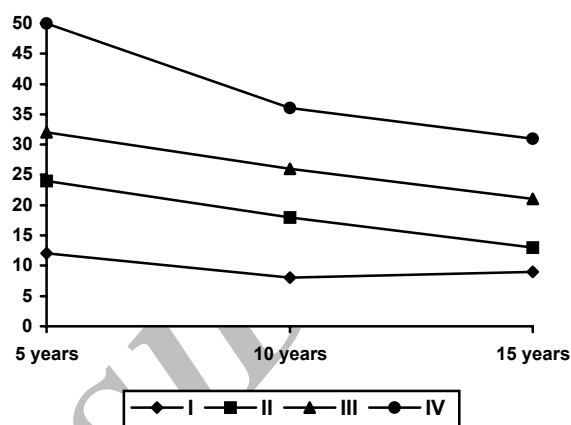


Figure 3. The survival time after metastasectomy in IRLM staging

REFERENCES

- Weinlechner JW. Zur Kasuistik der Tumoren an der Brustwand und deren Behandlung (Resektion der Rippen, Eröffnung der Brusthöhle, partielle Entfernung der Lung). *Wein Med Wochenschr* 1882, 32: 589-591, 624-628.
- Kronlein RU. Ueber lungenchirurgie. *Berl Klin Wchnschr* 1884, 21: 129-132.
- Baryney JD, Churchill EJ. Adenocarcinoma of the kidney with metastasis to the lung. *J Urol* 1939, 42: 269.
- Alexander J, Haight C. Pulmonary resection for solitary metastatic sarcoma and carcinoma. *Surg Gynec Obstet* 1974, 85: 129.
- Martini N, Huvos AG, Mike V, Marcove RC, Beattie EJ Jr. Multiple pulmonary resections in the treatment of osteogenic sarcoma. *Ann Thorac Surg* 1971; 12(3): 271-80.
- Beattie EJ Jr, Martini N, Rosen G. The management of pulmonary metastases in children with osteogenic sarcoma with surgical resection combined with chemotherapy. *Cancer* 1975; 35(3): 618-21.
- Telander RL, Pairoler PC, Pritchard DJ, et al. resection of pulmonary metastatic osteogenic sarcoma in children. *Surgery* 1978; 84: 335-341.

8. Meyers PA, Heller G, Healey JH, Huvos A, Applewhite A, Sun M, LaQuaglia M. Osteogenic sarcoma with clinically detectable metastasis at initial presentation. *J Clin Oncol* 1993; 11(3): 449-53.
9. Heij HA, Vos A, de Kraker J, Voute PA. Prognostic factors in surgery for pulmonary metastases in children. *Surgery* 1994; 115 (6): 687-93.
10. Murphy BR, Breeden ES, Donohue JP, Messemer J, Walsh W, Roth BJ, Einhorn LH. Surgical salvage of chemorefractory germ cell tumors. *J Clin Oncol* 1993; 11(2): 324-9.
11. Doerr R, Zvibel I, Chiuten D, D'Olimpio J, Reid LM. Clonal growth of tumors on tissue-specific biomatrices and correlation with organ site specificity of metastases. *Cancer Res* 1989; 49 (2): 384-92.
12. Eccles SA, Alexander P. Immunologically mediated restart of latent tumor metastasis. *Nature* 1975; 257: 52-53.
13. Ellis LM, Fidler IJ. Angiogenesis and breast cancer metastasis. *Lancet* 1995; 346 (8972): 388-90.
14. Putnam JB. Secondary Tumors of the lung. General Thoracic Surgery. By Shields TW. By Lippincott Williams & Wilkins. 2000 chapter 113, 1556.
15. Libshitz HI, North LB. Pulmonary metastases. *Radiol Clin North Am* 1982; 20 (3): 437-51.
16. Spebcer H. Pathology of the lung (excluding pulmonary tuberculosis). Oxford, Pergamon Press, 1985.
17. Willis RA. The spread of tumors in the human body, ed 3. London, Butterworths & Co, LTD, 1973.
18. Gross BH, Glazer GM, Bookstein FL. Multiple pulmonary nodules detected by computed tomography: diagnostic implications. *J Comput Assist Tomogr* 1985; 9(5): 880-5.
19. Scholten ET, Kreeel L. Distribution of lung metastases in the axial plane. *Radiol Clin North Am* 46: 248-256, 1977.
20. Bateson EM. An analysis of 155 solitary lung lesions illustrating the differential diagnosis of mixed tumors of the lung. *Clin Radiol* 16: 51-65, 1965.
21. Chaudhuri MR. Cavitory pulmonary metastases. *Thorax* 1970; 25 (3): 375-81.
22. Coppage L, Shaw C, Curtis AM. Metastatic disease to the chest in patients with extrathoracic malignancy. *J Thorac Imaging* 1987; 2 (4): 24-37.
23. DODD GD, BOYLE JJ. Excavating pulmonary metastases. *Am J Roentgenol Radium Ther Nucl Med* 1961; 85: 277-93.
24. Hirakata K, Nakata H, Haratake J. Appearance of pulmonary metastases on high-resolution CT scans: comparison with histopathologic findings from autopsy specimens. *AJR Am J Roentgenol* 1993; 161 (1): 37-43.
25. Janower ML, Blennerhasset JB. Lymphangitic spread of metastatic cancer to the lung. A radiologic-pathologic classification. *Radiology* 1971; 101(2): 267-73.
26. Johkoh T, Ikezoe J, Tomiyama N, Nagareda T, Kohno N, Takeuchi N, Yamagami H, Kido S, Takashima S, Arisawa J, et al. CT findings in lymphangitic carcinomatosis of the lung: correlation with histologic findings and pulmonary function tests. *AJR Am J Roentgenol* 1992; 158 (6): 1217-22.
27. Zwirowich CV, Vedal S, Miller RR, Muller NL. Solitary pulmonary nodule: high-resolution CT and radiologic-pathologic correlation. *Radiology* 1991; 179 (2): 469-76.
28. Crow J, Slavin G, Kreeel L. Pulmonary metastasis: a pathologic and radiologic study. *Cancer* 1981; 47 (11): 2595-602
29. Ren H, Hruban RH, Kuhlman JE, Fishman EK, Wheeler PS, Zerhouni EA, Hutchins GM. Computed tomography of inflation-fixed lungs: the beaded septum sign of pulmonary metastases. *J Comput Assist Tomogr* 1989; 13 (3): 411-6.
30. Schaner EG, Chang AE, Doppman JL, Conkle DM, Flye MW, Rosenberg SA. Comparison of computed and conventional whole lung tomography in detecting pulmonary nodules: a prospective radiologic-pathologic study. *AJR Am J Roentgenol* 1978; 131 (1): 51-4.
31. Friedmann G, Bohndorf K, Kruger J. Radiology of pulmonary metastases: comparison of imaging techniques with operative findings. *Thorac Cardiovasc Surg* 1986; 34 Spec No 2:120-4.
32. McCloud TC, Meyer JE. Mediastinal metastases. *Radiol Clin North Am*. 1982; 20 (3): 453-68.

33. Remy-Jardin M, Remy J, Giraud F, Marquette CH. Pulmonary nodules: detection with thick-section spiral CT versus conventional CT. *Radiology* 1993; 187 (2): 513-20.
34. Lucas JD, O'Doherty MJ, Wong JC, Bingham JB, McKee PH, Fletcher CD, Smith MA. Evaluation of fluorodeoxyglucose positron emission tomography in the management of soft-tissue sarcomas. *J Bone Joint Surg Br* 1998; 80 (3): 441-7.
35. Baumgartner WA, Mark JB. Metastatic malignancies from distant sites to the tracheobronchial tree. *J Thorac Cardiovasc Surg* 1980; 79 (4): 499-503.
36. King DS, Castleman B. Bronchial involvement in metastatic pulmonary malignancy. *J Thorac Cardiovasc Surg* 12: 305-315, 1943.
37. Heitmiller RF, Marasco WJ, Hruban RH, Marsh BR. Endobronchial metastasis. *J Thorac Cardiovasc Surg* 1993; 106 (3): 537-42.
38. Roviroso Casino A, Bellmunt J, Salud A, Vicente P, Maldonado J, Bodi R, Salvador L. Endobronchial metastases in colorectal adenocarcinoma. *Tumori* 1992; 78 (4): 270-3.
39. Ferson PF, Landreneau RJ, Keenan RJ. Thoracoscopy: General principles and diagnostic procedures. In Baue AE (ed). *Glenn's Thoracic and Cardiovascular Surg*. Stamford Connecticut, Appleton & Langr, 1996, pp 191-205.
40. Johnston MR, Grondin S. The role of endoscopy in the staging and management of lung metastases. *Chest Surg Clin N Am* 1998; 8 (1): 49-58.
41. Sadoff JD, Detterbeck FC. Pulmonary metastases from extrapulmonary cancer. *Diagnosis and treatment of Lung Cancer an Evidence-Based Guide for the Practicing Clinician*. By W.B. Saunders Company. 2001, 453.
42. Vogt- Moykopf I, Krysa S, Bulzebruck H, Schirren J. Surgery for pulmonary metastases. The Heidelberg experience. *Chest Surg Clin N Am* 1994; 4 (1): 85-112.
43. Baeza OR, Foster ED. Vertical axillary thoracotomy: a functional and cosmetically appealing incision. *Ann Thorac Surg* 1976; 22 (3): 287-8.
44. Ginsberg RJ. Alternative (muscle-sparing) incisions in thoracic surgery. *Ann Thorac Surg* 1993; 56 (3): 752-4.
45. Massimiano P, Ponn RB, Toole AL. Transaxillary thoracotomy revisited. *Ann Thorac Surg* 1988; 45 (5): 559-60.
46. Brulatti M, Tonielli E, Del Prete P, Gelsomini S, Briccoli A, Picci P, Guernelli N. The surgery of pulmonary metastases. The surgical indications and technical aspects of lung resections for metastases. *Minerva Chir* 1994; 49 (5): 413-22.
47. Hazelrigg SR, Naunheim K, Auer JE, Seifert PE. Combined median sternotomy and video-assisted thoracoscopic resection of pulmonary metastases. *Chest* 1993; 104 (3): 956-8.
48. Gilbert JC, Powell DM, Hartman GE, Seibel NL, Newman KD. Video-assisted thoracic surgery (VATS) for children with pulmonary metastases from osteosarcoma. *Ann Surg Oncol* 1996; 3 (6): 539-42.
49. Quaglia MPL. Osteosarcoma. Specific tumor management and results. *Chest Surgery Clinics of North America*, Feb 1998, 92.
50. Ferson PF, Landreneau RJ, Keenan RJ. Thoracoscopy. General principles and diagnostic procedures. In Baus AE (ed). *Glenn's Thoracic and Cardiovascular Surgery*. Stamford Connecticut, Appleton & Lange 1996, pp 191-205.
51. Kodama K, Doi O, Higashiyama M, Tatsuta M, Iwanaga T. Surgical management of lung metastases. Usefulness of resection with the neodymium:yttrium-aluminum-garnet laser with median sternotomy. *J Thorac Cardiovasc Surg* 1991; 101 (5): 901-8.
52. Branscheid D, Krysa S, Wollkopf G, Bulzebruck H, Probst G, Horn M, Schirren J, Vogt-Moykopf I. Does ND-YAG laser extend the indications for resection of pulmonary metastases? *Eur J Cardiothorac Surg* 1992; 6 (11): 590-6.
53. Miyamoto H, Masaoka T, Hayakawa K, Hata E. Application of the Nd-YAG laser for surgical resection of pulmonary metastases. *Kyobu Geka* 1992; 45 (1): 56-9.
54. Landreneau RJ, Herlan DB, Johnson JA, Boley TM, Nawarawong W, Ferson PF. Thoracoscopic neodymium: yttrium-aluminum garnet laser-assisted pulmonary resection. *Ann Thorac Surg* 1991; 52 (5): 1176-8.

55. Harvey JC, Lee K, Beattie EJ. Surgical management of pulmonary metastases. *Chest Surg Clin N Am* 1994; 4(1): 55-66.
56. Kern KA, Pass HI, Roth JA. Surgical treatment of pulmonary metastases. In Resenberg SA (ed). *Surgical treatment of metastatic cancer*. Philadelphia, JB Lippincott, 1988, pp 69-100.
57. Pastorino U, Grunewald D. pulmonary metastases. In *Thoracic surgery by pearson FG, Cooper JD, Deslauriers J, Ginsberg RJ, Hiebert CA, Alexander Patterson G, Urschel Jr HC, 2002, Churchill Livingstone: 966.*
58. Spender H. *pathology of the lung (excluding pulmonary tuberculosis)*. Oxford, Pergamon Press, 1985.
59. Willis RA. *The spread of tumors in the human body*, ed 3. London, Butterworths &Co, LTD, 1973.
60. Gilbert HA, Kagan AR. Metastasis: Incidence, detection, and evaluation without histologic confirmation. In Weiss L (ed). *Fundamental Aspects of Metastases*. Amsterdam, North-Holland, 1976.
61. Quaglia MPL. Osteosarcoma. Specific tumor management and results. *Chest Surgery Clinics of North America*, Feb 1998, 80.
62. Korholz D, Wirtz I, Vosberg H, Ruther W, Jurgens H, Gobel U. The role of bone scintigraphy in the follow-up of osteogenic sarcoma. *Eur J Cancer* 1996; 32A(3): 461-4.
63. Potter DA, Glenn J, Kinsella T, Glatstein E, Lack EE, Restrepo C, White DE, Seipp CA, Wesley R, Rosenberg SA. Patterns of recurrence in patients with high-grade soft-tissue sarcomas. *J Clin Oncol* 1985; 3(3): 353-66.
64. van Geel AN, Hoekstra HJ, van Coevorden F, Meyer S, Bruggink ED, Blankensteijn JD. Repeated resection of recurrent pulmonary metastatic soft tissue sarcoma. *Eur J Surg Oncol* 1994; 20 (4): 436-40.
65. Casson AG, Putnam JB, Natarajan G, Johnston DA, Mountain C, McMurtrey M, Roth JA. Five-year survival after pulmonary metastasectomy for adult soft tissue sarcoma. *Cancer* 1992; 69 (3): 662-8.
66. Jablons D, Steinberg SM, Roth J, Pittaluga S, Rosenberg SA, Pass HI. Metastasectomy for soft tissue sarcoma. Further evidence for efficacy and prognostic indicators. *J Thorac Cardiovasc Surg* 1989; 97 (5): 695-705.
67. Putnam JB Jr, Roth JA, Wesley MN, Johnston MR, Rosenberg SA. Analysis of prognostic factors in patients undergoing resection of pulmonary metastases from soft tissue sarcomas. *J Thorac Cardiovasc Surg* 1984; 87 (2): 260-8.
68. [No authors listed] Long-term results of lung metastasectomy: prognostic analyses based on 5206 cases. The International Registry of Lung Metastases. *J Thorac Cardiovasc Surg* 1997; 113 (1): 37-49.
69. Belli L, Scholl S, Livartowski A, Ashby M, Palangie T, Levasseur P, Pouillart P. Resection of pulmonary metastases in osteosarcoma. A retrospective analysis of 44 patients. *Cancer* 1989; 63 (12): 2546-50.
70. August DA, Ottow RT, Sugarbaker PH. Clinical perspective of human colorectal cancer metastasis. *Cancer Metastasis Rev* 1984; 3(4): 303-24.
71. McCormack PM, Burt ME, Bains MS, Martini N, Rusch VW, Ginsberg RJ. Lung resection for colorectal metastases. 10-year results. *Arch Surg* 1992; 127 (12): 1403-6.
72. Spaggiari L, Grunenwald D, Regnard JF. Resection of hepatic and pulmonary metastases in patients with colorectal carcinoma. *Cancer* 1998; 83 (5): 1049-51.
73. Okumura S, Kondo H, Tsuboi M, Nakayama H, Asamura H, Tsuchiya R, Naruke T. Pulmonary resection for metastatic colorectal cancer: experiences with 159 patients. *J Thorac Cardiovasc Surg* 1996; 112 (4): 867-74.
74. Dwight RW, Higgins GA, Keehn RJ. Factors influencing survival after resection in cancer of the colon and rectum. *Am J Surg* 1969; 117 (4): 512-22.
75. [No authors listed] Adjuvant therapy of colon cancer--results of a prospectively randomized trial. Gastrointestinal Tumor Study Group. *N Engl J Med* 1984; 310 (12): 737-43.
76. Higgins GA. Current status of adjuvant therapy in the treatment of large bowel cancer. *Surg Clin North Am* 1983; 63 (1): 137-50.
77. Higgins GA, Lee LE, Dwight RW. The case for adjuvant fluorouracil in colorectal cancer. *Cancer Clin trials* 1: 35-42, 1987.

78. Quentmeier A, Archlag P, Herfarth C. Key role of the CEA test in the diagnosis and surgical therapy of recurrent colorectal cancer. *Chirurg* 57(2): 83-87, 1986.
79. Umehara Y, Kimura T, Yoshida M, Oba N, Harada Y. Comparison of doubling times of serum carcinoembryonic antigen produced by various metastatic lesions in recurrent gastric and colorectal carcinomas. *Cancer* 1993; 71 (12): 4055-9.
80. McAfee MK, Allen MS, Trastek VF, Ilstrup DM, Deschamps C, Pairolero PC. Colorectal lung metastases: results of surgical excision. *Ann Thorac Surg* 1992; 53 (5): 780-5; discussion 785-6.
81. Maldazys JD, deKernion JB. Prognostic factors in metastatic renal carcinoma. *J Urol* 1986; 136(2): 376-9.
82. Cerfolio RJ, Allen MS, Deschamps C, Daly RC, Wallrichs SL, Trastek VF, Pairolero PC. Pulmonary resection of metastatic renal cell carcinoma. *Ann Thorac Surg* 1994; 57 (2): 339-44.
83. Pogrebniak HW, Haas G, Linehan WM, Rosenberg SA, Pass HI. Renal cell carcinoma: resection of solitary and multiple metastases. *Ann Thorac Surg* 1992; 54 (1): 33-8.
84. Harvey JC, Lee K, Beattie EJ. Surgical management of pulmonary metastases. *Chest Surg Clin N Am* 1994; 4 (1): 55-66.
85. Vogt-Moykopf I, Krysa S, Bulzebruck H, Schirren J. Surgery for pulmonary metastases. The Heidelberg experience. *Chest Surg Clin N Am* 1994; 4(1): 85-112.
86. Murphy BR, Breeden ES, Donohue JP, Messemer J, Walsh W, Roth BJ, Einhorn LH. Surgical salvage of chemorefractory germ cell tumors. *J Clin Oncol* 1993; 11 (2): 324-9.
87. Carsky S, Ondrus D, Schnorrer M, Majek M. Germ cell testicular tumours with lung metastases: chemotherapy and surgical treatment. *Int Urol Nephrol* 1992; 24(3): 305-11.
88. Einhorn LH, Williams SD, Mandelbaum I, Donohue JP. Surgical resection in disseminated testicular cancer following chemotherapeutic cytoreduction. *Cancer* 1981; 48 (4): 904-8.
89. Bracken RB, Johnson DE, Frazier OH, Logothetis CJ, Trindade A, Samuels ML. The role of surgery following chemotherapy in stage III germ cell neoplasms. *J Urol* 1983; 129 (1): 39-43.
90. Lotz JP, Andre T, Donsimoni R, Firmin C, Bouleuc C, Bonnak H, Merad Z, Estes A, Gerota J, Izrael V. High dose chemotherapy with ifosfamide, carboplatin, and etoposide combined with autologous bone marrow transplantation for the treatment of poor-prognosis germ cell tumors and metastatic trophoblastic disease in adults. *Cancer* 1995; 75 (3): 874-85.
91. Morgentaler A, Garnick MB, Richie JP. Metastatic testicular teratoma invading the inferior vena cava. *J Urol* 1988; 140 (1): 149-50.
92. Puc HS, Heelan R, Mazumdar M, Herr H, Scheinfeld J, Vlamis V, Bajorin DF, Bosl GJ, Mencil P, Motzer RJ. Management of residual mass in advanced seminoma: results and recommendations from the Memorial Sloan-Kettering Cancer Center. *J Clin Oncol* 1996; 14 (2): 454-60.
93. Tafra L, Dale PS, Wanek LA, Ramming KP, Morton DL. Resection and adjuvant immunotherapy for melanoma metastatic to the lung and thorax. *J Thorac Cardiovasc Surg* 1995; 110 (1): 119-28; discussion 129.
94. Harpole DH Jr, Johnson CM, Wolfe WG, George SL, Seigler HF. Analysis of 945 cases of pulmonary metastatic melanoma. *J Thorac Cardiovasc Surg* 1992; 103 (4): 743-8; discussion 748-50.
95. Atkins MB, O'Boyle KR, Sosman JA, Weiss GR, Margolin KA, Ernest ML, Kappler K, Mier JW, Sparano JA, Fisher RI, et al. Multiinstitutional phase II trial of intensive combination chemoimmunotherapy for metastatic melanoma. *J Clin Oncol* 1994; 12 (8): 1553-60.
96. Khayat D, Borel C, Tourani JM, Benhammouda A, Antoine E, Rixe O, Vuillemin E, Bazex PA, Thill L, Franks R, et al. Sequential chemoimmunotherapy with cisplatin, interleukin-2, and interferon alfa-2a for metastatic melanoma. *J Clin Oncol* 1993; 11(11): 2173-80.
97. Legha SS, Ring S, Papadopoulos N, Plager C, Chawla S, Benjamin R. A prospective evaluation of a triple-drug regimen containing cisplatin, vinblastine, and dacarbazine

- (CVD) for metastatic melanoma. *Cancer* 1989; 64 (10): 2024-9.
98. O'Day SJ, Boasberg P, Gua M, et al. Phase II trial of concurrent biochemotherapy (c-BC) with decreasing interleukin-2 (d-IL-2), tamoxifen (T), and G-CSF support in patients with metastatic melanoma (MM). *Proc AM Soc Clin Oncol* 1997; 16: 490a.
99. Richards JM, Mehta N, Ramming K, Skosey P. Sequential chemoimmunotherapy in the treatment of metastatic melanoma. *J Clin Oncol* 1992; 10 (8): 1338-43.
100. Thompson J, Gold P, Fefer A. outpatient chemoimmunotherapy for patients with metastatic melanoma. *Proc Am Soc Clin Oncol* 1996; 15: 433.
101. Abolhoda A, Brooks A, Nawata S, Kaneda Y, Cheng H, Burt ME. Isolated lung perfusion with doxorubicin prolongs survival in a rodent model of pulmonary metastases. *Ann Thorac Surg* 1997; 64 (1): 181-4.
102. Weksler B, Blumberg D, Lenert JT, Ng B, Fong Y, Burt ME. Isolated single-lung perfusion with TNF-alpha in a rat sarcoma lung metastases model. *Ann Thorac Surg* 1994; 58 (2): 328-31; discussion 332.
103. Weksler B, Lenert J, Ng B, Burt M. Isolated single lung perfusion with doxorubicin is effective in eradicating soft tissue sarcoma lung metastases in a rat model. *J Thorac Cardiovasc Surg* 1994; 107 (1): 50-4.
104. Pastorino U, Valente M, Gasparini M, Azzarelli A, Santoro A, Tavecchio L, Casali P, Ravasi G. Median sternotomy and multiple lung resections for metastatic sarcomas. *Eur J Cardiothorac Surg* 1990; 4 (9): 477-81.
105. Pastorino U, Valente M, Muscolino G, et al. Muscle-sparing anterolateral thoracotomy for pulmonary or mediastinal resections. In Motta G (ed): Lung Cancer Frontiers in Science and Treatment. Genos, Grafica LP, 1994, p 337.
106. Pastorino U, Buyse M, Friedal et al. for the international registry of lung metastases: Long-term results of lung metastasectomy: Prognostic analyses based on 5, 206 cases. *J Thorac Cardiovasc Surg* 1997; 113: 37.
107. Pastorino U, Gasparini M, Tavecchio L, Azzarelli A, Mapelli S, Zucchi V, Morandi F, Bellani FF, Valente M, Ravasi G. The contribution of salvage surgery to the management of childhood osteosarcoma. *J Clin Oncol* 1991; 9 (8): 1357-62.
108. Pastorino U, McCormack PM, Ginsberg RJ. A new staging proposal for pulmonary metastases. The results of analysis of 5206 cases of resected pulmonary metastases. *Chest Surg Clin N Am* 1998; 8 (1): 197-202.

مراجع فارسی:

۱. بازرگانی، رامین. یک مورد کانسر پستان با متاستاز به ریه در بیمار مذکر. به راهنمایی حبیبی، مینو. دانشگاه علوم پزشکی شهید بهشتی، دانشکده پزشکی، ۱۳۷۲، دکترای پزشکی عمومی.
۲. حیدری، مرتضی. بهار صفت، مجید. جراحی و شیمی درمانی در متاستازهای ریوی، بررسی بیماران بیمارستان حضرت رسول اکرم (ص) در سالهای ۷۵-۶۹. به راهنمایی: مشگ گو، مجید. دانشگاه علوم پزشکی ایران، دانشکده پزشکی، ۱۳۷۵. دکترای پزشکی عمومی.
۳. رجب پور نیکنام، فاطمه. کارسینومهای تیروئید در اطفال و گزارش یک مورد متاستاز پاپیلری کارسینومای تیروئید به ریه در یک کودک. به راهنمایی: جدلی، فرزانه. دانشگاه علوم پزشکی شهید بهشتی، دانشکده پزشکی، ۱۳۷۱. دکترای پزشکی عمومی.
۴. اصغری زاده، فرزاد. بررسی پاتولوژیکی بدخیمیهای ریوی در سالهای ۷۴-۱۳۷۲ در مرکز پزشکی امام خمینی (ره) تبریز.
۵. جواد نژاد، جلال. بررسی تومورهای ریوی در ۶ ماهه اول سال ۱۳۷۲ در بیمارستانهای لقمان حکیم، مسیح دانشوری، شهید مدرس، امام خمینی. به راهنمایی: پناهی، منصور. دانشگاه علوم پزشکی شهید بهشتی، دانشکده پزشکی، ۱۳۷۳. دکترای پزشکی عمومی.

۶. خرم کوهی، شهلا. تعیین فراوانی فرم‌های هیستولوژیک تومورهای خوش خیم و بدخیم ریه در نمونه های ارسالی به مرکز پاتولوژی دانشگاه علوم پزشکی اصفهان از سال ۶۷ تا ۷۳. به راهنمایی: مهدیزاده، مژگان. دانشگاه علوم پزشکی کاشان، دانشکده پزشکی، ۱۳۷۳. دکترای پزشکی عمومی.
۷. غفاری مهر، حسین. نئوپلاسم‌های متاستاتیک ریه. به راهنمایی: ناسی‌زاده، محمدرضا. دانشگاه علوم پزشکی تبریز، دانشکده پزشکی، ۱۳۶۹. دکترای پزشکی عمومی.
۸. مافی‌نژاد، اصغر. علوی، مجید. تومورهای متاستاتیک ریه و بررسی موارد ۱۵ ساله اخیر در بیمارستان قائم. به راهنمایی: حقی، ضیاء‌الدین. دانشگاه آزاد اسلامی مشهد، دانشکده پزشکی، ۱۳۷۴. دکترای پزشکی عمومی.
۹. رجبی، پروین. گزارش یک مورد متاستاز تومور بدخیم در تومور خوش خیم. مجله دانشکده پزشکی اصفهان. ۱۳۷۲. سال ۱۱ (۳۷): ۴۹-۴۷.
۱۰. توحیدی، محمد. صادقی‌انارکی، یزدان. متاستاز آندوبرونش در آمبریونال سل کارسینومای بیضه و معرفی یک مورد. مجله دانشکده پزشکی دانشگاه علوم پزشکی مشهد. ۱۳۷۱. سال ۳۵ (۴۰): ۱۰۹-۱۰۶.
۱۱. عباسی دزفولی، عزیزاله. نقش متاستاتیکتومی در استئوسارکوم. سمینار یکروزه کارسینوم استئوژنیک، تهران ۱۵ اسفند ۱۳۸۱، بیمارستان دکتر شریعتی تهران.