

Tanaffos (2005) 4(13), 39- 45

©2005 NRITLD, National Research Institute of Tuberculosis and Lung Disease, Iran

Localized Fibrous Tumors of the Pleura: Diagnosis, Clinical and Surgical Management

Manoochehr Aghajanzadeh ¹, Seyed Ali Alavi ², Hossin Amani ², Seba Hoda ³

¹Department of Thoracic surgery, ²Department of Pulmonary Medicine, ³ Department of Pathology, Razi Hospital, Rasht, Guilan University of Medical Sciences and Health Services, RASHT-IRAN.

ABSTRACT

Background: Localized fibrous tumours of the pleura are very rare. The aim of this case series study is to define clinical feature and determine the optimal treatment and surgical outcome of these tumours.

Materials and Methods: The records of 6 consecutive patients with localized fibrous tumours of the pleura, who were operated between 1994 and 2002, were retrospectively reviewed. Diagnostic procedure, clinical courses, surgical management and outcomes of these patients were studied.

Results: 6 patients were enrolled in the study (4 men, 2 women, mean age 41 yrs). All patients were symptomatic at the time. Chest pain, dyspnea and cough were the most common symptoms; CXR and CAT- scan were performed for all patients. Resection was performed through postero-lateral thoracotomy in all patients. Five cases had benign and one had malignant tumour. Local recurrence occurred in 1 patient. One case died because of malignant tumour during a 5-year follow-up.

Conclusion: Although localized fibrous tumors of the pleura are histologically considered as benign tumors, because of the risk of recurrence and malignant transformation, complete resection is indicated and long-term follow-up is recommended in all patients. (*Tanaffos* 2005; 4(13): 39-45)

Key words: Mesothelioma. Fibrous tumour, Fibroma, Fibrosarcoma

INTRODUCTION

Localized fibrous tumors of the pleura (LFTP) are rare tumors that are considered to develop from submesothelial connective tissue (1). Since its pathologic characteristics were first described by Klemperer et al. in 1992(2), the nomenclature has been confusing, and the disease has been referred to as a localized mesothelioma, localized fibrous tumor, fibrous mesothelioma or pleural fibroma (3). Further development of electronic microscopy and

immunohistochemistry has clarified that the tumor does not originate from mesothelial layer but from the submesothelial, noncommitted mesenchymal layer.(4,5,6,7). Thus, various terms used for this disease have become unified and now the disease is referred to as solitary or localized fibrous tumors of the pleura (8,9). Mesenchyma is a pluripotent tissue and possesses the potential to differentiate to bone, cartilage or blood vessels. Because of this diversity of the mesenchyme, the pathology and morphology of LFTP appear variable (5). Steinetz and their

Correspondence to: Alavi SA

Tel:+98-131-77723789

Email address: aalavi_foumani@yahoo.com

colleagues, have supported this concept of the mesenchymal origin of both the benign and malignant localized fibrous tumors of the pleura (10).

The LFTP can usually be distinguished from malignant mesothelioma by their radiographic features, (11) gross appearance (often pedunculated), immunohistologic characteristic and ultrastructural characteristic (12). Thirteen percent of reported tumors had aggressive clinical behavior with local infiltration and local recurrence. The remaining 87% had benign clinical behavior and were resected completely, including the adjacent structures if necessary, which is generally believed to be a sufficient treatment (13). Although complete surgical resection of benign LFTP is the usual method of cure, occasional reports advise caution concerning its unpredictable clinical behavior such as its invasion to adjacent organ or cardiac compression by the huge mass of benign LFTP (14,15). The aim of this research was to study the clinical behavior and surgical outcome of these tumors.

MATERIALS AND METHODS

We retrospectively reviewed the clinical records of patients who had undergone surgical resection for benign and malignant LFTP from 1992 to 2002 by one team in Rasht, Razi hospital, Guilan University of Medical Sciences, (GUMS). History taking, physical examination, routine blood tests, CXR, C.T scan, EKG, were performed for all patients.

Six patients were enrolled in the study (4 men, 2 women, mean age: 41 years).

RESULTS

The symptoms were chest pain in 5 patients, dyspnea in 4 patients and cough in 3 patients. On physical examination, dullness to percussion and absence of breath sounds in the ipsilateral hemithorax were detected in all patients. Table 1 shows characteristics of the patients. CXR and computed tomography revealed well circumscribed,

heterogeneous, hypodense soft tissue masses in most cases and in one patient calcification was detected in the mass. Pleural effusion was detected in 3 patients. Fiberoptic bronchoscopy was performed in 4 patients, in all of them extrinsic compression of segmental bronchi was observed. However, no endobronchial lesion was detected. Thoracentesis and transthoracic needle biopsy were done in all patients but the result was not diagnostic. Four left and two right posterolateral thoracotomies were performed in six patients. Reoperation was needed in 1 patient after two years because of tumor recurrence. In 5 patients, having pedunculated tumors arising from visceral pleura, total excision was performed easily. Because of mild fibrous adhesions, only in one patient, who had a giant and multiple mass, left upper lobectomy was performed. Fig 1,2: indicates chest computed tomography revealing a mass in the pleural space. Fig 3 shows chest computed tomography which revealed multiple masses on the parietal pleura with calcification.

Table 1. Characteristics of the patients.

Number	sex	age	Asbestos	Tumor size	Histology	Operation
1	F	20	No	30×20	Benign	Thoracotomy (L)
2	M	65	No	25×20	Benign	Thoracotomy (R)
3	F	54	No	22×20	Benign	Thoracotomy (L)
4	F	62	No	20×15	Benign	Thoracotomy (L)
5	M	68	Yes	15×10	Malignant	Toracotomy (R)
6	M	45	No	17×15	Benign	Toracotomy (L)

The largest mass in our patients was 25x20x15 cm and weighed 3350g. The smallest was 10x8x6 cm. Five patients had benign and 1 had malignant localized fibrous tumor of the pleura. Postoperative radiotherapy was used in only one patient who had recurrence after reoperation. One patient died during follow-up (2 to 5 years) because of

malignancy. Others are alive and do not show any complication or recurrences.

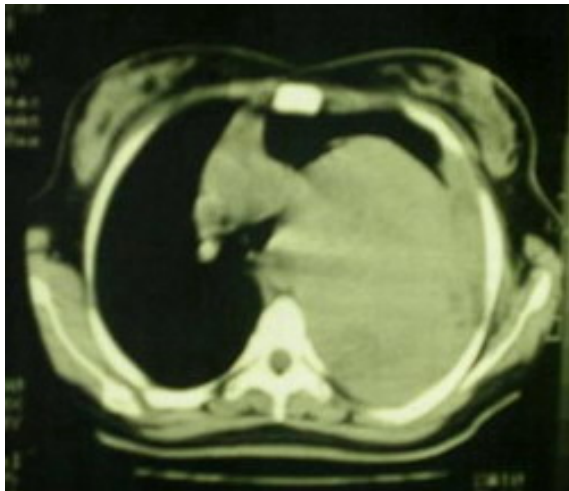
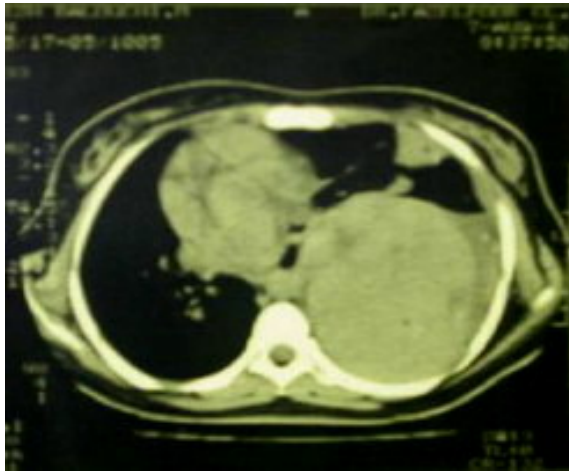


Figure 1,2). CT- scan of the patients with left side LFTP.

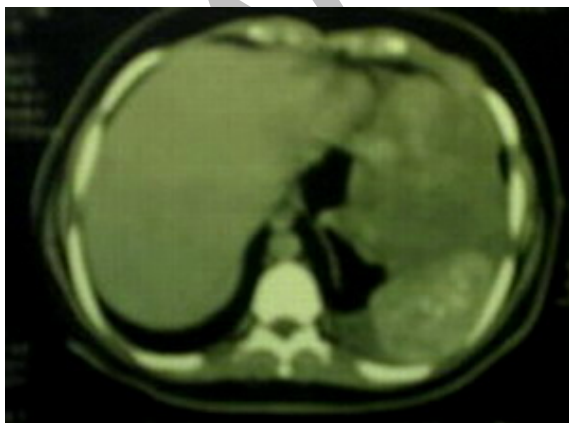


Figure 3. CT- scan of a patient with LFTP and calcification.

DISCUSSION

Localized fibrous tumors of the pleura are uncommon accounting for 8% of benign pathologic diseases of the chest and 10% of pleural neoplasms (2, 16). Approximately 800 cases of LFTP have been reported in the medical literature between 1931 and 2002 (15). Greatest occurrence is in the fourth to sixth decades (3, 16). It is believed that a history of asbestosis is lacking in patients with LFTP (17). In early stages localized fibrous tumors of the pleura are asymptomatic and are discovered on routine chest radiography (9,11). Solitary fibrous tumors of the pleura can present with various kinds of symptoms such as intrathoracic symptoms (dyspnea, chest pain, cough, and hemoptysis). Extra thoracic manifestation can include arthralgia, digital clubbing (hypertrophic osteoarthropathy), hypoglycemia and galactorrhea (18, 19) or nonspecific symptoms (fever, weight loss, and fatigue). The proportion of symptomatic patients is larger in case of malignant LFTP (15, 20). Possible cause may be erosion of adjacent structure by invasion or peritumoural adhesion and paracrine action of unknown factors secreted by LFTP (11).

Radiologically, LFTP appears as a solitary, sharp defined or lobulated mass at the periphery of the lung with no evidence of invasion, with or without pleural effusion. The radiologic's impression are considered to surgical extend. One of these findings may be the atypical images produced by a malignant LFTP showing invasion, severe peritumoural adhesion, necrosis or hemorrhage. These atypical images differ from images of typical, well - circumscribed pleural tumor (15). If a LFTP originates from interlobar visceral pleura appears as pulmonary mass rather than a pleural tumor (14, 21). The radiological manifestation strongly favoring LFTP can be used as a predicting factor for the extend of the disease preoperatively. Preoperative pathologic FNA

diagnosis is not recommended in LFTP. Because of the hypercellular nature of the tumor, it is usually difficult to obtain sufficient material for cytology and analysis (15, 22), Weyand and colleagues reported that Transthoracic core needle biopsies with cutting needle were often definitive for diagnosis of LFTP (23). Because surgical resection involves simultaneous diagnosis and treatment, preoperative FNA should not be considered. Surgical resection for diagnosis and treatment is accepted only for operable patients, because the risk of mortality and morbidity are very low. At least repeated FNA is not required even if a definitive preoperative pathologic diagnosis is not obtained, although there was a report of two cases in which diagnosis was obtained by fine-needle aspiration biopsy which was published (16). The reported incidence of malignant LFTP varies from 7% to 60%. Although some authors advocate that number of mitoses is the most significant criteria for malignant LFTP, useful immunohistochemical prognostic markers of malignant LFTP are still being investigated (15, 24). Macroscopically, tumors are round, or ovoid, encapsulated or sharply circumscribed and attached to the visceral pleura often by a pedicle (13).

Size of the tumor has been reported to be from 1 to 39 cm and the average weight was 100 to 400g. However, tumors greater than 10 cm are more likely to be malignant (15, 26).

Perrot and colleagues (20) classified LFTP as benign pedunculated, benign sessile, malignant pedunculated, and malignant sessile; a classification on the basis of combination of gross morphologic features and histopathology. They reported significant differences in the recurrences and also in survivals of these different morphopathologic subtypes. Recurrences were reported to occur in 63% of those in the malignant sessile group, in 14% of the

malignant pedunculated group, in 8% of the benign sessile group, and in 2% of those in the benign pedunculated group (16). Local recurrence or distant metastasis occurred only in the malignant sessile type. Pleural effusion can be seen in both benign and malignant forms, but it usually indicates a greater likelihood of malignancy (8). Multiple tumors are extremely rare (24). In the series reported by Carrillo and coworkers multiple tumors were observed in 1.8% of the patients (25). The best treatment for these tumors is surgical excision; it is easy to perform total excision in most benign lesions. Approximately 10% of benign LFTP recur with malignant change rarely supervening (9,11). It was reported that 8 patients with a malignant tumor had recurrence or distant metastasis between 6 months and 8 years after initial resection (11). The best predictor of benign courses is complete excision with microscopically free surgical margin (20). We have observed one case of recurrence during the treatment of choice for benign LFTP which is complete surgical resection. However, as far as malignant LFTP cases are concerned, there is no established systemic therapy, either preoperatively or postoperatively, despite the fact that malignant LFTP has shown distant metastasis (13). Postoperative adjuvant radiotherapy, chemotherapy or both have been used sporadically (13, 15, 16). Isolated reports have recommended the use of postoperative radiotherapy, however there are no clear data confirming its benefit (15, 20). Radiotherapy was required in patients with second recurrence after reoperation. Because a small number of malignant LFTP patients showed improved survival, preoperative or postoperative systemic therapy should be considered in selected patients who are predicted to achieve a satisfactory result (15, 26).

Prognosis depends on the respectability and size

of the tumor, the number of mitoses, polymorphism, and necrosis in the tumor (11, 15, 16). In conclusion, complete resection and close follow – up for years after operations are recommended for LFTP patients.

REFERENCES

- Al-Azzi M, Thurlow NP, Corrin B. Pleural mesothelioma of connective tissue type, localized fibrous tumor of the pleura, and reactive submesothelial hyperplasia: An immunohistochemical comparison. *J Pathol* 1989;158(1):41-4.
- Klemperer P, Coleman BR. Primary neoplasms of the pleura: a report of five cases. *Am J Ind Med* 1992;22(1):1-31.
- de Perrot M, Fischer S, Brundler MA, Sekine Y, Keshavjee S. Solitary fibrous tumors of the pleura. *Ann Thorac Surg* 2002;74(1):285-93.
- Hernandez FJ, Hernandez BB. Localized fibrous tumors of the pleura: a light and electron microscopic study. *Cancer* 1974;34(5):1667-74.
- Hanau CA, Miettinen M. Solitary fibrous tumor: histological and immunohistochemical spectrum of benign and malignant variants presenting at different sites. *Hum Pathol* 1995;26(4):440-9.
- Suster S, Nascimento AG, Miettinen M, Sickel JZ, Moran CA. Solitary fibrous tumors of the soft tissue: A clinicopathologic and immunohistochemical study of 12 cases. *Am J Surg Pathol* 1995;19(11):1257-66.
- Hasegawa T, Hirose T, Seki K, Yang P, Sano T. Solitary fibrous tumor of the soft tissue. An immunohistochemical and ultrastructural study. *Am J Clin Pathol* 1996;106(3):325-31.
- Okike N, Bernatz PE, Woolner LB. Localized mesothelioma of the pleura: benign and malignant variants. *J Thorac Cardiovasc Surg* 1978; 75 (3): 363- 72.
- Briselli M, Mark EJ, Dickersin GR. Solitary fibrous tumors of the pleura: eight new cases and review of 360 cases in the literature. *Cancer* 1981;47:2678-2689. 1996;106:325-31.
- Steinetz C, Clarke R, Jacobs GH, Abdul-Karim FW, Petrelli M, Tomaszefski JF Jr. Localized fibrous tumors of the pleura: correlation of histopathological, immunohistochemical and ultrastructural features. *Pathol Res Pract* 1990;186(3):344-57.
- Magdeleinat P, Alifano M, Petino A, Le Rochais JP, Dulmet E, Galateau F, et al. Solitary fibrous tumors of the pleura: clinical characteristics, surgical treatment and outcome. *Eur J Cardiothorac Surg* 2002; 21(6):1087-93.
- Carter D, Otis CN. Three types of spindle cell tumors of the pleura. Fibroma, sarcoma, and sarcomatoid mesothelioma. *Am J Surg Pathol* 1988;12(10):747-53.
- Altinok T, Topcu S, Tastepe AI, Yazici U, Cetin G. Localized fibrous tumors of the pleura: clinical and surgical evaluation. *Ann Thorac Surg* 2003;76(3):892-5.
- Shaker W, Meatchi T, Dusser D, Riquet M. An unusual presentation of solitary fibrous tumour of the pleura: right atrium and inferior vena cava compression. *Eur J Cardiothorac Surg* 2002;22(4):640-2.
- Sook Hwan Sung MD, Jee won Chang MD, Jhingook Kim MD. Solitary Fibrous tumor of the pleura: Surgical outcome and clinical course. *Ann Thorac surg* 2005; 79(1): 303- 7.
- Rena O, Filosso PL, Papalia E, Molinatti M, Di Marzio P, Maggi G, et al. Solitary fibrous tumour of the pleura: surgical treatment. *Eur J Cardiothorac Surg* 2001;19(2):185-9.
- England DM, Hochholzer L, McCarthy MJ. Localized benign and malignant fibrous tumors of the pleura. A clinicopathologic review of 223 cases. *Am J Surg Pathol* 1989 ;13(8):640-58. Erratum in: *Am J Surg Pathol* 1991;15(8):818.
- Shneerson JM. Digital clubbing and hypertrophic osteoarthropathy: The underlying mechanisms. *Br J Dis Chest* 1981;75(2):113-31.
- Nelson R, Burman SO, Kiani R, Chertow BS, Shah J, Cantave I. Hypoglycemic coma associated with benign pleural mesothelioma. *J Thorac Cardiovasc Surg* 1975;69(2):306-14.
- de Perrot M, Kurt AM, Robert JH, Borisch B, Spiliopoulos

- A. Clinical behavior of solitary fibrous tumors of the pleura. *Ann Thorac Surg* 1999;67(5):1456-9.
21. Nonaka M, Kadokura M, Takaba T. Benign solitary fibrous tumor of the parietal pleura which invaded the intercostal muscle. *Lung Cancer* 2001; 31 (2-3):325-9.
22. Drachenberg CB, Bourquin PM, Cochran LM, Burke KC, Kumar D, White CS, et al. Fine needle aspiration biopsy of solitary fibrous tumors. Report of two cases with histologic, immunohistochemical and ultrastructural correlation. *Acta Cytol* 1998; 42 (4):1003-10.
23. Weynand B, Noel H, Goncette L, Noirhomme P, Collard P. Solitary fibrous tumor of the pleura: a report of five cases diagnosed by transthoracic cutting needle biopsy. *Chest* 1997;112(5):1424-8.
24. Tastepe I, Alper A, Ozaydin HE, Memis L, Cetin G. A case of multiple synchronous localized fibrous tumor of the pleura. *Eur J Cardiothorac Surg* 2000; 18(4):491-4.
25. Cardillo G, Facciolo F, Carbone L, Regal M, Corzani F, Ricci A, et al. Long-term follow-up of video-assisted talc pleurodesis in malignant recurrent pleural effusions. *Eur J Cardiothorac Surg* 2002; 21(2):302-5; discussion 305-6.
26. Yokoi T, Tsuzuki T, Yatabe Y, Suzuki M, Kurumaya H, Koshikawa T, et al. Solitary fibrous tumour: significance of p53 and CD34 immunoreactivity in its malignant transformation. *Histopathology* 1998; 32 (5):423-32.

Archive of SID