

Tanaffos (2007) 6(4), 58-62

©2007 NRITLD, National Research Institute of Tuberculosis and Lung Disease, Iran

Idiopathic Subglottic Stenosis in a Pregnant Woman: Successful Treatment with Dilatation and Nd: YAG Laser Ablation

Hamid Reza Jabbar Darjani ^{1,2}, Tahereh Parsa ^{3,4}, Aydin Pirzeh ¹, Hassan Heydarnazhad ^{1,5}

¹ Department of Pulmonary Medicine, ² Tracheal Disease Research Center, ³ Department of Anesthesiology, ⁴ Telemedicine Research Center, ⁵ Tobacco Prevention and Control Research Center, NRITLD, Shahid Beheshti University M.C., TEHRAN-IRAN.

ABSTRACT

Idiopathic subglottic stenosis (ISS) is a rare progressive condition affecting young females. The cause is unknown and in some reports relation with anti-cytoplasmic antibodies (ANCA) and gastroesophageal reflux disease (GERD) has been reported. Surgical resection of stenotic area or dilatation with laser ablation are the main treatment options. We report a case of ISS in a five-month pregnant woman with gradual deterioration who was treated with dilatation by rigid bronchoscopy and laser ablation of excessive tissue. (Tanaffos 2007; 6(4): 58-62)

Key words: Subglottic stenosis, Idiopathic, Pregnancy, Dilatation, Laser

INTRODUCTION

Stenoses in the subglottic area of trachea have been reported in association with various conditions such as intubations, tracheostomy, trauma, Wegener's granulomatosis, sarcoidosis and gastroesophageal reflux disease (1-3). In the absence of any identifiable cause, the condition is called idiopathic subglottic stenosis (ISS). Subglottic stenosis has few medical challenges: 1) Rarity of this condition and high prevalence of asthma and chronic obstructive lung disease may cause delay in diagnosis and treatment. 2) Isolation of ISS (especially GERD related form) from other causes of subglottic stenoses has important therapeutic and preventive implications.

3) Controversies regarding surgical vs. non-surgical treatment with dilatation and laser ablation; and 4) Special complications of ISS in pregnancy. We report a case of ISS in a pregnant woman with deterioration in pregnancy, misdiagnosis and treatment for asthma for 3 years before diagnosis. Good early response to dilatation by rigid bronchoscope and laser ablation was obtained.

CASE REPORT

A 29-year-old female with a 3-year history of treatment for asthma with fluticazone and salmetrol was referred for increasing dyspnea after pregnancy.

On physical examination, she was 5-months pregnant with wheezing and stridor notable over the neck. Spirometry and flow volume loop showed decreased peak flow compared to FEV1 and typical flow volume loop of fixed upper airway obstruction (Figure 1).

Correspondence to: Heydarnazhad H

Address: NRITLD, Shaheed Bahonar Ave, Darabad, TEHRAN 19569,

P.O:19575/154, TEHRAN- IRAN

Email address: heidarnazhad@nritld.ac.ir

Received: 3 Sep 2007

Accepted: 27 Dec 2007

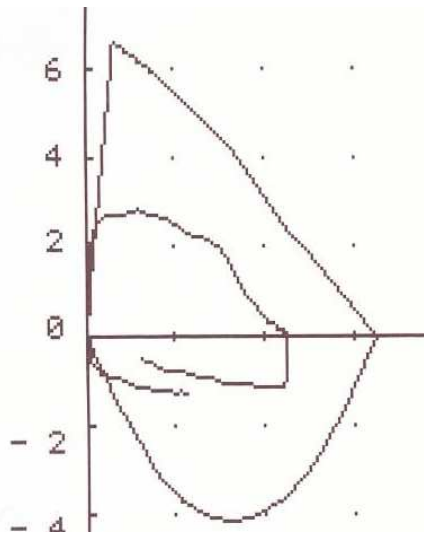


Figure 1. Spirometry before laser therapy

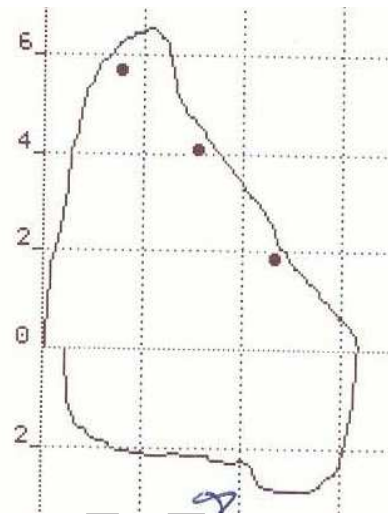


Figure 3. Spirometry after laser therapy.

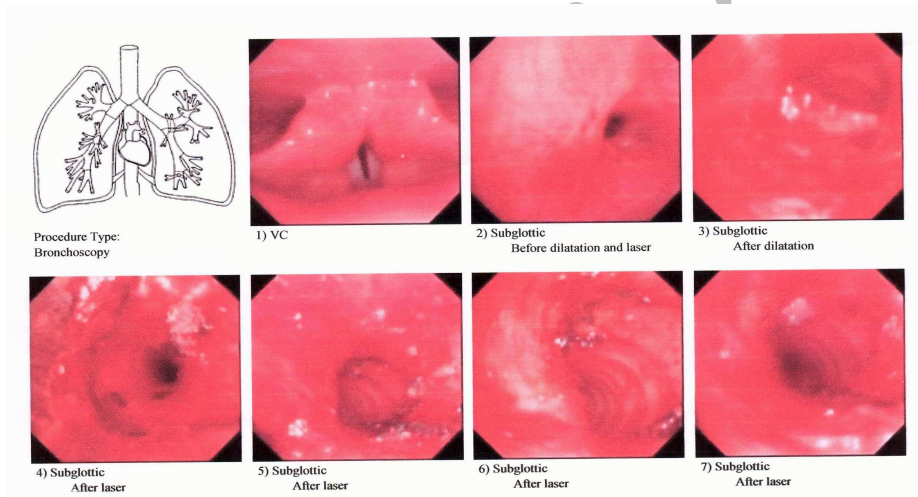


Figure 2. Bronchoscopy of patient before and after laser therapy.

Table 1. The pulmonary function tests of the patient before and after intervention

Date	PFT				Flow volume loop	6 Min walk (420 meter)
	FEV1	FVC	PEF			
09/07/2006	1.96(70%)	2.71(15%)	2.16(33%)		Fixed UAO	Sat 98→94% HR 116→149
30/09/2006	1.96(69%)	2.27(70%)	2.81(42%)		Fixed UAO	---
15/11/2006 after dilatation	2.92(107%)	3.18(102%)	6.49(101%)		Inspiratory limitation	PIF: 2.91(45%)
05/01/2007	2.58(95%)	3.01(96%)	5.14(79%)		Inspiratory limitation	PIF:3.15

Due to pregnancy no radiologic work up was done but on laryngoscopy, stenotic trachea 1 cm below the vocal cords was noticed. The patient denied any intubations or signs and symptoms of vasculitis and had no symptomatic gastroesophageal reflux disease.

Asthma medications were stopped and the patient was followed clinically. Complete blood counts, sedimentation rate, urinalysis, and tests for antineutrophil cytoplasmic antibodies (ANCA) were normal.

After 2 months, the patient referred with increasing dyspnea. New PFT showed deterioration of FVC; therefore, decision for intervention was made and the patient underwent graded dilatation by rigid bronchoscopy and then Nd-YAG laser ablation of excessive tissue under general anesthesia (Figure 2). She recovered without any complication and the new PFT two weeks later showed normal FEV1, PEF and slight limitation of inspiratory flow (PIF: 45%) (Figure 3 and Table 1).

DISCUSSION

The picture of stenotic lesions of the subglottic area and trachea has changed over the last 100 years. External trauma and infection are being supplanted by iatrogenic trauma from intubations and tracheostomy (1). Isolated stenosis of ISS differs from multiple level stenosis, because in the latter situation, the majority are due to previous intubations (3).

Our patient had several points to discuss. The first one is misdiagnosis of asthma with organic obstructive lesions of trachea which has been reported previously (4-6). Attention to harsh inspiratory or expiratory wheezing or stridor over the neck compared to peripheral regions of the lung, appearance of flow volume loop, more decrease in PEF compared to FEV1 and unresponsiveness to

regular anti-asthma medications are major points that physicians should rely on for differential diagnosis. Our patient had at least 3 years time lapse between presentation and final diagnosis.

The second problem was the differential diagnosis of ISS from other etiologies of subglottic stenoses (7). ISS is a rare disease and most patients are young or middle-aged women. This condition has been rarely reported in childhood (8). The rarity of ISS in the male population in reported series may be due to the genetic predispositions to this condition as Pizzutto reported subglottic stenosis in 2 of 3 premature male triplets; the affected infants were monozygotic (8). The relation between female gender and ISS has been established in previous reports (7,9,10) and is attributed to estrogen hormone as alteration in wound healing response has been noticed under estrogen effects (7). Other causes of subglottic stenosis have been reported in few series and intubations, high tracheostomy, and GERD comprise the majority of the causes and Wegener's granulomatosis and sarcoidosis rarely present as stenotic lesions in the subglottic area (2,3). Our patient had no history of intubation or tracheostomy and no signs of sarcoidosis or Wegener's granulomatosis, with normal laboratory tests.

The relationship between ISS and other subglottic stenoses due to GERD is another point. The majority of the patients with and without concomitant disease (sarcoidosis, Wegener's granulomatosis, laryngeal trauma, and post intubations) have established GERD by pH-metry (11), and in another report 14% of the patients had reflux disease (3). Our patient had no symptomatic reflux but due to pregnancy pH-metry was not possible; thus, we could not rule out the possibility of the correlation of ISS with reflux in our patient.

The last point relates to subglottic stenosis in

pregnant women. To our knowledge, only one case has been reported in the literature for whom elective surgical tracheostomy was performed before labor analgesia for severe subglottic tracheal stenosis (12). Our case was the first successful treatment of subglottic stenosis in pregnancy with dilatation and laser ablation of excessive tissue resulted in relief until delivery.

Due to the limitation of the stenotic area to the first two rings of the trachea, surgical resection with end to end anastomosis of the trachea is the preferred modality for treatment of ISS. (1, 2, 7, 13, 14)

Trials with dilatation and laser ablation have also been reported with temporary relief of stenosis, but most of these patients who have been treated without surgical resection faced recurrence during the follow-up period and were finally cured by surgery.(9,10,15-20)

Recent introduction of microdebrider bronchoscopy has had good results without procedure-related complications and no need for reoperation in the preliminary reports (21), and may become the procedure of choice in the future especially for rapid relief of central airway obstructive lesions.

CONCLUSION

Successful temporary relief of ISS in pregnancy is possible by non-surgical methods and can be tried without resort to tracheostomy or direct surgical resection in pregnant women. Long-term follow-up of these patients may be more informative.

REFERENCES

1. Lorenz RR. Adult laryngotracheal stenosis: etiology and surgical management. *Curr Opin Otolaryngol Head Neck Surg* 2003; 11 (6): 467- 72.
2. Couraud L, Jougon JB, Velly JF. Surgical treatment of nontumoral stenoses of the upper airway. *Ann Thorac Surg* 1995; 60 (2): 250- 9.
3. Poetker DM, Ettema SL, Blumin JH, Toohill RJ, Merati AL. Association of airway abnormalities and risk factors in 37 subglottic stenosis patients. *Otolaryngol Head Neck Surg* 2006; 135 (3): 434- 7.
4. Moue Y, Kuwahira I, Iwamoto T, Kamio K, Hayashi Y, Ohta Y. A case of idiopathic tracheal stenosis. *Nihon Kokyuki Gakkai Zasshi* 2000; 38 (11): 828- 30.
5. Baughman RP, Loudon RG. Stridor: differentiation from asthma or upper airway noise. *Am Rev Respir Dis* 1989; 139 (6): 1407- 9.
6. Kryger M, Bode F, Antic R, Anthonisen N. Diagnosis of obstruction of the upper and central airways. *Am J Med* 1976; 61 (1): 85- 93.
7. Valdez TA, Shapshay SM. Idiopathic subglottic stenosis revisited. *Ann Otol Rhinol Laryngol* 2002; 111 (8): 690- 5.
8. Pizzuto M, Donaldson D, Brodsky L. A role for genetic predisposition in subglottic stenosis. *Int J Pediatr Otorhinolaryngol* 1998; 44 (3): 279- 84.
9. Dedo HH, Catten MD. Idiopathic progressive subglottic stenosis: findings and treatment in 52 patients. *Ann Otol Rhinol Laryngol* 2001; 110 (4): 305- 11.
10. Benjamin B, Jacobson I, Eckstein R. Idiopathic subglottic stenosis: diagnosis and endoscopic laser treatment. *Ann Otol Rhinol Laryngol* 1997; 106 (9): 770- 4.
11. Maronian NC, Azadeh H, Waugh P, Hillel A. Association of laryngopharyngeal reflux disease and subglottic stenosis. *Ann Otol Rhinol Laryngol* 2001; 110 (7 Pt 1): 606- 12.
12. Kuczkowski KM, Benumof JL. Subglottic tracheal stenosis in pregnancy: anaesthetic implications. *Anaesth Intensive Care* 2003; 31 (5): 576- 7.
13. Grillo HC, Mathisen DJ, Wain JC. Laryngotracheal resection and reconstruction for subglottic stenosis. *Ann Thorac Surg* 1992; 53 (1): 54- 63.

14. George M, Lang F, Pasche P, Monnier P. Surgical management of laryngotracheal stenosis in adults. *Eur Arch Otorhinolaryngol* 2005; 262 (8): 609- 15.
15. Havas T, Dodd M, Weldon B, Benjamin B, Pigott P. A case report of subglottic stenosis. *Aust N Z J Surg* 1984; 54 (3): 291- 4.
16. Hans S, de Mones E, Biacabe B, Menard M, Laccourreye O, Brasnu D. Idiopathic sub-glottal stenosis in the adult. *Ann Otolaryngol Chir Cervicofac* 1999; 116 (5): 250- 6.
17. Park SS, Streitz JM Jr, Rebeiz EE, Shapshay SM. Idiopathic subglottic stenosis. *Arch Otolaryngol Head Neck Surg* 1995; 121 (8): 894- 7.
18. To M, Sano Y, Hata E, Ogawa C, Otomo M, Suzuki N, et al. A case of idiopathic subglottic stenosis successfully treated with endoscopic laser treatment. *Nihon Kokyuki Gakkai Zasshi* 2000; 38 (7): 545-50.
19. Garini G, Fecci L, Giacosa R, Vaglio A. Adult idiopathic subglottic stenosis: a diagnostic and therapeutic challenge. *Ann Ital Med Int* 2004; 19 (1): 54- 7.
20. Giudice M, Piazza C, Foccoli P, Toninelli C, Cavaliere S, Peretti G. Idiopathic subglottic stenosis: management by endoscopic and open-neck surgery in a series of 30 patients. *Eur Arch Otorhinolaryngol* 2003; 260 (5): 235- 8.
21. Lunn W, Garland R, Ashiku S, Thurer RL, Feller-Kopman D, Ernst A. Microdebrider bronchoscopy: a new tool for the interventional bronchoscopist. *Ann Thorac Surg* 2005; 80 (4): 1485- 8.