

Case Report

©2012 NRITLD, National Research Institute of Tuberculosis and Lung Disease, Iran

ISSN: 1735-0344 Tanaffos 2012; 11(3): 49-51

TANAFFOS 

Squamous Cell Carcinoma on the Remaining Sequel of Tuberculosis, Presented as Pancoast Tumor 8 Years Later

Mohsen Sokouti ¹, Monireh Halimi ²,
Samad EJ Golzari ^{3,4}

¹Department of Cardiothoracic Surgery, ²Department of Pathology, ³ Medical Philosophy and History Research Center, ⁴ Students' Research Committee, Tabriz University of Medical Sciences, Tabriz, Iran

Received: 27 February 2012

Accepted: 16 June 2012

Correspondence to: Samad EJ Golzari
Address: Medical Philosophy and History Research Center, Tabriz University of Medical Sciences, Tabriz, Iran
Email address: dr.golzari@hotmail.com

Herein a 46 year-old man is presented with intolerable severe pain of right shoulder radiating to right arm and fourth and fifth fingers. He had a history of right upper lobectomy due to complicated tuberculosis eight years ago. Based on the findings of clinical examination and computed tomography imaging, diagnosis of Pancoast tumor of the right chest apex was confirmed. However, Fine Needle Aspiration (FNA) under computed tomography (CT) guidance was not conclusive. By performing a limited thoracotomy, multiple biopsy specimens were obtained from the mass and destroyed ribs for histopathologic examination which consequently confirmed the diagnosis of squamous cell carcinoma. Eventually, the patient was referred to the radiotherapy ward for treatment of Pancoast tumor.

Key words: Tuberculosis, Pancoast tumor, Lobectomy, Squamous cell carcinoma

INTRODUCTION

Superior Pulmonary Sulcus or Pancoast tumor was first described by Pancoast in the US and Tobias in Argentina in 1932 (1). Being located at the dorsal aspect of the thoracic inlet and apex of the chest, Pancoast tumor is mostly derived from neoplasms in 95% of patients and characterized by shoulder pain due to involvement of brachial plexus nerves, Horner's syndrome and atrophy of hand muscles (1-3). Furthermore, first to third upper ribs are commonly destroyed by the tumor. Pulmonary infectious diseases rarely cause Pancoast-Tobias syndrome and only a few cases have been reported in the literature (2, 4). Delayed occurrence of squamous cell carcinoma on remaining sequel of pulmonary tuberculosis has not been reported in the literature.

CASE SUMMARIES

A 46-year-old man (employee) presented with a history of right upper lobectomy of the lung eight years ago due to complicated tuberculosis with hemoptysis. He complained of chronic cough, severe right upper arm and shoulder pain and sweating. His vital signs were as following: Pulse rate=80, respiratory rate=16, body temperature=37.6 °C and tuberculin test=1.5 cm. For the past eight years, he has been suffering from sputum production, weight loss and upper thoracic and right limb pain resulting in repeated admissions. Blood analysis upon admission to our referral hospital was as follows: WBC=14.4x10³, Hb =15.7 g/dL, Ca=13.5 mg/dL, P=4.6 mg/dL, Alkaline phosphatase 205 IU/L, ESR=86, and normal ABG findings. Three times sputum analysis and examinations were negative for tuberculosis. Computed Tomography (CT) scan of the chest revealed loculated pneumothorax in the right upper lobe with nodular infiltration in the left lower lobe, and

tracheal and mediastinal shift to the left hemithorax. Partial pleural thickening and fibrosis, irregular mass formation and calcification were also reported in the right upper lobe fossa (Figure 1). In flexible bronchoscopy, stricture of the right middle lobe and obstruction of the right upper lobe without evidence of tumor were observed.

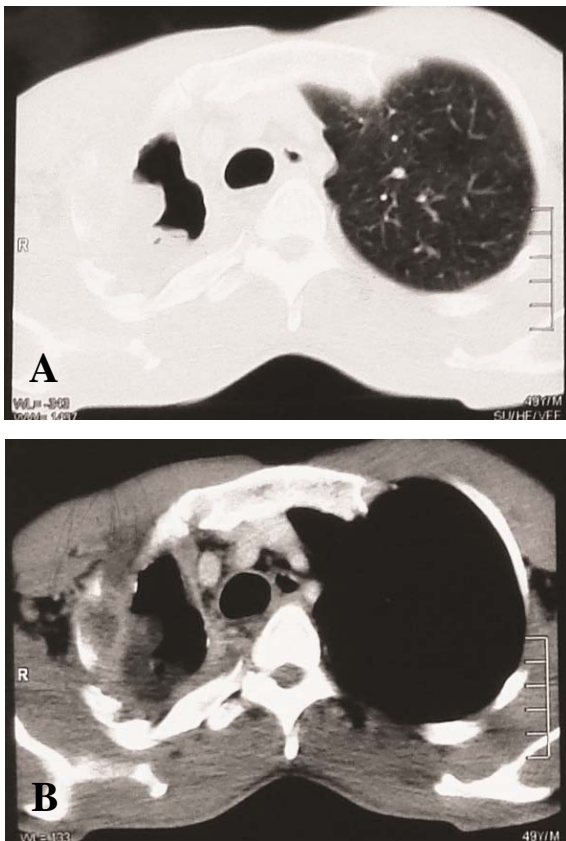


Figure 1 (A, B). Chest CT of the Patient in two different views.

Electromyography examination of the right arm muscles was in favor of superior sulcus tumor because of severe intolerable right arm and upper shoulder pain. After consultation with a pain clinic, the patient underwent cervicothoracic ganglion block which was performed through 6th cervical transverse process tuberosity with an injection of 10 mL solution of Depo-Medrol (40 mg) + Marcaine 0.05% (4 mg) + fentanyl (10 µg). The infrascapular blockage was performed in prone position. After the emergence of Horner's syndrome and sympathetic block, the patient was scheduled for Transcutaneous Electrical Nerve Stimulation (TENS) therapy and serial blockade. After pain relief, percutaneous

transthoracic biopsy was performed from the pleural thickenings. Pathologic examination was negative for the diagnosis of the tumor (Figure 2). The patient was previously hospitalized for 15 days in the Infectious Diseases Ward with diagnosis of TB recurrence; however, BK and cytology examinations of the sputum and BAL smears were negative.

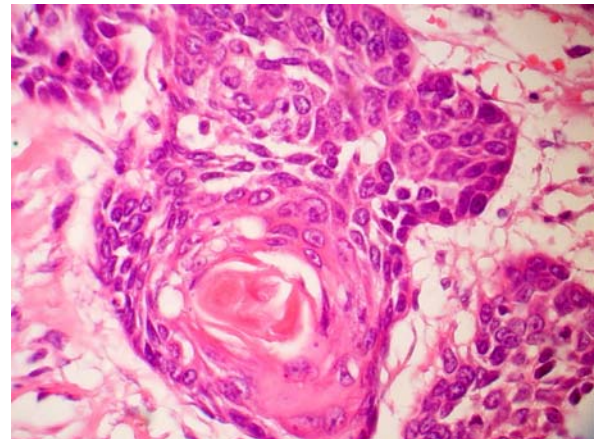


Figure 2. Histopathological view of the samples taken

In favor of malignancy, the patient was prepared for thoracotomy procedure. On exploration, severe adhesions caused by the previous operation, and tumor lesion invasion to upper brachial plexus and major subclavian vessels were observed. The tumor was inoperable. After sampling abundant biopsies from the tumor and closing bronchial openings, the chest was closed while one chest tube was located in the right upper hemithorax. Pathologic examination confirmed the diagnosis of squamous cell carcinoma. Consequently, the patient was scheduled for radio-therapeutic protocol.

DISCUSSION

Infectious diseases as a cause of Pancoast syndrome are extremely rare; pulmonary tuberculosis of upper lobes; however, could present in this way (3, 5). Horner's syndrome would occur as a result of the satellite ganglion involvement which might not be present in Pancoast tumor as in our patient. Radiation of the associated pain indicates the involvement of the lower and rarely middle brachial

plexuses (T4). On imaging, Pancoast tumor manifests as an apical mass (75%) or unilateral apical pleural thickening (50%). Magnetic Resonance Imaging (MRI) is ideal for determining soft tissue and brachial plexus and subclavian vessels involvement (6). Although concurrent Pancoast tumor and pulmonary tuberculosis have been sporadically reported in the literature (4,5), the present report focuses on the fact that Pancoast tumor should be kept in mind as a delayed occurrence on sequel of pulmonary tuberculosis after resection as well.

To our knowledge, this is the first reported case of squamous cell carcinoma on remaining sequel of pulmonary tuberculosis presented as Pancoast tumor eight years later. Our patient was neither immunosuppressed nor immunocompromised. He was rather healthy except for his moderate obstructive respiratory complication and severe right upper arm pain. Preoperative histological diagnosis is mandatory to confirm the diagnosis and treatment (radiotherapy in T3 or palliative radiotherapy and chemotherapy in T4).

As percutaneous transthoracic biopsy is inefficient in this regard, we preferred to perform limited thoracotomy to provide abundant samples and to manage the etiology of apical dead space, pleural thickening and non-homogenous apical mass formation.

In recent years, Video-Assisted Thoracoscopic Surgery (VATS) has been the procedure of choice for diagnosis and treatment of thoracic pathologies (7). In our patient, this procedure was not performed due to the complexity of the disease such as concomitant probable occurrence of bronco-pleural fistula, empyema, Pancoast tumor, recurrence of tuberculosis and managing the etiology of atelectasis of remaining segment of middle lobe of the lung. Recently, five-year survival has been reported to be less than 5% in stage IIIb and IV with palliative radiation.

REFERENCES

1. Attar S, Krasna MJ, Sonett JR, Hankins JR, Slawson RG, Suter CM, et al. Superior sulcus (Pancoast) tumor: experience with 105 patients. *Ann Thorac Surg* 1998; 66 (1): 193- 8.
2. Arenas Gordillo M, Ortega Ruiz F, Otero Candelera R, Caballero Oliver A, Blanco Orozco A, Calderón Osuna E. Pancoast syndrome caused by lung tuberculosis. *Arch Bronconeumol* 1998; 34 (5): 266- 8.
3. Ribas J, Lores L, Ruiz J, Ausina V, Morera J. Pancoast's syndrome due to chronic pneumonia by *Pasteurella multocida*. *Eur Respir J* 1997; 10 (12): 2904- 6.
4. Bernstein D. Concurrence of superior pulmonary sulcus tumor and pulmonary tuberculosis. *Dis Chest* 1946; 12 (5): 436-43.
5. Beshay M, Roth T, Stein RM, Schmid RA. Tuberculosis presenting as Pancoast tumor. *Ann Thorac Surg* 2003; 76 (5): 1733- 5.
6. Sharif HS, Morgan JL, al Shahed MS, al Thagafi MY. Role of CT and MR imaging in the management of tuberculous spondylitis. *Radiol Clin North Am* 1995; 33 (4): 787- 804.
7. Dusmet M, Halkic N, Corpataux JM. Video-assisted thoracic surgery diagnosis of thoracic spinal tuberculosis. *Chest* 1999; 116 (5): 1471- 2.