

Case Report

©2012 NRITLD, National Research Institute of Tuberculosis and Lung Disease, Iran

ISSN: 1735-0344 Tanaffos 2012; 11(3): 52-54

TANAFFOS 

One Stage Operation for Five Giant Hydatid Cysts of Both Lungs and Liver in a 20-Year-Old Female

Manochehr Aghajanzadeh , Gilda Aghajanzadeh , Hannan Ebrahimi, Sina Khajeh Jahromi, Alireza Amir Maafi, Sara Massahnia

Respiratory Diseases and TB Research Center, Razi Hospital, Guilan University of Medical Sciences (GUMS), Rasht-Iran

Received: 26 April 2012

Accepted: 2 June 2012

Correspondence to: Ebrahimi H

Address: Guilan University of Medical Sciences

(GUMS), Razi Hospital, Rasht-Iran

Email address: rrc@gums.ac.ir

Echinococcosis remains a significant health hazard in endemic areas, including the Middle East, Mediterranean countries and Central Asia. Pulmonary disease appears more commonly in younger individuals but bilateral pulmonary involvement is relatively rare. Concomitant pulmonary and liver hydatid disease may occur in 4% to 25% of patients with hydatidosis.

A previously healthy 20-year-old female from north of Iran without any previous history of lung or liver disease presented with complaints of right upper quadrant and right side chest pain and a low grade fever for the past one month. In imaging studies, one cyst in the left lung, two cysts in the right lung and two cysts in the liver were found. Since the cysts were symptomatic, it was decided to treat these cysts surgically. The patient underwent bilateral antero-lateral thoracotomies and phrenotomy under general anesthesia and all cysts were evacuated. The patient was discharged in good condition.

Key words: Liver, Echinococcosis, Lung

INTRODUCTION

Hydatid disease is a serious health problem in some countries like Iran where it is endemic (1). Although it may involve any organ, it most often affects the liver and the lungs (2). Concomitant pulmonary and liver hydatid disease may occur in 4% to 25% of patients with hydatidosis (3,4). Medical management with oral mebendazole and albendazole has been used, and it is the preferred treatment option in children (2). In some reports, a single-stage operation for pulmonary and liver hydatid cysts was found to be a safe procedure with low morbidity and mortality (5,6).

There is no universally accepted size to define a pulmonary hydatid cyst as "giant", but in an endemic country, the size can increase up to two thirds of the hemi thorax (4). Yet, a 6 cm hydatid cyst is rare (6). To date, cases reported in the literature have been unilateral solitary giant hydatid cysts (2,6). We discuss a case of unusually giant hydatid cysts as solitary cysts in each lung along with

liver hydatid cyst treated with bilateral antero-lateral thoracotomies and phrenotomy under general anesthesia. All the cysts were evacuated.

CASE SUMMARIES

A previously healthy 20-year-old female from north of Iran without any previous history of lung or liver disease presented with complaints of right upper quadrant and right side chest pain, cough and a low grade fever for the past one month. Her coughing and pain were persistent.

Upon physical examination, her vital signs were normal. However, her oxygen saturation rate reduced to 96% in room air. Chest and abdominal examinations were normal. Laboratory investigations showed eosinophilia (15%) and anti cestod antibody was positive. Chest X ray showed a well-defined, smoothly outlined, oval shaped soft tissue and opaque in density in each lung. These findings were indicative of bilateral hydatid cysts of the lungs. An ultrasonography of the abdomen revealed two

large well-defined cysts with homogenous walls in right lobe of the liver. It was septated and daughter cyst was identified within each cyst. The ultrasonography of other parts of the abdomen and pelvis was normal. A computed tomography scan of the chest and abdomen showed three large, bilateral and well circumscribed loculated cysts in the lungs (Figure 1) and two cysts in the liver (Figure 2).

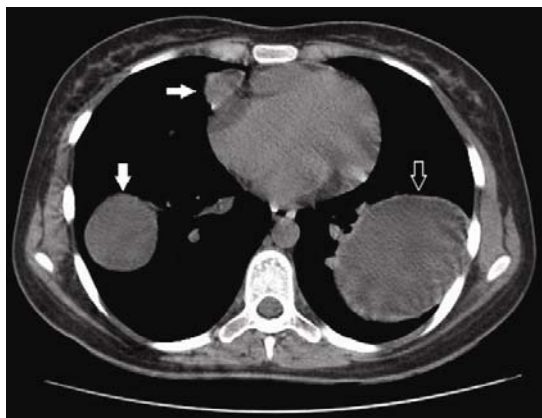


Figure 1. Chest computed tomography scan demonstrated one large cystic mass in the left lung (arrow) and two in the right lung (white arrow).

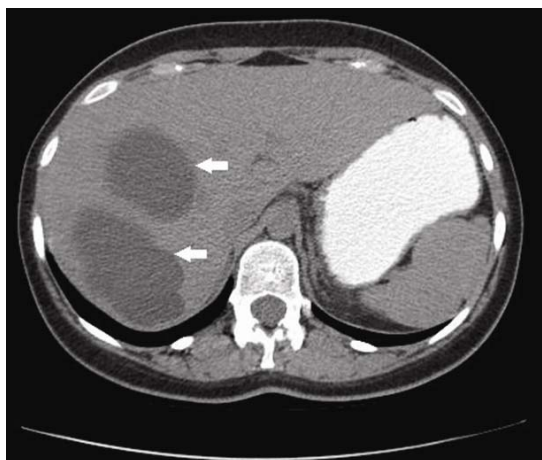

Figure 2. CT scan revealed two large cysts in the right lobe of the liver (white arrow).

Due to the symptoms caused by these cysts, the cysts were decided to be treated surgically. The patient underwent separated bilateral antero-lateral thoracotomies and phrenotomy under general anesthesia with double lumen and tracheal tube in the supine position. First, we operated the left side pulmonary cyst. Intraoperatively, cysts were found to be hydatid cysts, they were first aspirated and then evacuated. Laminated membrane and bronchial opening were closed with capitonage. The

pleural cavities were thoroughly irrigated with hypertonic saline. A chest tube was placed and the chest was closed primarily. Two cysts in the right side were evacuated similar to those in the left side. The two liver cysts were evacuated with phrenotomy. Two Foley catheters were placed in the cavity of liver cysts after evacuation. To reduce recurrence in the postoperative period, Albendazole was given for 3 months. Her postoperative recovery was smooth with no evidence of sepsis, pneumonia or bronchiectasis that. These complications sometimes occur after conservative parenchyma saving lung procedures. At one-year follow-up, the patient showed complete resolution of all symptoms and well expanded lungs with no residual cysts visible on the chest X-ray (Figure 3).

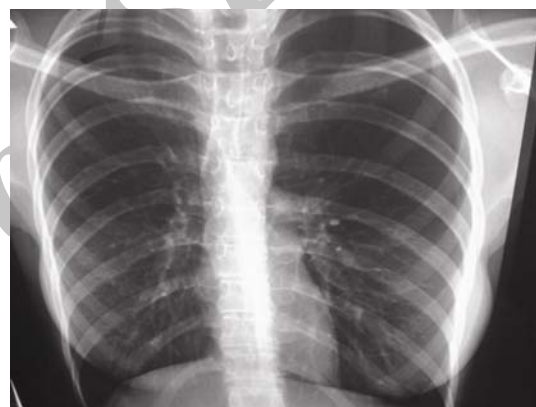

Figure 3. Chest X-ray after one-year showed no visible residual cysts.

DISCUSSION

Concomitant pulmonary and liver hydatid cysts occur in 4% to 25% of patients with echinococcosis (3,4). Pulmonary hydatid cyst appears more common in younger individuals but bilateral pulmonary involvement is relatively rare (7,8). The prevalence of multiple pulmonary cysts and bilateral cysts is 30% and 4%, respectively (7). Out of 216 cases of pulmonary hydatid cysts that were surgically treated, 18 had bilateral cysts (8.33%) (9,10).

We reported a 20 year-old female with three hydatid cysts in her lungs. In case of a hydatid cyst in the left lung, two in the right lung and two in the liver, they can either get perforated into the bronchiole with expectoration of the laminated layer and spontaneous obliteration of the residual cavity; or they can enlarge in size to form giant hydatid cysts(11). The latter is mostly seen among the

younger age group because the lower tissue resistance and higher elasticity in young patients allow for the cyst to grow to a giant size (11). The five cysts in our patient were uncomplicated because the laminated membrane had not been penetrated (5,11).

Bilateral lung cysts should be resected in one or two stages (3,4). In a patient with an uncomplicated lung cyst in one and a ruptured cyst in another lung, the intact cyst should be removed first in order to prevent its rupture. The contralateral lesions are then resected 2 to 4 weeks after the first operation (3,4).

Indications for a two-stage operation in Petrov and colleagues report are a large number of pulmonary cysts, lobectomy in the presence of pleural adhesions and poor cardiopulmonary reserve (12).

Concurrent pulmonary and hepatic cysts may be treated in one or two-stage surgical procedures and the lung is treated first in most cases (3,4).

Some authors recommend right thoracotomy and phrenotomy in one stage in patients with hydatid cyst of the right lung and hepatic cyst of the dome of the liver (3, 13, 14).

For bilateral pulmonary hydatid cysts and hepatic hydatid cyst, Other authors have used sternophrenotomy and sternolaparotomy as a one-stage procedure (3,15). This approach is not suitable in patients with infected cysts or those with hepatobiliary or bronchobiliary fistulas (3,4). We operated on our patient with five cysts in one stage through bilateral anterolateral thoracotomies and phrenotomy.

CONCLUSION

In conclusion, in an endemic area bilaterally hydatid cysts of the lungs and concomitant pulmonary and liver hydatid cysts can occur. Surgery should be performed in young patients through a one stage procedure as it was done in our patient.

REFERENCES

- Saidi F. Surgery of hydatid disease. London: WB Saunders; 1976.
- Eroğlu A, Kürkcüoğlu C, Karaoğlanoğlu N, Tekinbaş C, Kaynar H, Onbaş O. Primary hydatid cysts of the mediastinum. *Eur J Cardiothorac Surg* 2002; 22 (4): 599- 601.
- Aghajanzadeh M, Safarpour F, Amani H, Alavi A. One-stage procedure for lung and liver hydatid cysts. *Asian Cardiovasc Thorac Ann* 2008; 16 (5): 392- 5.
- Peleg H, Best LA, Gaitini D. Simultaneous operation for hydatid cysts of right lung and liver. *J Thorac Cardiovasc Surg* 1985; 90 (5): 783- 7.
- Erdogan A, Ayten A, Kabukcu H, Demircan A. One-stage transthoracic operation for the treatment of right lung and liver hydatid cysts. *World J Surg* 2005; 29 (12): 1680- 6.
- Rami-Porta R, Ais-Conde JG, Bravo-Bravo JL, Alix-Trueba A, Serrano-Muñoz F. Treatment of synchronous pulmonary and hepatic hydatid cysts. *J Thorac Cardiovasc Surg* 1986; 92 (2): 314- 5.
- Hussain A, Maraghi S. Hydatid disease in children:A different pattern than adults. *Pak J Med Sci* 2006; 22: 329- 32.
- Göçmen A, Toppare MF, Kiper N. Treatment of hydatid disease in childhood with mebendazole. *Eur Respir J* 1993; 6 (2): 253- 7.
- Biswas B, Ghosh D, Bhattacharjee R, Patra A, Basuthakur S, Basu R. One stage bilateral thoracotomy for hydatid cysts of both lungs. *Ind J Thorac Cardiovasc Surg* 2004; 20: 126- 8.
- Symbas N, Aletras H, eds. Hydatid disease of the lung. 7 ed. New York: Lippincott Williams & Wilkin; 2009. Shields T, Locicero J, Ponn R, Rusch V, eds. General thoracic surgery.
- Halezeroglu S, Celik M, Uysal A, Senol C, Keles M, Arman B. Giant hydatid cysts of the lung. *J Thorac Cardiovasc Surg* 1997; 113 (4): 712- 7.
- Petrov DB, Terzinacheva PP, Djambazov VI, Plochev MP, Goranov EP, Minchev TR, et al. Surgical treatment of bilateral hydatid disease of the lung. *Eur J Cardiothorac Surg* 2001; 19 (6): 918- 23.
- Kurul IC, Topcu S, Altinok T, Yazici U, Tastepi I, Kaya S, et al. One-stage operation for hydatid disease of lung and liver: principles of treatment. *J Thorac Cardiovasc Surg* 2002; 124 (6): 1212- 5.
- Lone GN, Bhat MA, Ali N, Ahangar AG, Dar AM, Sana I. Minimally invasive transthoracotomy-transphrenotomy for concurrent hepatic and pulmonary hydatid disease. *Br J Surg* 2005; 92 (6): 729- 33.
- Dhaliwal RS, Kalkat MS. One-stage surgical procedure for bilateral lung and liver hydatid cysts. *Ann Thorac Surg* 1997; 64 (2): 338- 41.