

## The Extrapulmonary Manifestations of Systemic Sclerosis on Chest High Resolution Computed Tomography

Donya Farrokh<sup>1</sup>, Bitā Abbasi<sup>1</sup>, Yalda Fallah-Rastegar<sup>1</sup>, Zahra Mirfeizi<sup>2</sup>

<sup>1</sup> Department of Radiology, Mashhad University of Medical Sciences, Mashhad, Iran, <sup>2</sup> Department of Rheumatology, Mashhad University of Medical Sciences, Mashhad, Iran

Received: 25 February 2015

Accepted: 9 July 2015

Correspondence to: Abbasi B

Address: Department of Radiology, Imam Reza Hospital, Razi Sq. Mashhad, Iran.

Email address: abbasib@mums.ac.ir

**Background:** Systemic sclerosis (SS) is a collagen vascular disease of unknown etiology that is characterized by connective tissue abnormalities. This study aimed to evaluate the extra-pulmonary manifestations of SS on chest high resolution computed tomography (HRCT).

**Materials and Methods:** The medical records of patients with SS who presented to our hospital in a 10-year period were retrospectively reviewed. Forty patients with SS were included in this study. The extra pulmonary manifestations of SS were evaluated in these patients, including esophageal involvement, pulmonary arterial dilatation, pleural abnormalities, pericardial disease and mediastinal lymph node involvement.

**Results:** The most common extra-pulmonary manifestation was esophageal dilatation, which was detected in 70% of the cases followed by pleural involvement. Pulmonary arterial dilatation was seen in 20%, pleural involvement in 40%, pericardial involvement in 40% and mediastinal lymphadenopathy in 30%. The most common pleural abnormality was diffuse pleural thickening and the most common pericardial abnormality was pericardial effusion. There was an association between the severity of lung fibrosis with the incidence of esophageal dilatation and pulmonary arterial hypertension (PAH) in our series. Patients with SS and interstitial lung disease (ILD) who had PAH, had more severe lung fibrosis than those without PAH.

**Conclusion:** Patients with SS may have a variety of extra-pulmonary manifestations, which can be detected using HRCT. Our study evidenced that HRCT was useful for detecting extra-pulmonary findings of SS such as esophageal dysmotility and dilatation, enlargement of main pulmonary artery and PAH, pleuropericardial involvement and mediastinal lymphadenopathy

**Key words:** Chest; Lung fibrosis; Systemic sclerosis; High resolution computed tomography

### INTRODUCTION

Systemic sclerosis is a chronic multisystem autoimmune disease that produces inflammation and fibrosis of the skin and several internal organs including the lungs, esophagus, musculoskeletal system, heart, and kidneys (1, 2). The exact etiology and pathogenesis are

unknown. Depending on the extent of cutaneous involvement, the disease is classified into two types including diffuse cutaneous and localized cutaneous forms (1). The disease is associated with high morbidity and mortality, and ILD is the main cause of morbidity and

mortality in patients with SS (2). Internal organ involvement is also an important determinant of mortality in these patients. The disease usually involves the young and middle aged women (3). The lungs are involved in nearly 90% of SS patients at autopsy and 40% of SS patients have abnormal pulmonary function test (4). Only 25% of SS patients have respiratory symptoms or radiographic manifestation of pulmonary involvement. Also, ILD, mainly in the form of fibrosis and PAH are the two most common complications and the leading causes of morbidity and mortality in patients with SS (2). In the recent years, evidence has been accumulating that immunosuppressive treatment in an early stage of the disease can improve survival, which mandates early, accurate diagnosis and complete evaluation of multiple organ involvement in these patients (1, 2). Patients with SS are routinely investigated with chest HRCT for detecting lung involvement and evaluating the severity of ILD (1, 2, 5). HRCT is more sensitive than chest radiograph to diagnose multiple intra-thoracic but extra pulmonary involvements in these patients. The extra pulmonary involvement can increase the complications and increase the mortality and morbidity of the disease. The aim of this study was to discuss the extra pulmonary manifestations of SS patients on chest HRCT and to describe the significance of these imaging findings.

## **MATERIALS AND METHODS**

This was a descriptive retrospective study, which was performed between 2004 and 2014. Forty consecutive patients with a definite diagnosis of SS were included in this study. The criteria for diagnosis of SS were based on the American College of Rheumatology criteria. All patients were evaluated at Imam Reza Hospital of Mashhad University of Medical Sciences, as either inpatients or outpatients. There were six men and 34 women with a mean age of 40 years (range 32-68 years). The mean duration of the disease was four years (range one-15 years). There was no evidence of other connective tissue disorders in the patients. None of the patients had a

history of other diseases such as lung, or digestive abnormalities, diabetes, tuberculosis or other systemic diseases. The patients had no clinical history of esophageal or gastric surgery.

HRCT of the thorax was performed in all patients in order to detect imaging abnormalities related to pulmonary involvement and extra pulmonary manifestations of SS. The HRCT was performed using 1 to 2 mm collimation slices with 10 mm intervals or volumetrically on a multidetector CT scanner. The HRCT protocol was standardized across all slices. The HRCT scan protocol included a beam potential of 140 KV and a beam current of 100 mA. The images were photographed at lung (level -600 to -700 HU, width 1000-1500 HU) and mediastinal windows (level 20-50 HU, width 300-500 HU).

The HRCT findings of extra-pulmonary manifestations of SS were investigated in the patients.

All registered data were transferred to SPSS 15, and analyzed using Mann-Whitney and Kruskal-Wallis tests. The results were regarded as significant when P-value was less than 0.05.

We used the following imaging criteria in our study:

- Esophageal dilatation:
  - Coronal diameter of esophagus more than 9 mm in the infra-aortic portion and/or presence of air-fluid level in the esophagus.
- Pleural disease: pleural thickening or pleural effusion.
- Pericardial disease: Pericardial thickening or pericardial effusion.
- Pulmonary arterial enlargement: diameter of the main pulmonary artery at the level of bifurcation greater than 29mm.
  - All patients underwent echocardiography to be evaluated for PAH.
- Mediastinal lymphadenopathy: Presence of lymph nodes greater than 9mm in short axis in contrast-enhanced or non-contrast chest HRCT studies.
- Pulmonary fibrosis:
  - Presence of intralobular septal thickening
  - Presence of honeycombing

- Presence of obvious fibrotic bands in the mid or lower zones of the lungs.

## RESULTS

Forty patients with definite diagnosis of SS who had medical records and HRCT scans were included in this study. All patients had evidence of pulmonary involvement. There were six men and 34 women in our series. Retrospective analysis of these patients revealed that 30 patients had evidence of extra pulmonary abnormalities on chest HRCT. The mean age of our patients was 40 years (age range of 32-68). The main extra-pulmonary manifestations in these patients included: esophageal dilatation, pleural disease, pericardial disease, pulmonary arterial dilatation and mediastinal lymphadenopathy.

Esophageal dilatation was diagnosed if HRCT demonstrated a pocket of air in the esophagus under the aortic arch on four or more consecutive serial CT images and if the lumen diameter of such an air filled esophagus in the coronal plane was more than 10 mm. The esophageal dilatation was presented in 21 patients (70%). The coronal diameter of the esophagus at the infra-aortic level ranged from 1-2.5 cm. There was a significantly higher incidence of esophageal dilatation in patients with severe lung fibrosis ( $P < 0.05$ ). HRCT demonstrated more severe lung fibrosis in the lower and mid lung zones in patients with esophageal dilation. There was also a positive correlation between the presence of esophageal dilatation and the incidence of pulmonary artery enlargement ( $P < 0.05$ ).

Pleural involvement was detected on HRCT in 12 patients (40%). Pleural thickening was more common and was seen in eight patients, and pleural effusion was detected only in four cases.

Pericardial abnormalities were seen in 12 patients (40%). Pericardial effusion was seen in seven patients, and diffuse pericardial thickening in five cases.

Chest HRCT demonstrated pulmonary artery dilatation in eight patients (20%). Main pulmonary artery

enlargement was detected if the transverse diameter of the main pulmonary artery exceeded 3 cm. There was a positive correlation between the presence of esophageal dilatation and the incidence of pulmonary artery dilatation, and pulmonary fibrosis in our series ( $P < 0.05$ ).

Among the eight patients that had imaging evidence of pulmonary artery dilatation, seven (87.5%) showed PAH in echocardiography. There were also three (7.5%) patients with echocardiographic PAH that did not have imaging manifestations of pulmonary dilatation. As our study's aim was to evaluate the HRCT findings in SS patients, these three patients were not considered positive for pulmonary artery involvement based on imaging.

Mediastinal lymphadenopathy was present in 12 patients (30%). The presence and location of mediastinal lymphadenopathy were evaluated according to the American Thoracic Society protocol. Mediastinal lymphadenopathy was diagnosed if the short axis of the lymph node exceeded 10mm. Although contrast injection increases the accuracy of mediastinal lymph node detection, in this study all mediastinal lymph nodes (excluding hilar lymph nodes) were evaluated without intravenous injection of contrast medium.

## DISCUSSION

Systemic sclerosis is a systematic connective tissue disease characterized by marked connective tissue abnormalities associated with vascular involvement. It is a complex and heterogeneous chronic disease with variable clinical presentation, internal organ involvement, and various outcomes (1, 3). The peak incidence is between 45 and 64 years of age, and the disease is more common in black American women (3). There is multiple organ involvement associated with skin and inflammatory changes (1, 3). The disease usually involves multiple organs and the lungs are commonly involved in patients with SS, preceded by skin, the peripheral vasculature, and the esophagus in the frequency of involvement (4). Lungs are involved in almost all patients at autopsy series. The

most common visceral manifestations are pulmonary and esophageal involvements. Lung disease and PAH are the leading causes of death in the patients (6, 7). The overall mortality is reported to be 50% and it has the highest mortality rate among collagen vascular diseases (1, 3).

In the recent years, evidence has shown that immunosuppressive drugs in an early stage of the disease could improve survival in these patients. HRCT is a sensitive method for evaluation of the early stages of lung involvement. The sensitivity of diagnostic methods is different and depends on the stage of the disease. In a few patients with SS, respiratory symptoms are the presenting manifestation and chest HRCT is a reliable and useful imaging modality for detecting asymptomatic interstitial lung involvement in the patients (1). Chest radiography may be insensitive to the presence of pulmonary disease, and shows lung involvement in only 60-70% of patients (5). HRCT is more sensitive than chest radiograph in detecting early interstitial involvement. Common HRCT findings of pulmonary involvement include pulmonary fibrosis associated with septal thickening, ground glass opacities, subpleural linear opacities with basilar distribution, subpleural cysts or honey combing, bronchiectasis and micro nodules (1, 3, 8). In advanced stages of the disease, HRCT shows volume loss in the lungs and diffuse pulmonary fibrosis. There are four main roles for imaging in patients with SS: 1) Detecting lung involvement, 2) Identifying patients who may respond to treatment, 3) Assessing treatment efficacy, and 4) Detecting extra pulmonary abnormalities especially pulmonary arterial dilatation, esophageal dysmotility and pleuropericardial involvement.

Various abnormalities can be detected on chest HRCT scans in SS patients such as dilated esophagus, dilated pulmonary artery secondary to PAH, pleural and pericardial abnormalities and mediastinal lymphadenopathy (1, 3). Table 1 shows various pulmonary and extra pulmonary findings on chest HRCT scans of patients with SS.

**Table 1.** Various pulmonary and extra pulmonary abnormalities which may be seen on the chest HRCT scans of patients with systemic sclerosis

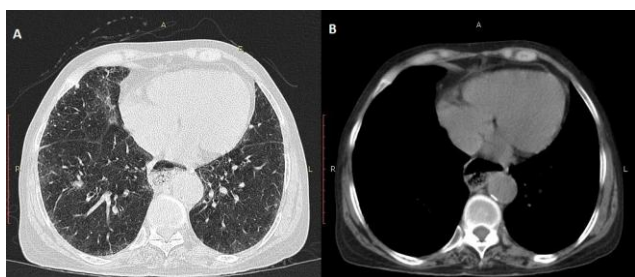
Esophageal involvement	Dysmotility Dilatation
Pleural involvement	Pleural thickening Pseudoplaque Subpleural micronodules Pleural effusion
Pericardial involvement	Pericardial effusion Pericardial thickening (diffuse or localized)
Pulmonary artery	Dilatation
Mediastinal involvement	Mediastinal lymphadenopathy

### **Esophageal involvement**

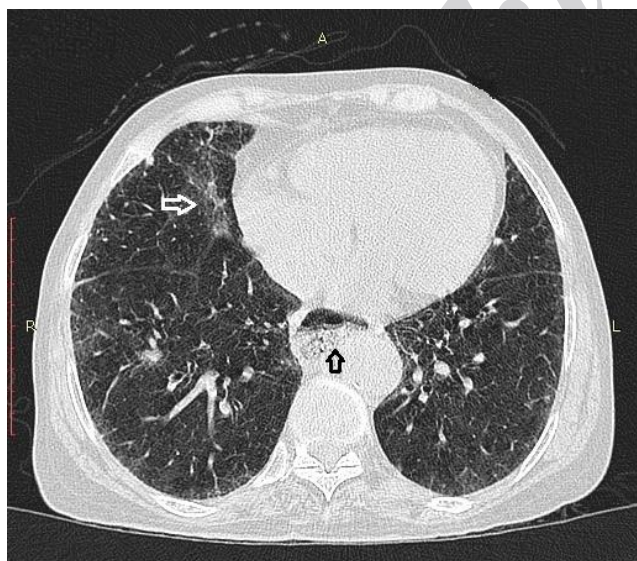
Esophagus is the first organ in the gastrointestinal tract that is affected in SS, followed by the anorectal region. Esophageal dysmotility is a common manifestation in patients with SS and is reported in 75% of patients (1, 9). Esophageal dysmotility may cause esophageal dilatation (Figure 1). Esophageal dysmotility is usually detected with barium swallow or esophageal transit scintigraphy (10, 11). In most patients with SS, chest HRCT and barium study show the same efficacy in detection of esophageal dysmotility and esophageal dilatation. A dilated air-fluid esophagus may be identified on upright chest radiograph and is a manifestation of esophageal dysmotility as a result of smooth muscle atrophy and fibrosis. An air-fluid level in the esophagus suggests distal esophageal stenosis and is secondary to chronic reflux esophagitis (12). Esophageal dilatation is defined by coronal diameter of > 9mm of the esophagus lumen at the infra-aortic portion of the esophagus (1, 9, 12). The prevalence of esophageal dilatation in patients with SSC varies from 50% to 80% in different series. The sensitivity of HRCT in detecting esophageal dilatation is reported to be 65% (12). Esophageal dysmotility and secondary functional or anatomic obstruction may cause aspiration with the development of lower lobe pneumonia (Figure 2). Recurrent aspiration pneumonia may result in pulmonary fibrosis (13, 14). Patients with SS that have pulmonary fibrosis and gastro esophageal reflux usually show more extensive esophageal involvement in comparison to those without evidence of pulmonary fibrosis (1, 3). Gastro



esophageal reflux is considered a contributing factor in the pathogenesis of ILD, and repeated microaspiration of gastric contents may cause pulmonary fibrosis (12, 13). Patients with SS and esophageal dilatation on HRCT usually show more severe ILD, more severe pulmonary vascular disease and a higher PAH (1, 3). CT is useful in detecting asymptomatic esophageal involvement in these patients. Early diagnosis of esophageal involvement is mandatory for accurate treatment to preclude the complications of esophageal dysmotility and associated chronic gastro esophageal reflux. The esophageal dilatation was presented in 70% of patients in our study, which was the same as the literature.



**Figure 1.** Chest HRCT of the lung (A) and mediastinal (B) window setting in a 42-year old woman with SS showing dilatation of the esophagus



**Figure 2.** HRCT shows aspiration pneumonitis in the right lung (white arrow) associated with esophageal dysmotility (black arrow).

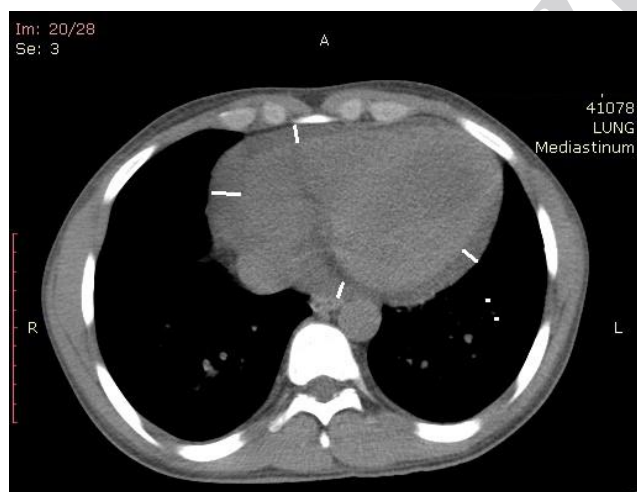
### Pleural disease

Pleural involvement may be in the form of diffuse pleural thickening, pleural effusions, pseudo-plaques, and subpleural micronodules (1). The presence of pleuritis, pleural effusion and pleural thickening is a general finding in patients with SS. Pleural diseases are associated with pleuritic chest pain in 40-50% of patients and pleuritic chest pain has been reported in 40% of SS patients (1, 3). Pleural effusion and pleural thickening are not common findings on chest radiograph. Pleural thickening is reported in 20% of cases on HRCT scans, but significant pleural effusion is an uncommon finding. Pleural effusion in SS patients is non-specific and requires a complete clinical evaluation to exclude other causes of effusion such as complications of treatment and infection (15, 16). Usually the characteristics of fluid on pleural fluid analysis are useful for correct diagnosis. Pleural effusion is frequently reported in patients with SS who have evidence of PAH (16). Pleural disease was detected in 40% of patients in our series. Pleural abnormalities were more common in our patients in comparison to the literature.

### Pericardial disease

The radiographic features of pericarditis with associated effusion were first described by Steinberg and Rothbard (16). Pericardial abnormalities may be seen in the form of pericardial effusion, diffuse pericardial thickening, and thickening of anterior pericardial recess (1, 3, 17). Thompson et al. reported pericardial abnormality in 59% of patients with SS (18). The exact etiology of pericardial abnormalities is not well known. Drainage of some cardiac veins into the right atrium and secondary increase of right atrial pressure may also play a role in increased pulmonary arterial pressure. There may be a passive transudative phenomena secondary to increased pulmonary artery pressure. Drainage of the cardiac veins into the right atrium and secondary increased right atrial pressure may also play a role in the accumulation of fluid in pericardium (18). Pulmonary hypertension is seen more commonly in patients with pericardial abnormality (1).

The incidence of pericardial involvement in SS is about 50% on autopsy series. Asymptomatic pericarditis occurs in 16% of patients with diffuse disease and 30% of patients with limited type of SS (1, 3, 19). Pericardial effusion is more common in diffuse form of SS and may be seen without evidence of clinical features of cardiac dysfunction. Pericardial effusion occurs in 70% of patients with SS and it is usually asymptomatic (1, 3). In patients with SS and ILD, pericardial involvement is a common finding on HRCT, and is usually associated with evidence of PAH on echocardiography. Pericardial thickening or effusion are also common findings in patients with severe PAH. HRCT is more sensitive than chest radiograph in detecting early pericardial effusion (Figure 3). Total pericardial score > 8 mm is considered abnormal. Total pericardial score is the sum of the thickness of pericardium at the four points including; anterior, posterior, right lateral, and left lateral, measuring at a level between the aortic root and diaphragm on axial HRCT scans (1, 3). Abu-Shakra and associates reported a patient with pericardial effusion, massive pleural effusion, and renal failure (19). Pericardial abnormalities were presented in 30% of patients in our study.



**Figure 3.** HRCT scan demonstrating pericardial effusion (white lines).

#### **Pulmonary arterial enlargement**

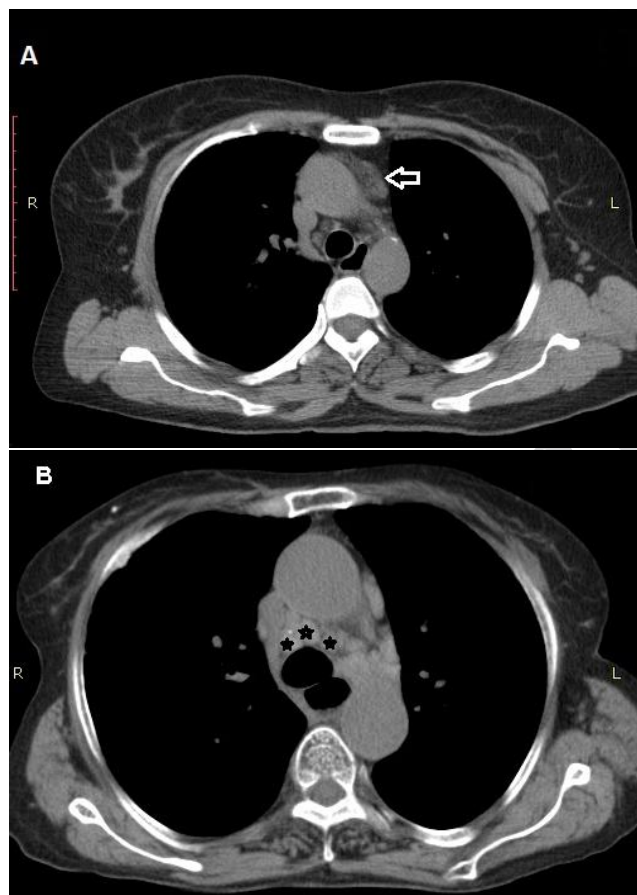
Interstitial lung disease and PAH are the most common cardiopulmonary manifestations of SS (1, 3, 20). PAH is

typically associated with severe lung disease in these patients and may be seen as an isolated finding. Pulmonary arterial hypertension is one of the common extra pulmonary manifestations of SS with an incidence of 10 to 80% (1, 20); 33% of patients with SS show evidence of PAH at angiography (1, 3). On chest radiograph, it is characterized by an enlarged main pulmonary artery, attenuation of the smaller vessels and cardiomegaly (3). Computed tomography is an accurate method for measuring the size of main pulmonary artery (21). In most series, pulmonary artery diameter has been shown to correlate with pulmonary arterial pressure and increased diameter of the main pulmonary artery is a prediction of PAH (1). Main pulmonary artery is measured at its widest portion at the level of bifurcation to the right and left pulmonary artery on the axial CT scan and dilated pulmonary artery (>29mm) suggests the presence of PAH (1, 3). The cause of PAH in SS is usually diffuse lung fibrosis but it may be primary and without fibrosis or any evidence of extensive lung disease (22). Detection of severity and extent of ILD may be useful in screening for PAH in patients with SS. Some authors reported that pulmonary arterial dilatation may occur in the absence of PAH in patients with ILD (22). Today, echocardiography is the screening test for detection of PAH, and is recommended in all patients with SS. When echocardiogram is indeterminate, right heart catheterization is necessary to confirm the presence of PAH (1, 3). PAH has a dramatic impact on prognosis and is the most common cause of disease related death in these patients. Our study demonstrated pulmonary artery enlargement in 20% of cases. The incidence of pulmonary artery dilatation was less than the literature in our patients.

#### **Mediastinal lymphadenopathy**

Esophageal dilatation and mediastinal lymphadenopathy are frequent associated findings in SS patients (1, 3). Bhalla et al. reported asymptomatic esophageal dilatation in 80% of patients with SS, and mediastinal lymphadenopathy in 60% (9). Wechsler et al. found mediastinal lymphadenopathy in 50% of patients

with diffuse form of cutaneous SS and in 40% of patients with limited cutaneous SS (23). Garber et al. described that there is an association between the presence of mediastinal lymphadenopathy and ILD, especially when there is lung involvement with ground glass opacities (24). Mediastinal lymphadenopathy in SS patients may be a consequence of pulmonary inflammation. HRCT can help narrow the differential diagnosis in patients in whom CT scan reveals lymph node involvement (Figure 4). Our study demonstrated mediastinal lymphadenopathy in 30% of patients. The prevalence of mediastinal lymphadenopathy increased with the presence of extensive lung fibrosis on HRCT in our series.



**Figure 4.** Axial HRCT scan in mediastinal window setting in a 55 year old woman with SS showing mediastinal lymphadenopathy in anterior (arrow in A) and middle (asterisks in B) mediastinum.

This study had three limitations. First it was a retrospective study that included a small number of patients. Second, we performed HRCT with intravenous

contrast medium when there was suspicion for mediastinal lymphadenopathy, and there is possibility that we cannot detect all cases with mediastinal lymphadenopathy. Finally we did not have any histological confirmation and so we were unable to correlate the HRCT findings of extra pulmonary abnormalities with histopathology.

## CONCLUSION

The main goal of performing HRCT in SS patients is to diagnose ILD in early stage and detect the severity of lung involvement, and evaluate the reversibility and response to treatment. It is important to detect extra pulmonary manifestations of the disease because these findings may be helpful in diagnosing visceral involvement especially in asymptomatic patients. Our study demonstrated that chest HRCT was useful for detecting extra pulmonary manifestations in SS patients.

## REFERENCES

1. Pandey AK, Wilcox P, O' Brien J, Ellis J, Brown J, Leipsic J. Significance of various pulmonary and extrapulmonary abnormalities on HRCT of the chest in scleroderma lung. *Indian J Radiol Imaging* 2013;23(4):304-7.
2. Ioannidis JP, Vlachoyiannopoulos PG, Haidich AB, Medsger TA Jr, Lucas M, Michet CJ, et al. Mortality in systemic sclerosis: an international meta-analysis of individual patient data. *Am J Med* 2005;118(1):2-10.
3. Al-Jahdali H, Rajiah P, Allen C, Koteyar SS, Khan AN. Pictorial review of intrathoracic manifestations of progressive systemic sclerosis. *Ann Thorac Med* 2014;9(4):193-202.
4. Varga J. Systemic sclerosis: an update. *Bull NYU Hosp Jt Dis* 2008;66(3):198-202.
5. Schurawitzki H, Stiglbauer R, Graninger W, Herold C, Pölzleitner D, Burghuber OC, et al. Interstitial lung disease in progressive systemic sclerosis: high-resolution CT versus radiography. *Radiology* 1990;176(3):755-9.
6. Wells AU, Steen V, Valentini G. Pulmonary complications: one of the most challenging complications of systemic sclerosis. *Rheumatology (Oxford)* 2009;48 Suppl 3:iii40-4.
7. Arroliga AC, Podell DN, Matthay RA. Pulmonary manifestations of scleroderma. *J Thorac Imaging* 1992;7(2):30-45.

8. Goldin JG, Lynch DA, Stollo DC, Suh RD, Schraufnagel DE, Clements PJ, et al. High-resolution CT scan findings in patients with symptomatic scleroderma-related interstitial lung disease. *Chest* 2008;134(2):358-67.
9. Bhalla M, Silver RM, Shepard JA, McLoud TC. Chest CT in patients with scleroderma: prevalence of asymptomatic esophageal dilatation and mediastinal lymphadenopathy. *AJR Am J Roentgenol* 1993;161(2):269-72.
10. Vonk MC, van Die CE, Snoeren MM, Bhansing KJ, van Riel PL, Fransen J, et al. Oesophageal dilatation on high-resolution computed tomography scan of the lungs as a sign of scleroderma. *Ann Rheum Dis* 2008;67(9):1317-21.
11. Pitrez EH, Bredemeier M, Xavier RM, Capobianco KG, Restelli VG, Vieira MV, et al. Oesophageal dysmotility in systemic sclerosis: comparison of HRCT and scintigraphy. *Br J Radiol* 2006;79(945):719-24.
12. Pandey AK, Wilcox P, Mayo JR, Moss R, Ellis J, Brown J, et al. Oesophageal dilatation on high-resolution CT chest in systemic sclerosis: what does it signify? *J Med Imaging Radiat Oncol* 2011;55(6):551-5.
13. Savarino E, Ghio M, Marabotto E, Zentilin P, Sammito G, Cittadini G, et al. Possible connection between gastroesophageal reflux and interstitial pulmonary fibrosis in patients with systemic sclerosis. *Recenti Prog Med* 2009;100(11):512-6.
14. Lee JS, Collard HR, Raghu G, Sweet MP, Hays SR, Campos GM, et al. Does chronic microaspiration cause idiopathic pulmonary fibrosis? *Am J Med* 2010;123(4):304-11.
15. Highland KB, Heffner JE. Pleural effusion in interstitial lung disease. *Curr Opin Pulm Med* 2004;10(5):390-6.
16. Steinberg I, Rothbard S. Roentgen Features of Scleroderma Pericarditis with Effusion. *Radiology* 1964;83:292-6.
17. Baque-Juston MC, Wells AU, Hansell DM. Pericardial thickening or effusion in patients with pulmonary artery hypertension: a CT study. *AJR Am J Roentgenol* 1999;172(2):361-4.
18. Thompson AE, Pope JE. A study of the frequency of pericardial and pleural effusions in scleroderma. *Br J Rheumatol* 1998;37(12):1320-3.
19. Abu-Shakra M, Koh ET, Treger T, Lee P. Pericardial effusion and vasculitis in a patient with systemic sclerosis. *J Rheumatol* 1995;22(7):1386-8.
20. Pandey AK, Wilcox P, Mayo JR, Sin D, Moss R, Ellis J, et al. Predictors of pulmonary hypertension on high-resolution computed tomography of the chest in systemic sclerosis: a retrospective analysis. *Can Assoc Radiol J* 2010;61(5):291-6.
21. Tan RT, Kuzo R, Goodman LR, Siegel R, Haasler GB, Presberg KW. Utility of CT scan evaluation for predicting pulmonary hypertension in patients with parenchymal lung disease. Medical College of Wisconsin Lung Transplant Group. *Chest* 1998;113(5):1250-6.
22. Devaraj A, Wells AU, Meister MG, Corte TJ, Hansell DM. The effect of diffuse pulmonary fibrosis on the reliability of CT signs of pulmonary hypertension. *Radiology* 2008;249(3):1042-9.
23. Wechsler RJ, Steiner RM, Spirn PW, Rubin S, Salazar AM, Shah R, et al. The relationship of thoracic lymphadenopathy to pulmonary interstitial disease in diffuse and limited systemic sclerosis: CT findings. *AJR Am J Roentgenol* 1996;167(1):101-4.
24. Garber SJ, Wells AU, duBois RM, Hansell DM. Enlarged mediastinal lymph nodes in the fibrosing alveolitis of systemic sclerosis. *Br J Radiol* 1992;65(779):983-6.