

## Case Report

©2015 NRITLD, National Research Institute of Tuberculosis and Lung Disease, Iran

ISSN: 1735-0344 *Tanaffos* 2015; 14(3): 217-221



# Different and Unpredictable Clinical Outcome of Ruptured Pulmonary Hydatid Cysts

Kambiz Sheikhy<sup>1</sup>, Mehregan

Abbasidezfouli<sup>1</sup>, Abolghasem Daneshvar

Kakhaki<sup>1</sup>, Seyed Reza Saghebi<sup>2</sup>, Alireza

Malekzadegan<sup>3</sup>

<sup>1</sup> Lung Transplantation Research Center, National Research Institute of Tuberculosis and Lung Disease (NRITLD), Shahid Beheshti University of Medical Sciences, Tehran, Iran, <sup>2</sup> Tracheal Diseases Research Center, Shahid Beheshti University of Medical Sciences, Tehran, Iran, <sup>3</sup> Zabol University of Medical Sciences, Zabol, Iran.

Received: 16 March 2015

Accepted: 30 May 2015

Correspondence to: Abbasidezfouli M

Address: Lung Transplantation Research Center, NRITLD, Shahid Beheshti University of Medical Sciences, Tehran, Iran

Email address: mehregan.abbasi@gmail.com

Most authors believe that the best treatment for pulmonary hydatid disease is surgical evacuation. Although albendazole has been used prophylactically before surgery, there are many reports about increased incidence of the rupture of cyst after albendazole therapy, which can cause some complications.

In this case report we present a patient with bilateral pulmonary hydatid cyst that was ruptured after using albendazole and different strategies were used for management of each cyst.

**Key words:** Pulmonary hydatid cyst; Albendazole; Surgery

## INTRODUCTION

Hydatid cyst is endemic in Iran and some other Middle Eastern countries. Lung is the second most commonly affected organ after liver by this parasitic disease. Course of most pulmonary hydatid cysts is unpredictable. Furthermore, clinical presentation of ruptured cysts can be misleading. Albendazole has been used as a prophylactic drug before surgery or as definitive medical therapy in patients with this disease. On the other hand, clinical observations have shown an increased incidence of spontaneous rupture of lung cysts following administration of albendazole (1-3). In this case report we present a patient with bilateral pulmonary hydatid cysts that were ruptured following administration of

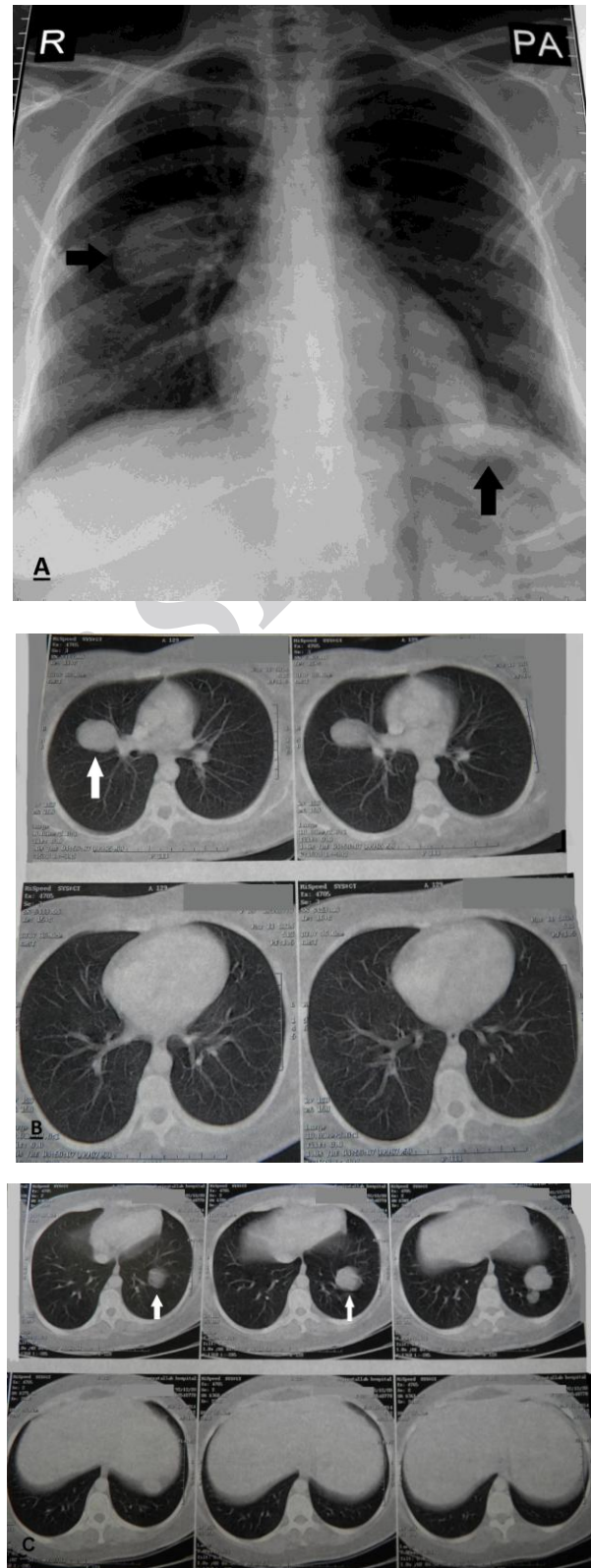
albendazole. Clinical outcome and therapeutic approaches were different for each cyst.

## CASE SUMMARIES

A 37 year-old woman incidentally noticed a 5 cm soft mass in her left inguinal area that disappeared after manipulation and compression by herself. On the morning after, she noticed severe edema and erythema in this area that spread to her genitalia. After visiting her physician sonography was done, which suggested the presence of an abscess due to necrotic lymph nodes. Patient was admitted to hospital and intravenous antibiotic was started with no obvious effect on reducing the edema. A round cystic

lesion was noticed in each lung on chest x ray that was confirmed by computed tomography (CT) scan and magnetic resonance imaging (MRI) (Figure 1 A,B,C). Serologic studies for hydatid cyst were positive and diagnosis of pulmonary hydatid cyst was confirmed. CT scan of the abdomen revealed a round lesion in the liver that was compatible with hemangioma and a small cystic lesion in her left inguinal area.

As a prophylactic measure, albendazole was initiated for a 30-day period (400 mg twice daily) before surgical treatment of pulmonary lesions, but after 20 days the patient experienced an attack of dyspnea and wheezing. Chest radiograph showed ruptured cysts in both lungs (Figure 2 A,B). After 7 days of medical treatment dyspnea and wheezing subsided and since chest CT scan showed complete evacuation of the cyst, we decided to continue medical treatment with albendazole. The patient was symptom-free for about 10 months but cough and sputum production returned. On CT scan, the left cyst was completely empty but the right cyst contained fluid. Due to its central location there was high probability of a communication between the right sided cyst cavity and larger bronchus compared to the left cyst (Figure 3 A,B). Oral antibiotic was ineffective in reducing respiratory symptoms. Fiber optic bronchoscopy showed pus with mucoid material in the right middle lobe bronchus. A thoracotomy was planned for patient with the diagnosis of infected cyst cavity. A right anterolateral thoracotomy was done and the cavity of the cyst that contained turbid fluid and degenerated laminated membrane was opened. After evacuation of the cyst and washing the cavity with normal saline solution, capitonage was done. After the operation, there was complete resolution of signs and symptoms. On the chest x ray taken one month after the operation there was no abnormality in the right lung and there was only one empty cavity in the left lung (Figure 4).



**Figure 1.** Bilateral intact cystic lesions on chest X ray (A) and CT scan (B & C) (arrows)

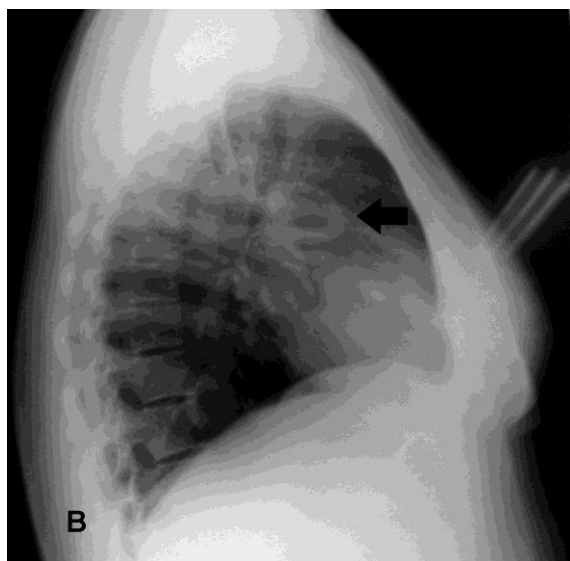
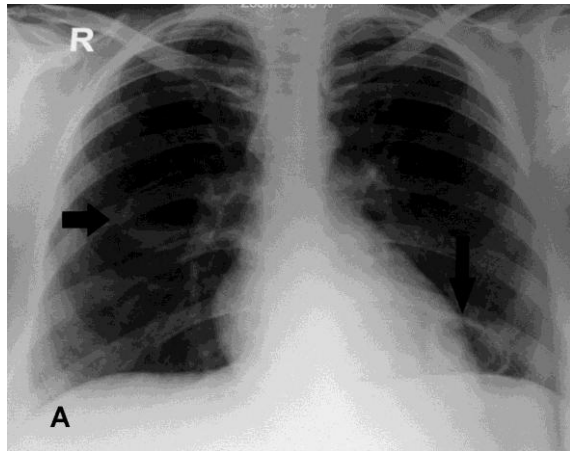


Figure 2 PA & lateral chest X ray 20 days after administration of albendazole showing bilateral ruptured cysts with seemingly empty cavity (arrows) (A & B)

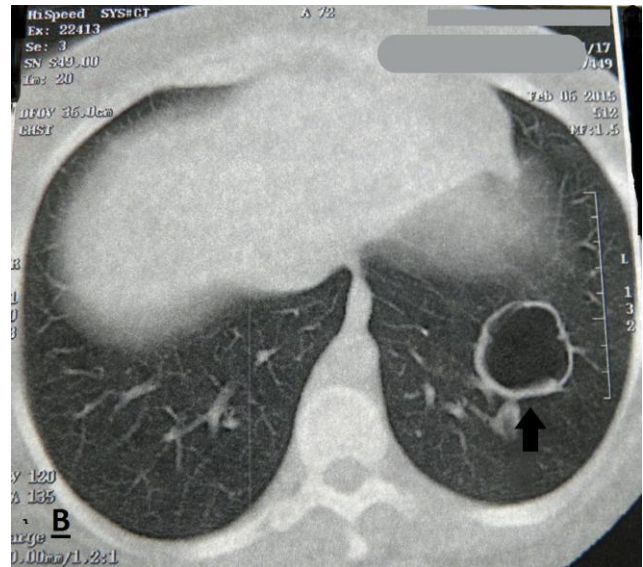
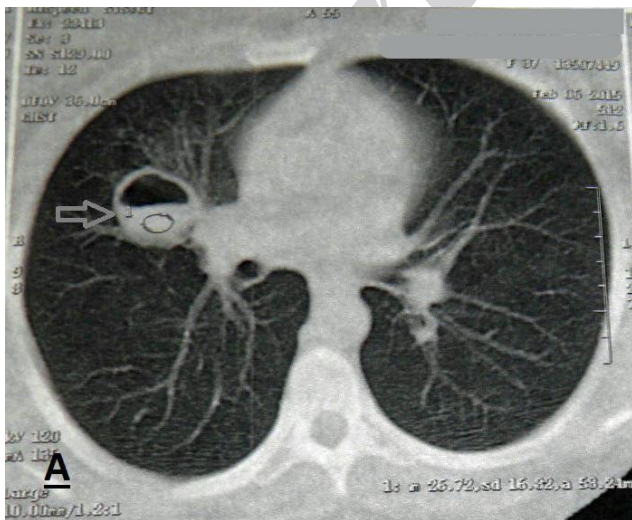


Figure 3. CT scans 10 months after treatment with albendazole. Right cyst is central with intra cystic fluid accumulation (A) and left cyst is peripheral and completely empty (B).

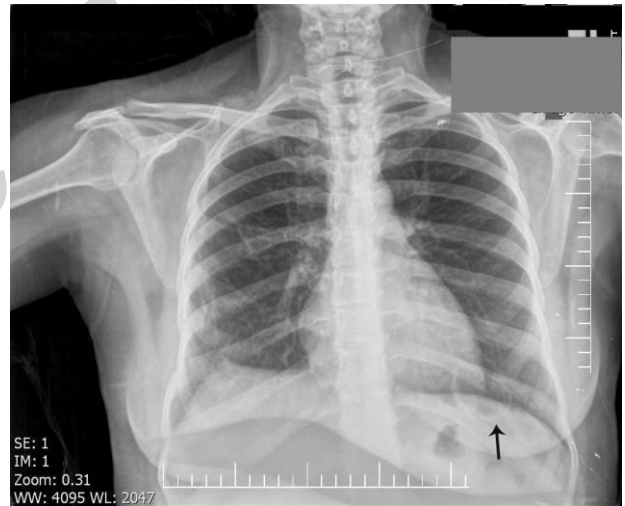


Figure 4. Chest X ray six months after surgery showing unchanged stable left cyst (arrow) and right lung with small postoperative changes and without cystic lesion

## DISCUSSION

Hydatid cyst is an endemic disease in Iran and some other Middle Eastern countries. Liver is the most common location for this cyst and the lungs are the second most common organ involved by this disease. Generally, the course of pulmonary hydatid cysts is unpredictable; some cysts will grow with time but some remain stable in size or



even rupture. Classic treatment of pulmonary hydatid cyst consists of surgical evacuation and closure of bronchial opening with or without capitonage (1). In the recent years, antihelmentic drugs such as albendazole have been used as a prophylactic measure before surgery for reducing the recurrence rate or as a definite medical therapy in patients that are not good candidates for surgical treatment (2). Rupture of pulmonary hydatid cyst can occur spontaneously and can be the first presentation in an asymptomatic patient. There are a series of medical observations that show an increased incidence of spontaneous rupture following administration of albendazole. In most of these cases severe anaphylactic shock was not observed. The chance of this event is higher in larger pulmonary cysts. In some of these reports rupture of pulmonary hydatid cyst was followed by complete evacuation of intra cavitory membranes and even disappearance of cyst on radiographs.

Koul and Kanjwal in their study reported six patients with ruptured pulmonary hydatid cyst following albendazole usage. In all of these patients albendazole was used as a prophylactic drug before surgical treatment. In two patients surgical evacuation of cyst was required and in the remaining four patients treatment with albendazole was continued with acceptable results (3).

Talwar et al. in their report presented a patient in whom, albendazole induced rupture of pulmonary hydatid cyst that did not need surgical treatment and several cycles of albendazole treatment resulted in full recovery of the patient (4).

Galankis et al. also reported a similar case (5). These authors believe that there is an increased incidence of spontaneous rupture of pulmonary hydatid cyst caused by using albendazole but continuing treatment with albendazole can result in complete recovery and eliminate the need for surgery. The main reason for rupture of cyst following albendazole administration is not completely understood but may be due to the impaired nutrition of cyst wall and high intra cystic pressure (6).

Usluer et al. in their experimental study showed that tensile strength of cuticular membrane of pulmonary hydatid cysts decreased following administration of albendazole (7).

There are two important findings in our case: the first is bilateral rupture of pulmonary cysts in spite of their small sizes following administration of albendazole, the second and more important one is that in spite of bilateral rupture of cysts, clinical course of these two cysts was different. Following rupture of cysts, we selected non-surgical management for the patient although the left cyst remained asymptomatic but the right one was complicated by infection that needed surgery. Depending on the anatomical location of pulmonary hydatid cyst and signs and symptoms of patient, surgical treatment, continuation of medical treatment or even termination of treatment may be considered. In central cysts, there is a higher probability of connection of cysts to larger airways and higher chance of complication compared to peripheral cysts. Some authors believe that reducing the duration of albendazole administration to 4-7 days before surgery will eliminate the chance of albendazole induced rupture of cyst; although in some reports using this drug for more than 30 days reduced scolex numbers in cysts (8). Finally, although albendazole can cause elimination of pulmonary hydatid cyst and even complete recovery in some rare cases, there is also an unpredictable risk of rupture and subsequent complications, therefore surgical treatment is the best therapy for these patients (9).

## CONCLUSION

Albendazole has been used as prophylactic treatment before surgery in patients with pulmonary hydatid cyst to reduce recurrence rate. This drug can cause spontaneous rupture of cysts with some unpredictable complications. Therefore, we believe early surgical treatment even without albendazole prophylaxis is an acceptable strategy for treating these patients.

Patients with peripherally located and completely evacuated pulmonary hydatid cysts that are asymptomatic may not need surgery.

## REFERENCES

1. Sheikhy K, Shadmehr MB. Hemoptysis as a complication of capitonage for management of pulmonary hydatid cyst. *Tanaffos* 2014;13(3):46-8.
2. Anadol D, Ozçelik U, Kiper N, Göçmen A. Treatment of hydatid disease. *Paediatr Drugs* 2001;3(2):123-35.
3. Koul PA, Kanjwal MK. Albendazole Induced rupture of pulmonary hydatid cysts. *The Internet Journal of Pulmonary Medicine* 2006; 6(1).
4. Talwar D, Dhariwal A, Gupta BB, Sen Gupta D. Albendazole in pulmonary hydatid disease. *Indian J Chest Dis Allied Sci* 1990;32(4):237-41.
5. Galanakis E, Besis S, Pappa C, Nicolopoulos P, Lapatsanis P. Treatment of complicated pulmonary echinococcosis with albendazole in childhood. *Scand J Infect Dis* 1997;29(6):638-40.
6. Taylor DH, Morris DL. The current management of hydatid disease. *Br J Clin Pract* 1988;42(10):401-6.
7. Usluer O, Kaya SO, Samancilar O, Ceylan KC, Gursoy S. The effect of preoperative albendazole treatment on the cuticular membranes of pulmonary hydatid cysts: should it be administered preoperatively? *Kardiochir Torakochirurgia Pol* 2014;11(1):26-9.
8. Taylor DH, Morris DL, Richards KS. Perioperative prophylactic chemotherapy of Echinococcus granulosus: determination of minimum effective length of albendazole therapy in in vitro protoscolex culture. *HPB Surgery* 1990;2(3):159-64.
9. Kurkcuoglu IC, Eroglu A, Karaoglanoglu N, Polat P. Complications of albendazole treatment in hydatid disease of lung. *Eur J Cardiothorac Surg* 2002;22(4):649-50.

Archive of SID