

# Comparative study of amyloidogenic potential of AgNO<sub>3</sub> and Freund's Adjuvant (AF) with that of Vitamin Free Casein, on Spatio-Temporal Pattern of Experimental Amyloidosis in Mice

Jamshidi, K.<sup>1\*</sup>, Moshfeqi, S.<sup>1</sup>, Mortazavi, P.<sup>2</sup>, Daneshvar, A.<sup>3</sup>, Abedi, M.<sup>2</sup>

<sup>1</sup> Department of Pathobiology, Faculty of Veterinary Sciences, Islamic Azad University, Garmsar Branch, Garmsar, Iran.

<sup>2</sup> Department of Pathobiology, Faculty of Specialized Veterinary Sciences, Islamic Azad University, Science and Research Branch, Tehran, Iran.

<sup>3</sup> Graduated of Faculty of Veterinary Sciences, Islamic Azad University, Garmsar Branch, Garmsar, Iran.

\*Corresponding Author: [kjamshidi48@yahoo.com](mailto:kjamshidi48@yahoo.com)

## Abstract

Reactive amyloidosis is a condition that complicates a long list of chronic inflammation, chronic infectious, malignant, and hereditary disorders. In the present study the potential effects of two amyloidogenic substances: ie. AgNO<sub>3</sub> and Freund's Adjuvant (AF) with that of vitamin free casein, on spatio-temporal pattern of experimental amyloidosis in mice were compared. For this purpose a total of 40 male Swiss mice, obtained from Pasteur Institute Tehran, after being weighted were randomly divided into 4 groups including 2 treatments, 1 control (vitamin free casein) and 1 positive control (normal saline). At the end of 3rd, 5th and 7th weeks of experiment 3 mice were randomly selected and euthanized. Spleen sample of each animal obtained and preserved in 10% neutral buffer formalin. Sample were then processed through different stages of dehydration, clearing and impregnation and finally embedded in paraffin blocks. Sections of 5µm thickness then cut and stained by alkaline Congo red techniques. Spleen weights and the data obtained from microscopic quantitative analysis did show no significant differences between groups A and B, A and C, and B and C. But significant differences were observed between groups A and D, B and D, and C and D respectively. It is concluded that two compounds ie; AgNO<sub>3</sub> and Freund's Adjuvant have the same potential, as does vitamin free casein have, in spatio-temporal pattern of experimental amyloidosis in mice. *Islamic.Azad.Univ., Garmsar Branch, 5,1:67-71,2009.*

**Keywords:** amyloid, AgNO<sub>3</sub>, Freund's Adjuvant, vitamin free, mice.

## مطالعه مقایسه‌ای پتانسیل آمیلوئیدوز نیک در ماده نیترا نقره و فروندز آجونت با کازئین بدون ویتامین بر الگوی فضایی- زمانی آمیلوئیدوزیس تجربی در موش

نام نویسندگان: کیوان جمشیدی<sup>۱</sup>، سوسنگند مشفق<sup>۱</sup>، پژمان مرتضوی، احمد رضا دانشور، محمد عابدی

۱- گروه پاتوبیولوژی، دانشکده دامپزشکی، دانشگاه آزاد اسلامی واحد گرمسار، گرمسار - ایران.

۲- گروه پاتوبیولوژی، دانشکده علوم تخصصی دامپزشکی، دانشگاه آزاد اسلامی واحد علوم تحقیقات، تهران - ایران.

۳- دانش آموخته دانشکده دامپزشکی، دانشگاه آزاد اسلامی واحد گرمسار، گرمسار - ایران.

## چکیده

آمیلوئیدوز راکتیو وضعیتی است که بدنبال طیف وسیعی از بیماری‌های آماسی مزمن، عفونت‌های مزمن، نئوپلازم‌های بدخیم و اختلالات وراثتی بوجود می‌آید. در مطالعه حاضر تأثیر دو ماده آمیلوئیدوز نیک یعنی AgNO<sub>3</sub> و Freund's Adjuvant (AF) با اثر آمیلوئیدوز نیک کازئین بدون ویتامین در ایجاد الگوی فضایی زمانی آمیلوئیدوز تجربی مورد مطالعه و مقایسه قرار گرفت. به همین منظور تعداد ۴۰ سر موش نر نژاد Swiss که از موسسه پاستور تهیه شده بود، پس از وزن کشی به طور تصادفی در چهار گروه شامل ۲ گروه تیمار، ۱ گروه کنترل (کازئین بدون ویتامین) و یک گروه کنترل مثبت (سالین نرمال) تقسیم شدند. در پایان هفته‌های سوم، پنجم و هفتم، ۳ موش به صورت راندوم انتخاب و به روش انسانی معدوم شدند. نمونه طحال هر حیوان برداشته و در فرمالین بافر ۱۰ درصد شد. نمونه‌ها پس از عبور از خلال مراحل مختلف دئیدراسیون، شفاف‌سازی و غوطه‌ورسازی، در بلوک‌های پارافینی قالبگیری شدند. مقاطع به ضخامت ۵ میکرون تهیه و به روش کنگورد رنگ آمیزی شدند. وزن طحال‌ها و اطلاعات بدست‌آمده از آنالیز نتایج میکروسکوپی، تغییر قابل توجهی بین گروه‌های A و B، C و B، C و D، D و B، D و C مشاهده نشد. ولی تفاوت‌های قابل توجهی بین گروه‌های A و D، B و D، C و D مشاهده شد. چنین نتیجه‌گیری می‌شود که دو ماده AgNO<sub>3</sub> و (FA) از پتانسیل مشابهی مانند کازئین بدون ویتامین در ایجاد الگوهای فضایی زمانی آمیلوئیدوز تجربی در موش برخوردار می‌باشند. مجله دانشکده دامپزشکی دانشگاه آزاد اسلامی واحد گرمسار، ۱۳۸۸، دوره ۵، شماره ۱، ۶۷-۷۱.

واژه‌های کلیدی: آمیلوئید، کازئین بدون ویتامین، نیترا نقره، فروندز آجودنت و موش.



## Introduction

Amyloidosis encompasses a diverse group of diseases and is characterized by the extracellular accumulation of fibrillar protein deposits (1). Amyloid is a pathologic proteinaceous substance that produces a collection of diverse clinical syndromes characterized by extracellular deposition of amorphous, congophilic protein within tissues. Amyloid proteins are distinguished by their twisted  $\beta$ -pleated sheet-fibrillar ultrastructure and made up of nonbranching fibrils of indefinite length and a width of approximately 7.5 - 10 nm. Amyloidosis is divided into systemic and localized forms based on the localization of the amyloid. The systemic form is composed of three types: AL amyloid associated with primary amyloidosis or immunoglobulin dyscrasias, AA amyloid associated with chronic inflammatory processes, and AF amyloid associated with hereditary amyloidosis. The most common types of localized amyloidosis are AE amyloid in the endocrine organs either associated or not associated with neoplastic conditions and AS amyloid associated with senile cardiomyopathy and cerebral plaques (2).

Amyloidosis is one of the human diseases that can be studied in animal models. Kuzcynski, the pioneer in the field of experimental amyloidosis, used casein to induce amyloidosis in mice in 1923. Subsequently this method has been widely used by investigators interested in amyloid research, and the Kuzcynski method is the most popular and easily reproducible model for induction of reactive (secondary) amyloidosis. The availability of such animal model has greatly advanced our understanding of the reactive systemic amyloidosis (5).

Secondary amyloidosis is a serious complication of chronic inflammatory disease, is caused by deposition in the tissues of amyloid A fibrils. It can be induced experimentally in mice following the introduction of various antigenic or inflammatory stimuli. Induction of amyloidosis in mice generally consists of chronic injections of inflammatory stimuli (such as daily s.c. injections of casein, azocasein, or AgNO<sub>3</sub>) which trigger production of serum acute-phase proteins such as serum amyloid A

(SAA). Serum concentration of SAA increases 100-1000 fold during acute and chronic inflammation (3). The principal diagnostic criterion of amyloidosis, established by Divry and Florkin in 1927, is the detection with a polarizing optical microscope of so-called "apple green birefringence" from Congo red stained tissue sections (4). As there are various compounds used experimentally in induction of amyloidosis, therefore in this study we compared the potential effect of two compounds i.e. AgNO<sub>3</sub> and Freund's Adjuvant with that of vitamin free casein on spatio-temporal pattern of amyloidosis in mice.

## Materials and Methods

**Experimental animals:** Forty Swiss male mice (31 ± 1 g BW), 5-7 week old purchased from Pasteur Institute - Tehran, were housed in polycarbonate boxes (10 per box) 1 week for acclimation. Drinking water and a commercial feed were available *ad libitum*. The animal room was maintained at approximately 22°C and 50% humidity with a 12-h light - dark cycle. On day 0 of experiment, animals after being weighted were randomly assigned to 4 groups including 2 treatment groups [ silver nitrate (B), and Freund's Adjuvant (C) ], 1 control group [vitamin free casein (A)] and positive control group [ normal saline (D)].

**Source of chemical compounds:** All chemicals including vitamin free casein, silver nitrate and Freund's Adjuvant purchased from Sigma chemical.

**Induction of amyloidosis:** For induction of amyloidosis in mice the following protocol was met:

Group A: subcutaneous injection of 0.5 ml of 12% vitamin free casein per day × 5 days per week.

Group B: subcutaneous injection of 0.5 ml of 2% AgNO<sub>3</sub> per day × once per week.

Group C: subcutaneous injection of 0.5 ml Freund's Adjuvant per day × once per week.

Group D: subcutaneous injection of 0.5 ml normal saline per day × 5 days per week.

**Tissue Sampling and Processing:** At the end of 3rd, 5th, and 7th week of experiment three mice randomly selected from each group, euthanized and after being necropsied, spleen of each animal collected and preserved in 10% neutral buffer



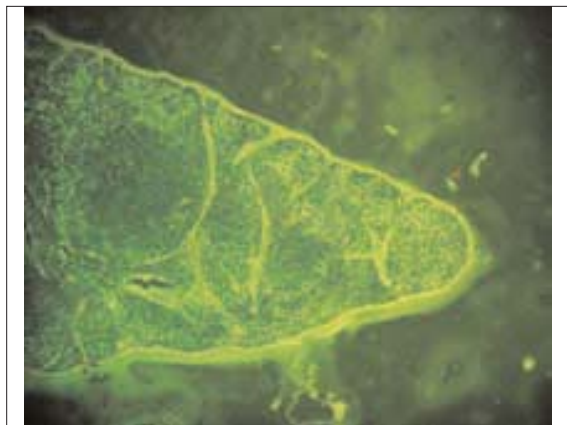

Fig.1: Group A - Spleen of mouse received casein on 7th week of treatment . Amyloid density scale is 3. Extracellular deposition of amyloid protein characterized by apple green birefringence. Congo red stain  $\times 10$ .

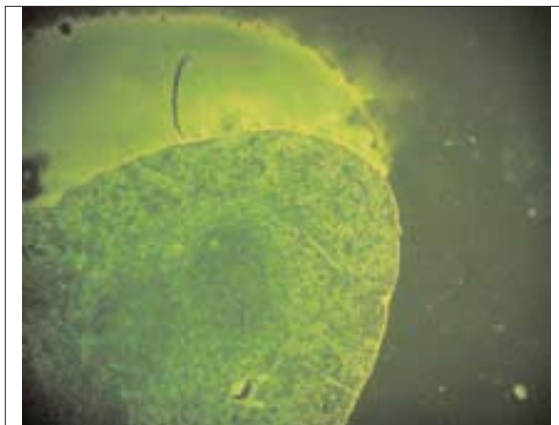


Fig. 2: Group B - Spleen of mouse received Freund's Adjuvant, on 7th week of treatment . Amyloid density scale is 3. Extracellular deposition of amyloid protein characterized by apple green birefringence. Congo red stain  $\times 10$ .




Fig.3: Group C - Spleen of mouse received AgNO<sub>3</sub>, on 7th week of treatment . Amyloid density scale is 3. Extracellular deposition of amyloid protein characterized by apple green birefringence. Congo red stain  $\times 10$ .

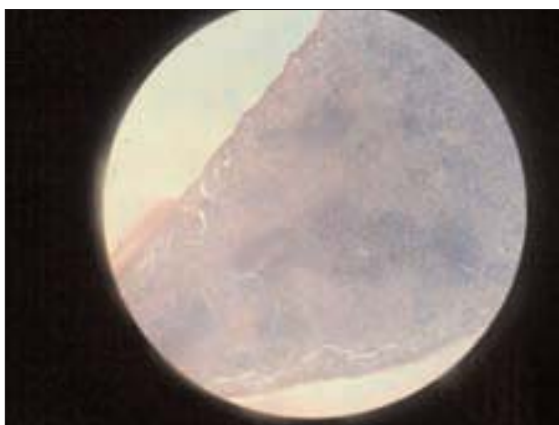
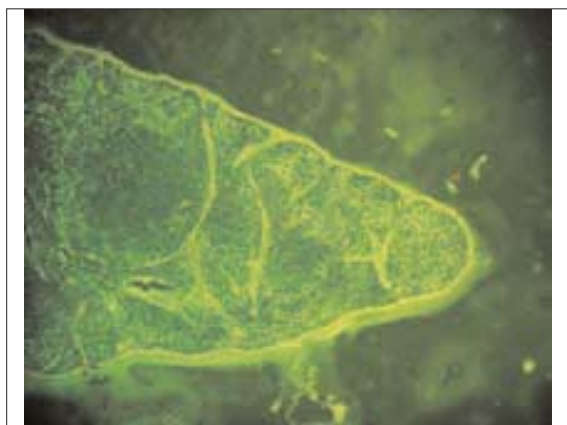
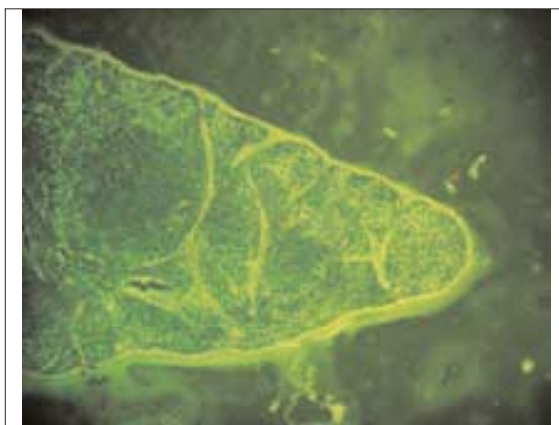
Fig.4: Group D - Spleen of mouse received Normal Saline, on 7th week of treatment . Amyloid density scale is 0. Congo red stain  $\times 10$ .



Graph 1:.



Graph 2:.

formalin for 72 hrs. Samples were then passed through different stages of dehydration, clearing and

impregnation and finally embedded in paraffin blocks. Tissue blocks were cut into 5 um sections and



Table 1- Indicating the mean spleen weights of each group on collecting days.

weeks groups	3 <sup>rd</sup>	5 <sup>th</sup>	7 <sup>th</sup>
1	1.65	1.80	2.44
2	1.36	2.03	1.96
3	1.23	1.64	2.14
4	0.86	0.69	0.98

stained with alkaline Congo red stain (Putchler et al. 1962). As indices of developing amyloidosis a green birefringence under the polarized microscope was considered to be a positive criterion for the presence of amyloid.

**Grading Score of Amyloid Deposits:** For optical evaluation of amyloidogenic potentials; amyloidoic areas were observed in randomly 10 selected high power fields (40x). A light microscope equipped with polarized light optics was used to determine the birefringence intensity of the amyloid deposition in Congo red stained sections. This system was assigned to represent changes in the quantitative appearance and intensity of amyloid deposits in various microscopic fields. Amyloidosis scale was assigned from 0 - 3. In brief the scale was as follow:

Grade 0: No birefringence, Grade 1: minimal, Grade 2: moderate, Grade 3: heavy amyloid deposits (6).

### Results

Organ weights and the data obtained from microscopic quantitative analysis of tissues were analysed by one - way analysis of variance (ANOVA) and use of SPSS software.

Table 1 shows the amount of average weights of spleens collected from different groups at the end of 3rd, 5th, and 7th weeks of experiment.

**Spleen Weights:** There was no significant difference between mean spleen weight of groups A and B, (  $P > 0.05$ ). The same result was observed between group A and C, and B and C as well. But high significant difference was observed between mean spleen weights of groups A and D, B and D, and C and D (  $p < 0.05$ ). The same results were observed at the end of 3rd, 5th and 7th weeks of experiment

Table -2: Indicating the amount of amyloid density in spleen samples on collecting days.

weeks groups	3 <sup>rd</sup>	5 <sup>th</sup>	7 <sup>th</sup>
1	1	2	3
2	1	1.5	2.5
3	1	1.5	2
4	0	0	0

respectively ( Table-1,Graph-1).

**Amyloid density Scale:** Relating to amyloid density scale the following results were observed at the end of 3rd, 5th, and 7th weeks of experiment. There was no significant difference between amyloid density scale of groups A and B, groups A and C, and groups B and C respectively (  $P > 0.05$ ). But high significant difference was observed between amyloid density scale of groups A and D, B and D, and C and D respectively (Figs- 1,2,3 & 4, Table-2, Graph -2).

### Discussion

Amyloidosis is defined by the presence in tissues of amyloid, a fibrillar proteinaceous material, which consists of a main protein and common elements. In animal models AA amyloid is classically induced by repetitive subcutaneous injections of casein or azocasein leading to amyloid deposition within 2-3 weeks. In this study, using casein, AgNO3 and Freud's Adjuvant, as amyloidogenic stimulants the authors could exhibit a remarkable and significant increase in mean spleen weights and amount of amyloid deposits during 7 weeks of experiments. However the results of this study are in favor of the results obtained by different investigators using the same compounds but separately (7, 8, 9,10).

As there was no data comparing the amyloidogenic potential of these biologic compounds thus the present study was conducted to evaluate it.

In conclusion our data indicate that both AgNO3 and Freud's Adjuvant (AF) have same amyloidogenic potential, as casein does have, in induction of AA amyloidosis, though their concentrations and frequencies of injections differ.



## References

1. Un-tao Guo, Jin Yu, David Grass, Fredrick C. Debeer, and Mark S. Kindy. (2002) Inflammation-Dependent Cerebral Deposition of Serum Amyloid A Protein in a Mouse Model of Amyloidosis. *The Journal of Neuroscience*. 22,(14):5900-5909.
2. H.Taniyama, A.Kitamura, Y. Kagawa, K. Hirayama, T. Yoshino, AND S. Kamiya. (2000). Localized Amyloidosis in Canine Mammary Tumors. *Vet. Pathol* 37:104-107
3. Francine Gervals, Lise Hebert, and Emill Skamene.( 1988). Amyloid - Enhancing Factor: Production and response in Amyloidosis- Susceptible and Resistant Mouse Strains. *Journal of Leukocyte Biology* 43:311-316.
4. Gilles Grateau, Robert A.Kyle, Martha Skinner. Amyloid and Amyloidosis. *International Symposium on Amyloidosis*. (2004). 10 th Ed.
5. Jen-Hung Yang (2004). Animal models for amyloidosis. *Clinics in dermatology*. 8:2:102-107.
6. R. Bradunaite., D. Povilenaite., L.Leonaviciene., D. Vaitkiene., A.Venalis (2004). Experimental amyloidosis induced by Freund's Adjuvant and casein in two mouse strains. *Amyloid and Amyloidosis*. pp: 231
7. S. Shtrasburg, R.Gal, E.Gruys, S.Pert, B.M. Martin, B.Kaplan, R. Koren, A. Nyska, M. Pars, and A. Livne. An Ancillary Tool for the Diagnosis of Amyloidosis in a Variety of Domestic and Wild Animals(2005). *Vet Path* 42:132 - 139.
8. S. Shtrasburg, M. Pars, N. Breznika, M. Dolitzki, and A. Lvneh( 1999). Pregnancy and Amyloidosis: I. Offspring of amyloidotic mice are not predisposed to develop amyloidosis. *J Lab Clin Med*. Volume 134, No:2.
9. S. Shtrasburg, M. Pars, R.Gal, M. Salai, and A. Lvneh (2001). Inhibition of Second Phase of Amyloidosis in a Mouse Model by a Single - Dose Colchicine Regimen. *J Lab Clin Med*. Volume 138, No:2.
10. M. Umezawa, M. Hosokawa, A. Kohno, S. Ishikawa, K. Kitagawa, and T. Takeda (1993). Dietary soyabean protein compared with casein retards senescence in the senescence accelerated mouse. *The Journal of Nutrition*, 1905- 1910.
11. R. Kisilevsky (2004). Amyloidosis in Vitro: From Molecular Interactions to Therapeutic Targets. *Amyloid and Amyloidosis*. Pp:6-9.

