

Comparative Study of Propensity for Amyloidogenesis in Male and Female Rats

Jamshidi, K.^{1*}, Mortazavi, M.², Daneshvar, A.³

¹Department of Pathobiology, Faculty of Veterinary Medicine, Islamic Azad University, Garmsar Branch, Garmsar-Iran.

²Faculty of Specialized Veterinary Sciences, Islamic Azad University, Sciences and Researches Tehran Branch, Tehran -Iran.

³Graduate from Faculty of Veterinary Medicine, Islamic Azad University, Garmsar Branch, Garmsar-Iran.

*Corresponding Author: kjamshidi48@yahoo.com

دریافت مقاله: ۱۵ مهر ۸۸ پذیرش نهایی: ۲۲ اسفند ۸۸

Abstract

Reactive amyloidosis is a condition that complicates a long list of chronic inflammation, chronic infectious, malignant, and hereditary disorders. In the present study the propensity for amyloidogenesis in male and female rats on spatio-temporal pattern was evaluated. For this purpose a total of 60 male and female Swiss mice, obtained from Pasteur Institute Tehran, after being weighted were randomly divided into 2 treatment groups including 2 groups [10 male (Group A1) and 10 female (Group B1) each], and 2 control groups [10 male (Group A2) and 10 female (Group B2) each]. At the end of 3rd, 5th and 7th weeks of experiment 3 mice were randomly selected and euthanized. Liver, lung, kidney and heart samples of each animal were obtained and preserved in 10% neutral buffer formalin. Sample were then processed through different stages of dehydration, clearing and impregnation and finally embedded in paraffin blocks. Sections of 5µm thickness then cut and stained by alkaline Congo red techniques. The data obtained from microscopic quantitative analysis did show significant differences between groups A1 and B1. A preferential expression of reactive amyloidosis is concluded in male, indicating sex differences in amyloidosis. *Vet. Res. Bull.* 6,1:86-90,2010.

Keywords: amyloid, AgNO₃, Freund's Adjuvant, vitamin free, mice.

مطالعه مقایسه‌ای تمایل جنس در شکل‌گیری آمیلوئیدوز تجربی در موش‌های نر و ماده

کیوان جمشیدی^۱، پژمان مرتضوی^۲، احمدرضا دانشور^۳

۱) گروه پاتوبیولوژی، دانشکده دامپزشکی، دانشگاه آزاد اسلامی واحد گرمسار، گرمسار - ایران. ۲) دانشکده علوم تخصصی دامپزشکی، دانشگاه آزاد اسلامی واحد علوم تحقیقات تهران، تهران - ایران. ۳) دانش آموخته دانشکده دامپزشکی دانشگاه آزاد اسلامی واحد گرمسار، گرمسار - ایران.

چکیده

آمیلوئیدوز راکتیو وضعیتی است که بدنال طیف وسیعی از التهاب‌های مزمن، عفونت‌های مزمن، نئوپلازم‌های بدخیم و اختلالات وراثتی بوجود می‌آید. در مطالعه حاضر حساسیت دو جنس نر و ماده موش در شکل‌گیری الگوی فضایی - زمانی آمیلوئیدوز تجربی مورد بررسی قرار گرفته است. به همین منظور تعداد ۶۰ موش نر و ماده (به نسبت مساوی) (Swiss mice) از انستیتو پاستور تهیه، پس از وزن‌کشی به صورت راندام در ۴ گروه شامل ۳ گروه درمان (گروه A1 (۱۰ نر) و گروه B1 (۱۰ ماده هر کدام) و ۲ گروه کنترل (گروه A2 (۱۰ نر) و گروه B2 (۱۰ سر ماده)) تقسیم شدند. در پایان هفته‌های سوم، پنجم و هفتم مطالعه، ۳ موش از هر گروه به صورت راندام انتخاب و به روش انسانی معدوم شدند. نمونه‌های کبد، ریه، کلیه و قلب از هر موش بطور مجزا در فرمالین بافر خنثی ۱۰٪ تثبیت شد. سپس نمونه‌ها از مراحل مختلف آنگیری، شفاف‌سازی و غوطه‌ورسازی در پارافین عبور داده و نهایتاً بلوک‌های پارافینی از آنها تهیه شد. مقاطع به ضخامت ۵ میکرون از بلوکها تهیه و به روش کنگورد و با استفاده از میکروسکوپ پلاریزه رنگ‌آمیزی شدند. داده‌های اخذ شده از آنالیز میکروسکوپی اسلایدها، اختلافات قابل توجهی بین گروه‌های A1 و B1 نشان دادند. نتیجه حاضر بیان ترجیحی آمیلوئیدوز راکتیو در جنس نر را نشان داده، که بیانگر تاثیر اختلاف جنسی در بروز آمیلوئیدوز تجربی می‌باشد. پژوهشنامه دامپزشکی، ۱۳۸۹، دوره ۵، شماره ۱، ۷۷-۸۶.

واژه‌های کلیدی: آمیلوئید، AgNO₃، فروند آدجوانت، کاروئین بدون ویتامین.

Introduction

Amyloidosis encompasses a diverse group of diseases and is characterized by the extracellular accumulation of fibrillar protein deposits (1). Amyloid is a pathologic proteinaceous substance that produces a collection of diverse clinical syndromes characterized by extracellular deposition of

amorphous, congophilic protein within tissues. Amyloid proteins are distinguished by their twisted β -pleated sheet-fibrillar ultrastructure and made up of nonbranching fibrils of indefinite length and a width of approximately 7.5 - 10 nm. Amyloidosis is divided into systemic and localized forms based on the localization of the amyloid. The systemic form is



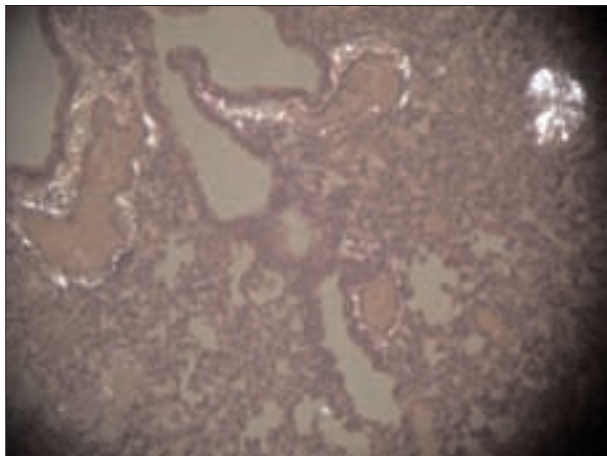


Fig-1: Amyloid deposition in lung, Male Rat, Group A1, Grade 3. Congo Red Staining .

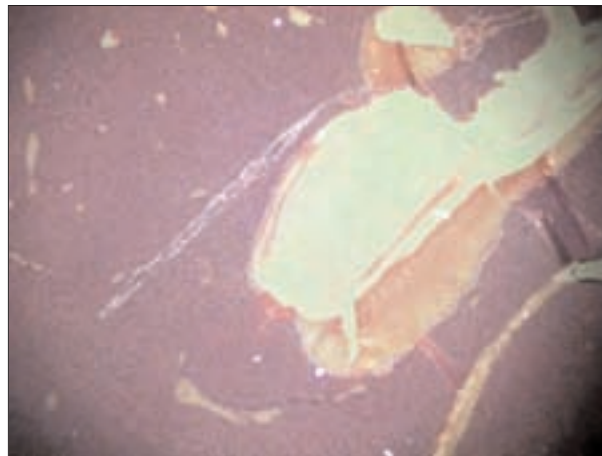


Fig-2: Amyloid deposition in liver, Male Rat, Group A1, Grade 2. Congo Red Staining .

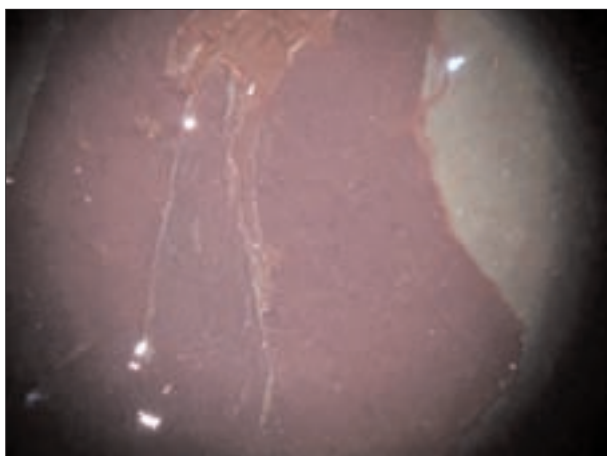


Fig-3: Amyloid deposition in heart, Male Rat, Group A1, Grade 1. Congo Red Staining .




Fig-4: Amyloid deposition in kidney, Male Rat, Group A1, Grade 1. Congo Red Staining .

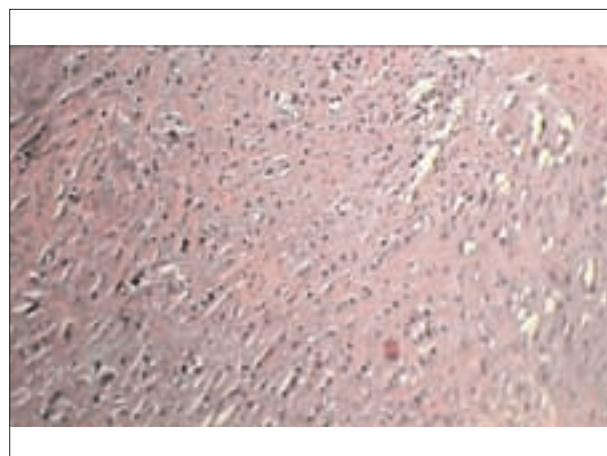


Fig-5 : Amyloid deposition in heart, Female Rat, Group B1, Grade 0. Congo Red Staining .

composed of three types: AL amyloid associated with primary amyloidosis or immunoglobulin dyscrasias, AA amyloid associated with chronic inflammatory processes, and AF amyloid associated with

heredofamilial amyloidosis. The most common types of localized amyloidosis are AE amyloid in the endocrine organs either associated or not associated with neoplastic conditions and AS amyloid associated with senile cardiomyopathy and cerebral plaques (2).

Amyloidosis is one of the human diseases that can be studied in animal models. Kuzcynski, the pioneer in the field of experimental amyloidosis, used casein to induce amyloidosis in mice in 1923. Subsequently this method has been widely used by investigators interested in amyloid research, and the Kuzcynski method is the most popular and easily reproducible model for induction of reactive (secondary) amyloidosis. The availability of such animal model has greatly advanced our understanding of the reactive systemic amyloidosis (5).



Secondary amyloidosis is a serious complication of chronic inflammatory disease, is caused by deposition in the tissues of amyloid A fibrils. It can be induced experimentally in mice following the introduction of various antigenic or inflammatory stimuli. Induction of amyloidosis in mice generally consists of chronic injections of inflammatory stimuli (such as daily s.c. injections of casein, azocasein, or AgNO₃) which trigger production of serum acute-phase proteins such as serum amyloid A (SAA). Serum concentration of SAA increases 100-1000 fold during acute and chronic inflammation (3). The principal diagnostic criterion of amyloidosis, established by Divry and Florkin in 1927, is the detection with a polarizing optical microscope of so-called "apple green birefringence" from Congo red stained tissue sections (4). The male sex is a risk factor for reactive amyloidosis in several disease entities. Environmental, socioeconomic or genetic factors may underlie this male preponderance (7). This study was aimed at discovering the preponency of male sex for amyloidogenesis.

Materials and Methods

Experimental animals: Forty Swiss mice including 20 male and 20 female (31 ± 1 g BW), 5-7 week old purchased from Pasteure Institute - Tehran, were housed in polycarbonate boxes (10 per box) 1 week for acclimation. Drinking water and a commercial feed were available *et libitum*. The animal room was maintained at approximately 22°C and 50% humidity with a 12-h light - dark cycle. On day 0 of experiment, animals after being weighted were randomly assigned to 4 groups including 2 treatment groups [10 male (Group A1) and 10 female (Group B1) each], and 2 control groups [10 male (Group A2) and 10 female (Group B2) each].

Source of chemical compounds: Chemicals including vitamin free casein, as amyloid inducer, purchased from Sigma chemical.

Induction of amyloidosis: For induction of amyloidosis in male and female mice the following protocol was met:

Group A1: subcutaneous injection of 0.5 ml of 12% vitamin free casein per day \times 5 days per week.

Group B1: subcutaneous injection of 0.5 ml of

12% vitamin free casein per day \times 5 days per week.

Group A2: subcutaneous injection of 0.5 ml normal saline per day \times 5 days per week.

Group B2: subcutaneous injection of 0.5 ml normal saline per day \times 5 days per week.

Tissue Sampling and Processing: At the end of 3rd, 5th, and 7th week of experiment three mice randomly selected from each group, and were subjected to necropsy. Liver, lung, kidney and heart samples of each animal were obtained and preserved in 10% neutral buffer formalin. Samples were then processed through different stages of dehydration, clearing and impregnation and finally embedded in paraffin blocks. Sections of 5 μ m thickness then cut and stained by alkaline Congo red techniques (Putchler et al. 1962). As indices of developing amyloidosis a green birefringence under the polarized microscope was considered to be a positive criterion for the presence of amyloid.

Grading Score of Amyloid Deposits: For optical evaluation of amyloidogenic potentials; amyloidotic areas were observed in randomly 10 selected high power fields (40 \times). A light microscope equipped with polarized light optics was used to determine the birefringence intensity of the amyloid deposition in Congo red stained sections. This system was assigned to represent changes in the quantitative appearance and intensity of amyloid deposits in various microscopic fields. Amyloidosis scale was assigned from 0 - 3. In brief the scale was as follows: Grade 0: No birefringence, Grade 1: minimal, Grade 2: moderate, Grade 3: heavy amyloid deposits (6).

Results

The data obtained from microscopic quantitative analysis of tissues were analysed by one - way analysis of variance (ANOVA) and use of SPSS software.

Amyloid density Scale

Relating to amyloid density scale the following results were observed at the end of 3rd, 5th, and 7th weeks of experiment (Tables : 1,2 ,3,4).

LIVER

1- There was no significant difference from



Table - 1 : Amyloid Density Scale in Male Mice (group A1)

Tissue \ Week	3th	5th	7th
Liver	0	1	2
Heart	0	0	1
Kidney	0	1	2
Lung	1	2	3

amyloid density point of view between male and female groups at the end of 3th week of experiment ($p < 0.05$).

2- There was significant difference from amyloid density point of view between male and female groups at the end of 5th week of experiment ($p < 0.05$).

3- There was significant difference from amyloid density point of view between male and female groups at the end of 7th week of experiment ($p < 0.05$).

HEART

1. There was no significant difference from amyloid density point of view between male and female groups at the end of 3th week of experiment ($p < 0.05$).

2. There was NO significant difference from amyloid density point of view between male and female groups at the end of 5th week of experiment ($p < 0.05$).

3. There was significant difference from amyloid density point of view between male and female groups at the end of 7th week of experiment ($p < 0.05$).

KIDNEY

1. There was no significant difference from amyloid density point of view between male and female groups at the end of 3th week of experiment ($p < 0.05$).

2. There was significant difference from amyloid density point of view between male and female groups at the end of 5th week of experiment ($p < 0.05$).

3. There was significant difference from

Table - 2 : Amyloid Density Scale in Male Mice (group A2)

Tissue \ Week	3th	5th	7th
Liver	0	0	0
Heart	0	0	0
Kidney	0	0	0
Lung	0	0	0

Table - 3 : Amyloid Density Scale in Female Mice (group B1)

Tissue \ Week	3th	5th	7th
Liver	0	0	0
Heart	0	0	0
Kidney	0	0	0
Lung	0	0	1

Table - 4 : Amyloid Density Scale in Female Mice (group B2)

Tissue \ Week	3th	5th	7th
Liver	0	0	0
Heart	0	0	0
Kidney	0	0	0
Lung	0	0	0

amyloid density point of view between male and female groups at the end of 7th week of experiment ($p < 0.05$).

LUNG

1. There was significant difference from amyloid density point of view between male and female groups at the end of 3th week of experiment ($p < 0.05$).

2. There was significant difference from amyloid density point of view between male and female groups at the end of 5th week of experiment ($p < 0.05$).

3. There was significant difference from amyloid density point of view between male and female groups at the end of 7th week of experiment



($p < 0.05$).

Discussion

Amyloidosis is defined by the presence in tissues of amyloid, a fibrillar proteinaceous material, which consists of a main protein and common elements. In animal models AA amyloid is classically induced by repetitive subcutaneous injections of casein or azocasein leading to amyloid deposition within 2-3 weeks.

Shtrasburg et. al (2004) in their study subjected male and female Swiss mice to an established amyloid induction protocol and then determined and compared their splenic amyloid, and found more abundant amyloid deposition in male mice. Shtrasburg et. al (2004) in their study revealed the preferential expression of reactive amyloidosis in male mice which was unrelated to the common sex hormones. Increased production of the hormones such as adrenalin, or perhaps an augmented susceptibility to their effect, may cause gender differences by suppressing female amyloidosis (7).

Our study based on histopathological evaluation of tissue sections including lung, liver, kidney and heart, stained by Congo red technique favors the hypothesis leading to sex differences in amyloidogenesis. The results indicate that the male is a risk factor for reactive amyloidogenesis. The maximum and minimum amyloid density/deposition were observed in lung and heart of male mice respectively, which must be considered more in future studies. There must be some tissue predisposing factor for amyloid deposition too. Further validation of our findings in gonadal ablated models and other amyloid induction protocols is warranted.

References

- 1- Un-tao, G., Jin Yu, D., Fredrick, C., Debeer, Kindy, S. (2002) Inflammation-Dependent Cerebral Deposition of Serum Amyloid A Protein in a Mouse Model of Amyloidosis. *Journal of Neuroscience*, **22(14)**:5900-5909.
- 2- Taniyama, H., Kitamura, A., Kagawa, Y., Hirayama,

- K., Yoshino, T., Kamiya, S. (2000) Localized Amyloidosis in Canine Mammary Tumors. *Vet. Pathol*, **37**:104-107
- 3- Francine, G., Lise, H., Emill, S. (1988) Amyloid - Enhancing Factor: Production and response in Amyloidosis- Susceptible and Resistant Mouse Strains. *Journal of Leukocyte Biology*, **43**:311-316.
4. Gilles, G., Robert, A., Kyle, M. (2004) Amyloid and Amyloidosis. *International Symposium on Amyloidosis*, (10).
5. Jen-Hung Yang (2004) Animal models for amyloidosis. *Clinics in dermatology*, **8(2)**:102-107.
6. Bradunaite, R., Povilenaite, D., Eonaviciene, L.L., Vaitkiene, D., Venalis, A. (2004) Experimental amyloidosis induced by Freund's Adjuvant and casein in two mouse strains. *Amyloid and Amyloidosis*, 231.
7. Shtrasburg, S., Pras, M., Dulitzky, M., Pariente, C., Gal, R., Mor, A., Livneh, A. (2004) Increased propensity for amyloidogenesis in male mice. *ClinExp Rheumatol*, **22(4)**:421-426.

