

Nonoxynol-9 berberine plural gel has little effect on expression of SLPI, SP-D and lactoferrin in mice's vagina

Qiao Yuan^{1,3} Ph.D., Chen Zhuo^{1,2} M.D., Ph.D., Ma Yonggui⁴ Ph.D, Lu Fuer^{1,2} M.D., Ph.D., Chen Suhua² M.D., Ph.D., Huang Guangying^{1,2} M.D., Ph.D.

1. Department of Integrated Traditional Chinese and Western Medicine, Tongji Hospital, Tongji Medical College, Huazhong University of Science and Technology, Wuhan, P.R.China.

2. Institute of Integrated Traditional Chinese and Western Medicine, Tongji Medical College, Huazhong University of Science and Technology, Wuhan, P.R.China.

3. Department of Obstetrics and Gynecology, Zhongnan Hospital of Wuhan University, Wuhan, P.R.China.

4. Department of Pharmacy, Tongji Hospital, Tongji Medical College, Huazhong University of Science and Technology, Wuhan, P.R.China.

Corresponding Author:

CHEN Zhuo, Department of Integrated Traditional Chinese and Western Medicine, Tongji Hospital, Tongji Medical College, Huazhong University of Science and Technology, Wuhan, (430030), China.

Email: chenz@tjh.tjmu.edu.cn

Tel/Fax: (+86) 2783663304

Received: 26 July 2012

Accepted: 23 January 2013

Abstract

Background: The most frequently used spermicide Nonoxynol-9 (N-9) in the clinic alters the vaginal flora, which will result in an increased risk of opportunistic infection. So development of a novel spermicidal and microbicidal drug appears to be inevitable. Vaginal local immune is an important part of vaginal flora. Secretory leukocyte protease inhibitor (SLPI), surfactant proteins D (SP-D), and lactoferrin (LF) are anti-microbial molecules with important roles in immune system of female vaginas.

Objective: To observe effect of a vaginal spermicide nonoxynol-9 (N-9) berberine plural gel on the expression of SLPI SP-D and LF in mice's vaginas.

Materials and Methods: Female BABL/C mice were randomly divided into following 5 groups: normal control group, blank gel group, berberine gel group, 12% N-9 gel group and N-9 berberine plural gel group. Estradiol benzoate at physiological dose was done by hypodermic injection to every group's mice. After 72h, drug gels were separately injected into the mice's vaginas, while immunohistochemistry and Western blot were taken to detect the expression of the 3 indexes in mice's vaginas respectively after 24h and 72h of gel injection.

Results: The differences in the three indexes between normal control group and blank gel group were not significant statistically ($p > 0.05$). The expression of the three indexes in 12% N-9 gel group was decreased compared to that in blank gel group ($p < 0.05$). The differences in the three indexes between N-9 berberine plural gel group and blank gel group were not significant statistically ($p > 0.05$). Also, the three index's level of 24h and 72h in sub observation groups after treatment were without statistical significance ($p > 0.05$).

Conclusion: Application of N-9 berberine plural gel had little impact on antimicrobial peptides in normal mice's vaginas.

Key words: Vagina, Anti-infective agents, Mice, Berberine, Nonoxynol-9.

Introduction

Reproductive tract infections (RTIs) were a serious public health problem in most parts of the world.

The World Health Organization (WHO) reckoned that each day one million people acquired a sexually transmitted infection/ RTI, which has reached epidemic proportions throughout the world (1). Failure to combating RTIs at early stage may result in severe complications, including endometritis, uterine sinechiae, salpingitis, pelvic inflammatory disease, as well as female infertility. Topical contraceptives were adopted

widely by women with child-bearing age, because of their excellent features, such as reversibility, voluntary selectivity. As the most common topical contraceptive, Nonoxynol-9 (N-9) may fight against some pathogens of RTIs, but it both stimulated vaginal mucosa and broke the balance of vaginal normal flora at the same time, which limited its use. Vaginal agents with dual function of prevention of RTIs and contraception were gradually focused by researchers (2-6).

Our pre-clinical research found that a new compound N-9 berberine plural gel not only places good synergism of spermicidal, contraceptive effect and bacteriostatic,

bactericidal activity, but reduce side effects of N-9 (7-11). Female reproductive tract (FRT) was a unique immunological site that is required to protect the mucosa from a variety of pathogens. A number of broad-spectrum antimicrobial peptides presented in it prevented and reduced infection by directly interfering with the infectivity of the pathogen or indirectly recruiting innate and adaptive immune cells to FRT (12). Imitating the clinical application of it, N-9 berberine plural gel was applied for one time to acquire the influence on antimicrobial peptides of mice's vaginal flora, including secretory leukocyte protease inhibitor (SLPI), lactoferrin (LF) and surfactant protein D (SP-D). Therefore, the specific objective of this study was to evaluate effects of N-9 berberine plural gel on antimicrobial peptides of mice's vaginal flora, including secretory leukocyte protease inhibitor (SLPI), lactoferrin (LF) and surfactant protein D (SP-D) when applied vaginally for one time.

Materials and methods

Drug and main reagent

Carbomer was taken as stroma and added into berberine or N-9 berberine in a certain proportion, so as to prepare drug gel; blank gel was also prepared with carbomer as stroma in the same proportion. The five gels above were provided by the Department of Pharmacy of Tongji Medical College of Huangzhong University of Science and Technology (Hubei, China); pH=5.0 of all gels was adjusted by NaOH. Estradiol Benzoate (E_2) injection (1mg/ml, KingYork Amino Acid Co., Ltd); rabbit anti-SLPI, goat anti-LF polyclonal antibody, mouse anti-SP-D monoclonal antibody, GAPDH antibody and β -actin antibody were purchased from Santa Cruz Company; protein Marker (Fermentas Company American); SP Immunohistochemistry kit and DAB color kit was bought from Zhongshan Goldenbridge Biotechnology Limited Company.

Animals and grouping

Animal ethical approval was obtained for the experiments reported in this study: approved by Experimental Animal Center of Tongji Medical College of Huazhong University of Science and Technology-Approval number 00000485 and by the Tongji hospital, Tongji Medical College, Huazhong

University of Science and Technology Ethics Committee- Approval number 2012-1203.

100 female BABL/C mice were randomly divided into five groups, with 20 mice in each group. That is, normal control group, blank gel group (stroma control group) (0.3mg/ml), 12% N-9 gel group, berberine gel group and N-9 berberine plural gel group (0.3mg/ml, 50mg berberine +10%N-9), while each group was divided into two sub observation groups, which were 24h and 72h after treatment. Animals were housed in a temperature- and light- controlled room with 12 h light/dark intervals, with free access to food and water.

Before administration, each mouse was treated with the entry of oestrus

Before 72h of administration, each mouse was injected with Estradiol Benzoate (E_2) as pretreatment. E_2 was indicated every other day until the end of the experiment (13). In 24h observation group after treatment, groups were injected E_2 on the first day of the experiment, and once on the third and the fifth day. On the fourth day, vaginal administration was conducted, after 24h of which, the mice were killed by CO_2 asphyxiation for sampling; in 72h observation group after treatment, groups were injected E_2 on the first, third, fifth and seventh day. Vaginal administration was conducted on the fourth day of injection, after 72h of which, the mice were killed by the same method.

Mice's vaginal administration

In all observation groups, 20 μ L corresponding drug gel was indicated intravaginally for one time. The mice were upside down, so as to make sure that the drug was completely contacted with vaginal mucosa. In normal control group, normal saline at the same amount was injected into mice's vaginas, and the same operation was done.

Hematoxylin eosin (HE) staining

A part of vaginal slice in all observation groups were being HE stained. The variations of the pathology in mice vaginas were observed under an optical microscope.

Immunohistochemistry

Slices of mice vaginas from all observation groups were taken out to determine SLPI and SP-D, LF positive expression by

immunohistochemistry SP method, and the method explained by Kumar *et al* (14). PBS was used as a negative control instead of primary antibodies. The first antibodies were rabbit anti- SLPI or goat anti-LF polyclonal antibody, mouse anti-SP-D monoclonal antibody (at a dilution of 1:1000). Under Nikon optical microscope, positive signals were presented as yellowish-brown or brown particles. The image analysis was conducted by Image Pro Plus 5.0, so as to determine positive material expression areas and integral optical density.

Western blot detection

Referring to the instruction of kits, vaginal tissues of each group's mice were taken and added into tissue lysate. Bradford method was used to measure protein concentration. In per sample, 50µg 10% or 15% of SDS-PAGE were taken and wet electro-transferred to Nitrocellulose membrane. The membrane was sealed into 5% skimmed milk powder for 2h at room temperature, and then added into primary antibodies at a dilution 1:1000. It was left overnight at 4°C.

After washing the membrane, goat anti-rabbit second antibody or monkey anti-goat second antibody marked with HRP was added(diluted according to 1: 5000), being incubated for 2h at room temperature. It was developed and exposed by adding ECL after washing the membrane, and film was developed. In order to calculate the relative content value of SLPI, LF and SP-D, integral value of protein banding's optical density was analyzed by American Bio-Rad Quantity One.

Statistical analysis

All the experiments were repeated 3 times. SPSS 17.0 statistical software was adapted to process data, while all experimental measured values were displayed by mean±SD. The data was subjected to one-way ANOVA test, while $p < 0.05$ was considered to be significant.

Results

Vagina HE staining

In all groups, surface middle lamella and stratum basale of mice vaginal stratified epithelium arranged regularly and equally; cell boundary was clear; structure was normal in both nucleus and cytoplasm; mucosa did not show inflammation (Figure 1). There was no

obvious abnormality in morphological changes of the mice's vaginas in 24h and 72h of observation group after treatment (Figure 1B, 1C).

SLPI, SP-D and LF protein expression level

Immunohistochemistry staining results are shown in Figure 2, 4, 6. It was found that SLPI SP-D and LF of all observation groups expressed in the endochylema and cell membrane of vaginal epithelial tissues, presenting to be brown particles.

There was no statistical significance of positive expression level of the three indexes between normal control group and blank gel group in either 24h or 72h ($p=0.420$, 0.135 and 0.508 respectively in 24h, $p=0.508$, 0.383 and 0.788 respectively in 72h) (Figure 2A, Figure 4A, Figure 6A), while compared the expression of N-9 berberine plural gel group with blank gel group, the difference was without statistical significance ($p=0.181$, 0.533 and 0.258 respectively in 24h sub observation groups, $p=0.863$, 0.247 and 0.549 respectively in 72h sub observation groups) (Figure 2B, 2C; Figure 4B, 4C; Figure 6B, 6C). However, expression level of 12% N-9 gel group reduced compared to that of blank gel group ($p=0.000$ in both 24h and 72h sub observation groups) (Figure 2B, 2C; Figure 4B, 4C; Figure 6B, 6C).

When Western blot method was used, target strips can be detected at 11.7 KDa, 47 KDa and 78 KDa (Figure 3, Figure 5, Figure 7) in all observation groups. The difference of three index was without statistical significance between normal control group and blank gel group in either 24h or 72h ($p=0.367$, 0.239 and 0.915 respectively in 24h, $p=0.278$, 0.945 and 0.471 respectively in 72h) (Figure 3A, 3B; Figure 5A, 5B; Figure 7A, 7B); the expression level of the three indexes in 12% N-9 gel group was decreased as compared with those in blank gel group ($p=0.000$, 0.002 and 0.000 respectively in 24h sub observation groups, $p=0.000$ in 72 sub observation groups) (Figure 3A, 3B; Figure 5A, 5B; Figure 7A, 7B); there was no statistical significance in expression level of the three index between N-9 berberine plural gel group and blank gel group ($p=0.185$, 0.586 and 0.636 respectively in 24h sub observation groups, $p=0.214$, 0.979 and 1.000 respectively in 72 sub observation groups), while the three

protein expression level between N-9 berberine plural gel group and 12% N-9 group were of statistical significance ($p= 0.000,0.004$ and 0.000 respectively in 24h sub observation groups, $p= 0.000,0.000$ and 0.002 respectively in 72h sub observation groups) (Figure 3A, 3B; Figure 5A, 5B; Figure 7A, 7B).

Our findings also demonstrated that the expression of SLPI, SP-D and LF between

24h observation group after treatment and corresponding 72h observation group after treatment was also without statistical significance (p values are shown in Figure 3C, Figure 5C, Figure 7C respectively). The results above indicated that vaginal administration of N-9 berberine plural gel had little effect on the expression of SLPI SP-D and LF level in mice vaginas.

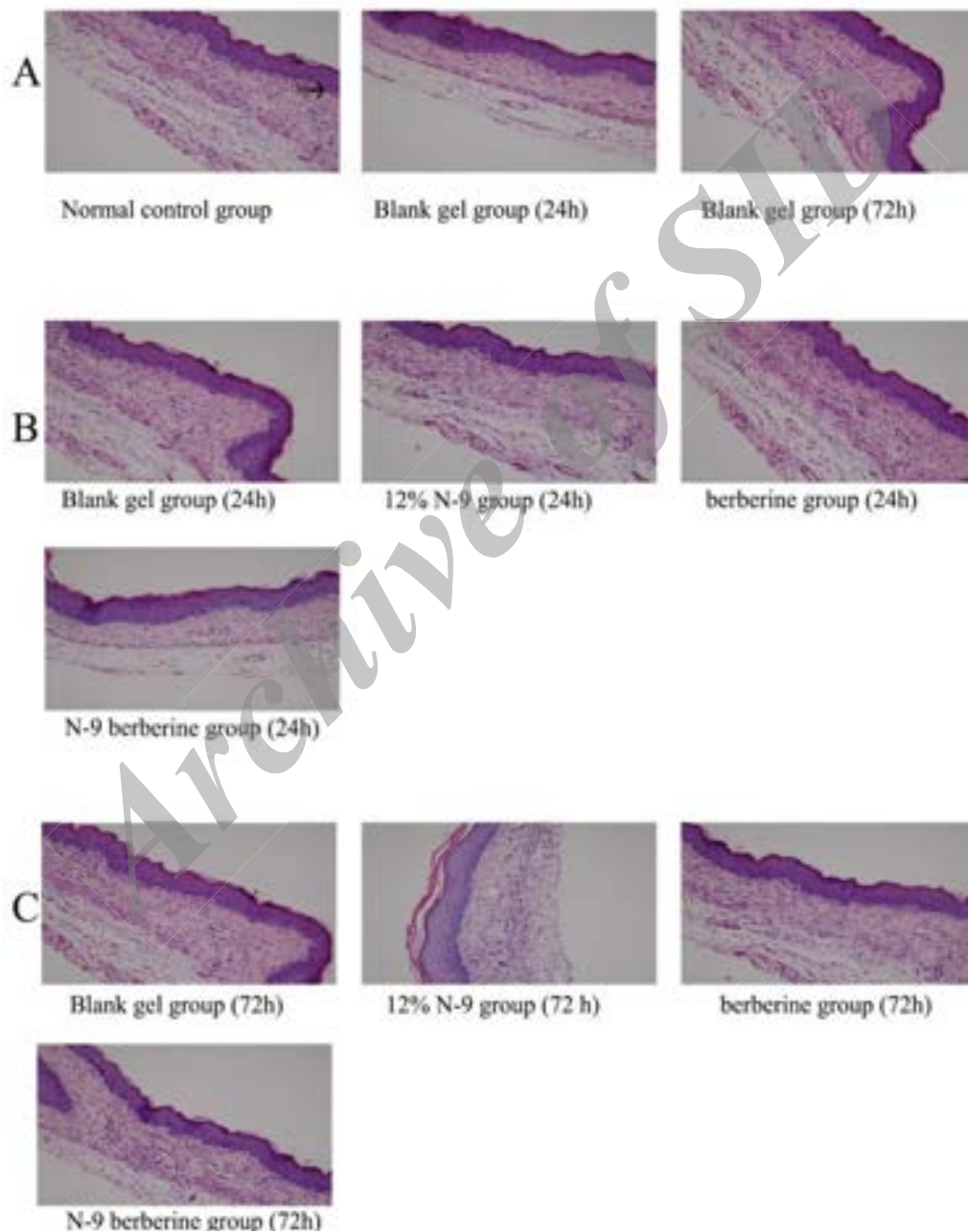


Figure 1. Histology of all observation groups' vaginas under HE staining. (Magnification $\times 200$)

(A) mice vaginas in blank gel groups in vivo;
 (B) mice vaginas in 24 sub observation groups in vivo;
 (C) mice vaginas in 72 sub observation groups in vivo.

S: surface, ML: middle lamella, SB: stratum basale.

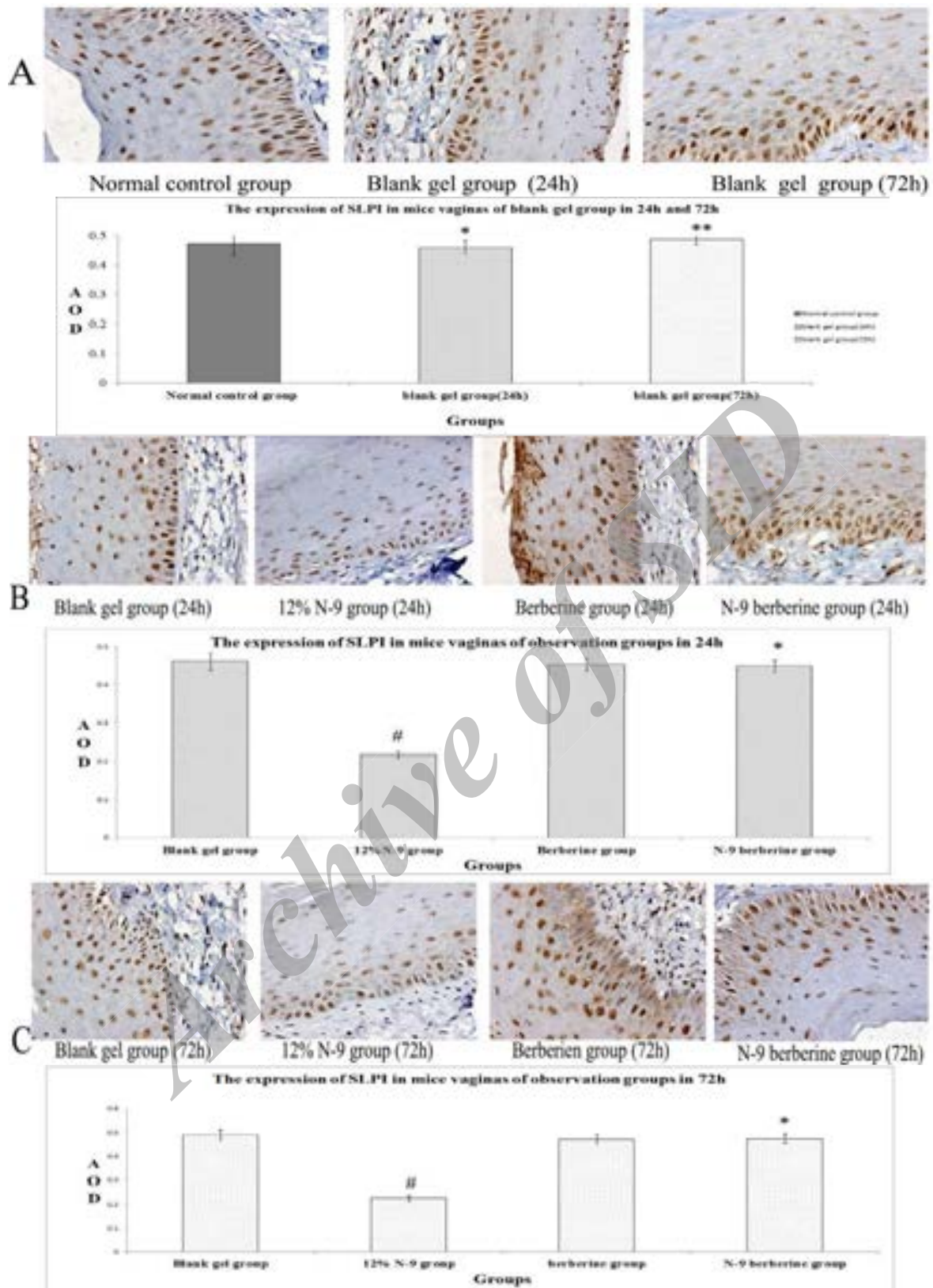


Figure 2. Immunohistochemical detection of SLPI-producing cells in mice's vaginal tissue.

The endochylema and cell membrane of epithelial cells in mice's vaginas are intensely stained.

(A) Representative immunohistochemical staining in blank gel group. Data about average optical density comparisons are shown in following bar chart (*, ** $p > 0.05$ versus normal control group).

(B) Representative immunohistochemical staining in 24 sub observation groups. Data about average optical density comparisons are shown in following bar chart (* $p > 0.05$ versus blank gel group; # $p < 0.05$ versus blank gel group).

(C) Representative immunohistochemical staining in 72 sub observation groups. Data about average optical density comparisons are shown in following bar chart (* $p > 0.05$ versus blank gel group; # $p < 0.05$ versus blank gel group).

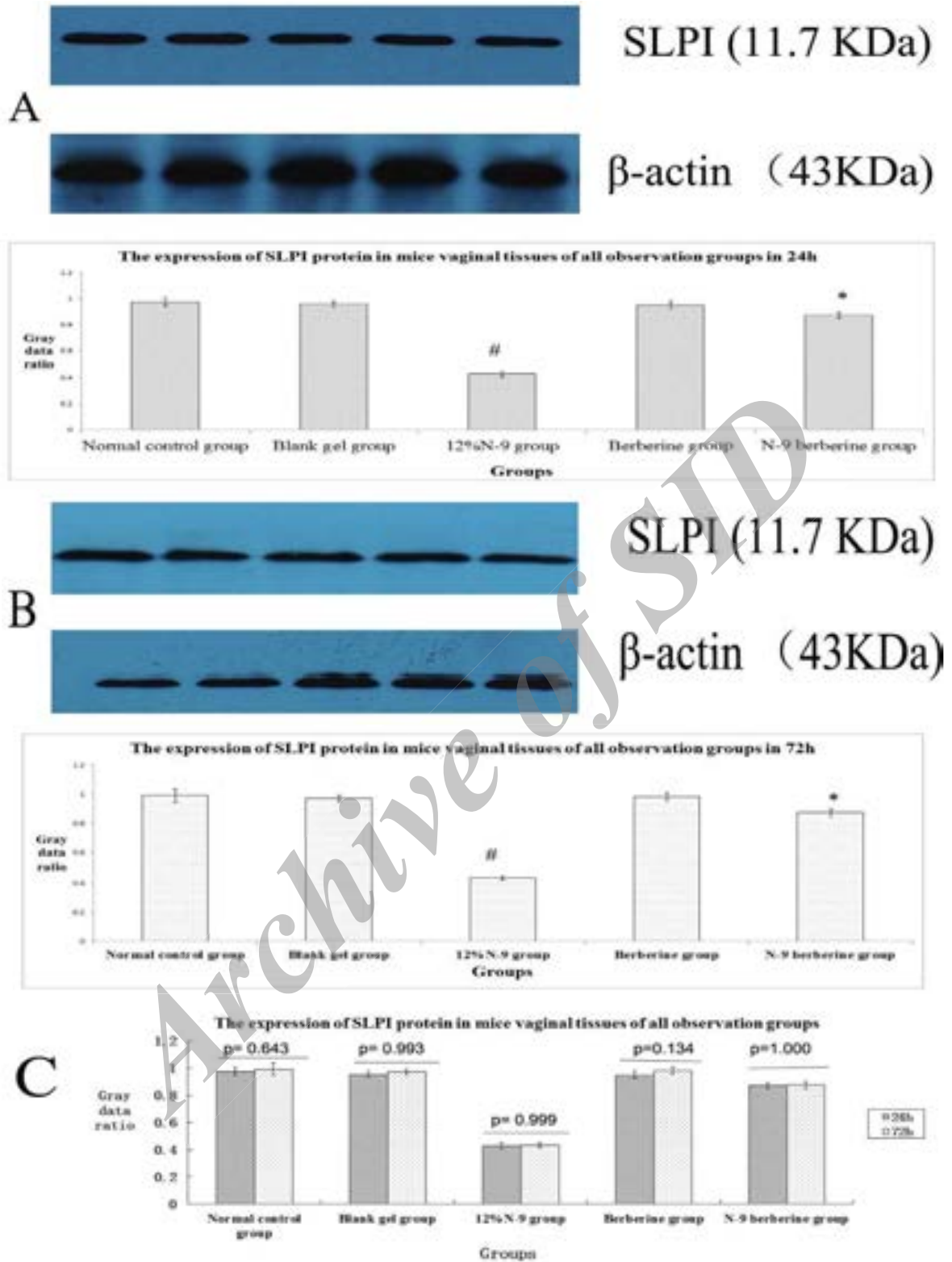


Figure 3. Western blotting of SLPI protein in mice's vaginal tissue.

Western blot method was detected SLPI protein of mice's vaginal tissue and the protein was detected at 11.7KDa; each lane of protein signal corresponded to one label in the abscissa axis of following bar chart.

(A) Representative western blotting of SLPI in 24 sub observation groups (above). Data about gray data ratio comparisons are shown in the bar chart (below) ($p > 0.05$, normal control group versus blank gel group; * $p > 0.05$ versus blank gel group; # $p < 0.05$ versus blank gel group).

(B) Representative western blotting of SLPI in 72 sub observation groups (above). Data about gray data ratio comparisons are shown in the bar chart (below). ($p > 0.05$, normal control group versus blank gel group; * $p > 0.05$ versus blank gel group; # $p < 0.05$ versus blank gel group)

(C) Data about gray data ratio comparisons between 24 and 72 sub observation groups are shown in the bar chart.\

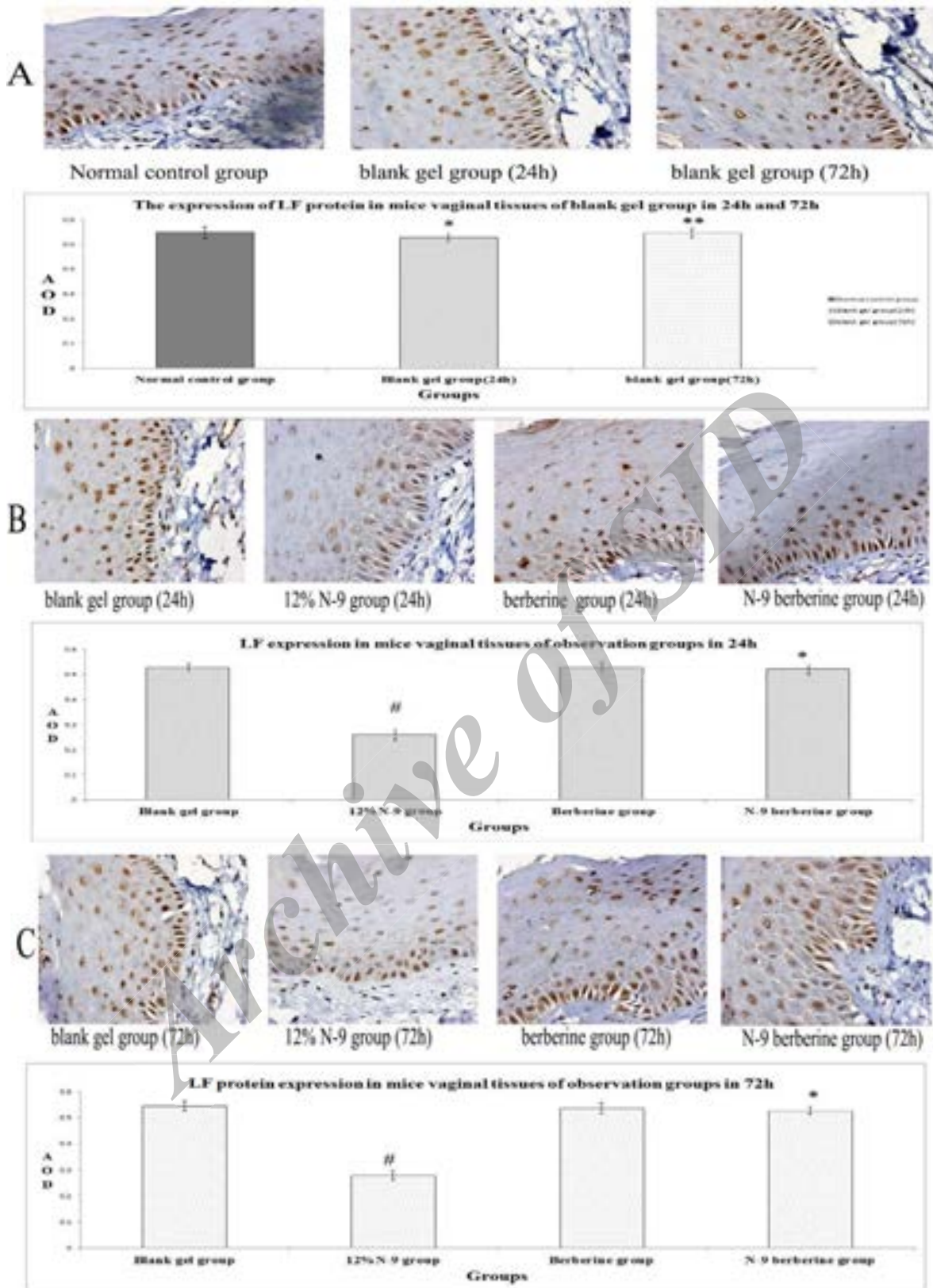


Figure 4. Immunohistochemical detection of LF-producing cells in mice's vaginal tissue.

The endochylema and cell membrane of epithelial cells in mice's vaginas are intensely stained.

(A) Representative immunohistochemical staining in blank gel group. Data about average optical density comparisons are shown in following bar chart (*, ** $p > 0.05$ versus normal control group).

(B) Representative immunohistochemical staining in 24 sub observation groups. Data about average optical density comparisons are shown in following bar chart (* $p > 0.05$ versus blank gel group; # $p < 0.05$ versus blank gel group).

(C) Representative immunohistochemical staining in 72 sub observation groups. Data about average optical density comparisons are shown in following bar chart (* $p > 0.05$ versus blank gel group; # $p < 0.05$ versus blank gel group).

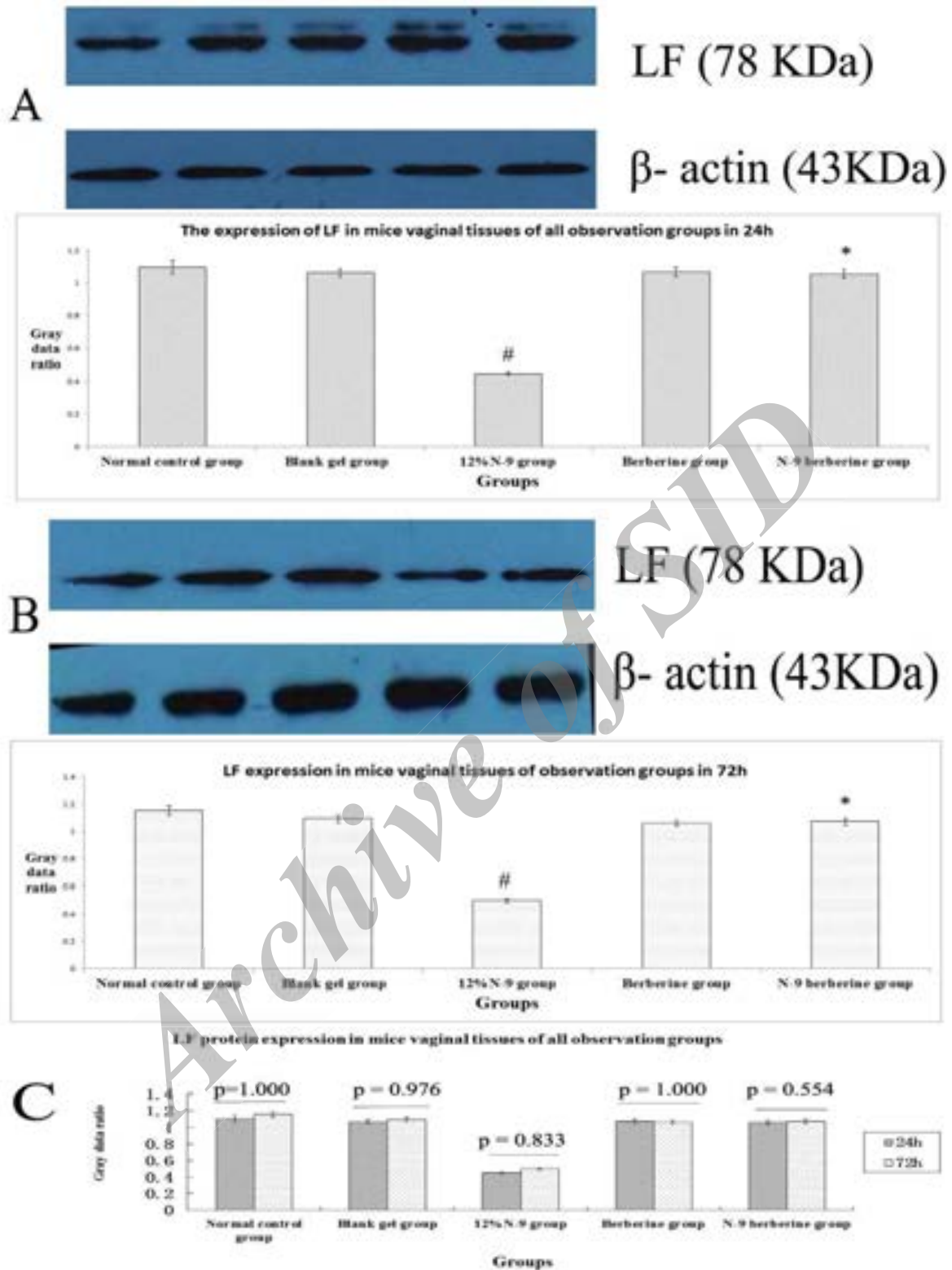


Figure 5. Western blotting of LF protein in mice's vaginal tissue.

Western blot method was detected LF protein of mice's vaginal tissue and the protein was detected at 78KDa; each lane of protein signal corresponded to one label in the abscissa axis of following bar chart.

(A) Representative western blotting of LF in 24 sub observation groups (above). Data about gray data ratio comparisons are shown in the bar chart (below) ($p > 0.05$, normal control group versus blank gel group; $* p > 0.05$ versus blank gel group; $\# p < 0.05$ versus blank gel group).

(B) Representative western blotting of LF in 72 sub observation groups (above). Data about gray data ratio comparisons are shown in the bar chart (below). ($p > 0.05$, normal control group versus blank gel group; $* p > 0.05$ versus blank gel group; $\# p < 0.05$ versus blank gel group)

(C) Data about gray data ratio comparisons between 24 and 72 sub observation groups are shown in the bar chart.

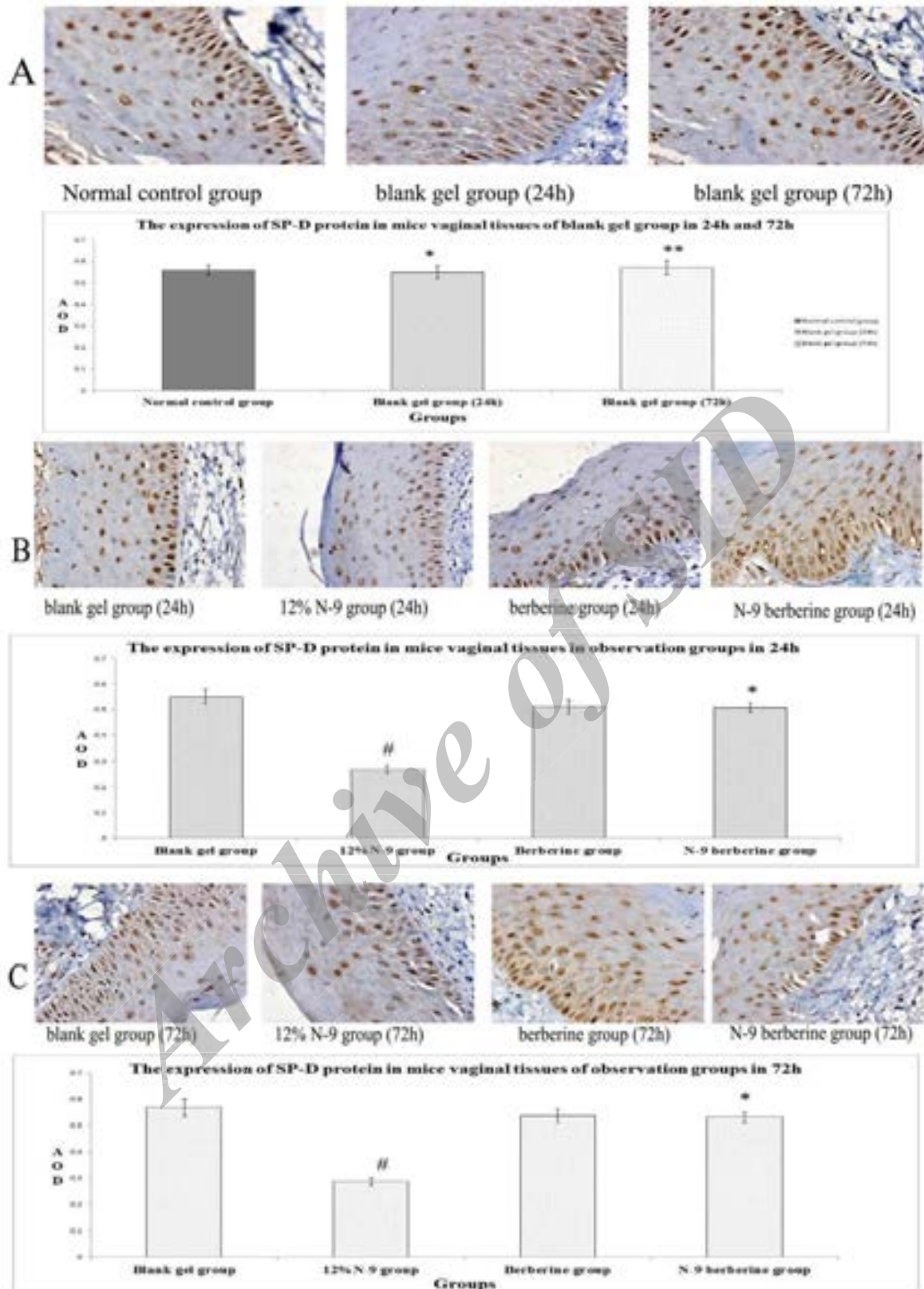


Figure 6. Immunohistochemical detection of SP-D-producing cells in mice's vaginal tissue.

The endochylema and cell membrane of epithelial cells in mice's vaginas are intensely stained.

(A) Representative immunohistochemical staining in blank gel group. Data about average optical density comparisons are shown in following bar chart (*, ** $p > 0.05$ versus normal control group).

(B) Representative immunohistochemical staining in 24 sub observation groups. Data about average optical density comparisons are shown in following bar chart (* $p > 0.05$ versus blank gel group; # $p < 0.05$ versus blank gel group).

(C) Representative immunohistochemical staining in 72 sub observation groups. Data about average optical density comparisons are shown in following bar chart (* $p > 0.05$ versus blank gel group; # $p < 0.05$ versus blank gel group).

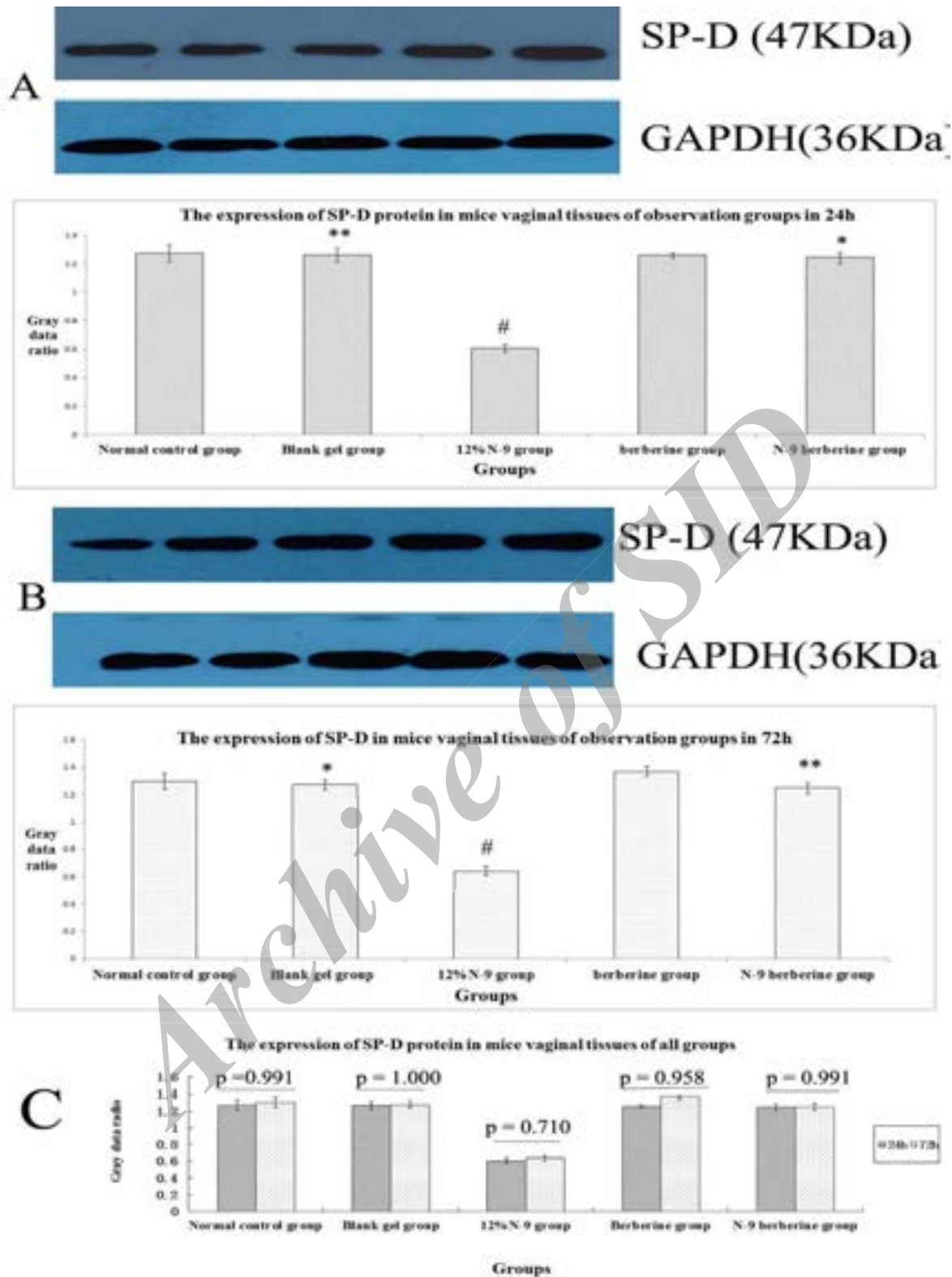


Figure 7. Western blotting of SP-D protein in mice's vaginal tissue.

Western blot method was detected SP-D protein of mice's vaginas in five groups and the protein was detected at 47 KDa; each lane of protein signal corresponded to one label in the abscissa axis of following bar chart.

- (A) Representative western blotting of SP-D in 24 sub observation groups (above). Data about gray data ratio comparisons are shown in the bar chart (below) ($p > 0.05$, normal control group versus blank gel group; * $p > 0.05$ versus blank gel group; # $p < 0.05$ versus blank gel group).
- (B) Representative western blotting of LF in 72 sub observation groups (above). Data about gray data ratio comparisons are shown in the bar chart (below). ($p > 0.05$, normal control group versus blank gel group; * $p > 0.05$ versus blank gel group; # $p < 0.05$ versus blank gel group)
- (C) Data about gray data ratio comparisons between 24 and 72 sub observation groups are shown in the bar chart.

Discussion

Berberine had ranges of anti-inflammatory and anti-bactericidal functions. Iwasa *et al* found that aromatic ring C contained in its quaternary ammonium structure was necessary for antibiotic activity of Berberine (15-17). Berberine gel, the essential component of No.1 Jieze Gel, which has been used for curing cervical erosion and vaginitis for many years in our hospital, was curative. N-9 was a nonionic surfactant, being a killing-sperm drug of external application acknowledged internationally (18). However, its frequent use would dramatically damage cervicovaginal mucosal cells, increased the occurrence of vaginal lesions and elevated proinflammatory cytokines in cervicovaginal secretions, ultimately leading to the increased chance of infection. In addition, the side effect was positively correlated with the dose of N-9 (19-21).

Our pre-study research found that N-9 berberine plural gel not only prevents *Candida albicans* vaginitis and *Trichomonas vaginitis*, but shows apparent effects of sperm-killing and antifertility on both rabbit and mice, which reduce the dose use of N-9 in clinic: the difference in antifertility incidence between N-9 berberine plural gel (10% N-9 contained) and 12% N-9 gel was without statistical significance (7, 8, 10, 11). In this study, we compared the influence of N-9 berberine plural gel with 12% N-9 gel on the vaginal antimicrobial peptides at 24h and 72h after treatment. Normal mice estrus was generally 8-24h, which was too short to grasp. Consequently each mouse was injected estrogen at physiological dose every other day to maintain mice estrus (13).

The mucosal surfaces of the human FRT were protected against pathogens by both the innate and the adaptive immunity. SLPI, SP-D and LF were important antimicrobials, which had a synergistic effect on innate immune in the FRT. The decrease of these may cause low defensiveness in genital tract, which could correlate with susceptibility to RTIs (22). Our results suggested that expression level of three indexes in 12% N-9 gel group were decreased, while vaginal N-9 berberine plural gel for one time had little influence on the expression of SLPI, LF and SP-D. SLPI expression in the human vaginas was decreased by certain pathogens, including

Trichomonas, *Pseudomonas*, *Staphylococcus aureus*, *Chlamydia* and *Candida albicans* (23).

Some scholars considered that it was related to the positive ion destroying the surface of bacterial cell membrane (24). Clinical trials had demonstrated the high efficiency of LF against infections in inflammatory diseases, such as bacteria, viruses and fungi. The antimicrobial mechanisms of LF were considered to be at least three aspects: it bound iron molecules with high affinity, which inhibited bacterial growth by sequestering free iron under acidic conditions; it augmented the permeability of bacterial cell membrane, leading to LPS liberation from tunica externa; it produced antimicrobial peptides and antibacterial action via hydrolyzation (25, 26).

SP-D was a candidate molecule to prevent vaginal infection in vaginal mucosal surfaces. SP-D recognized non-self-carbohydrates and lipid moieties on the surface of bacterial, fungal and viral pathogens, and then mediated their elimination (27, 28). It enhanced the uptake of pathogens through different mechanisms, including opsonizing the pathogens, activating ligands and regulating cell-surface-receptor expression (29).

Conclusion

In conclusion, N-9 berberine plural gel demonstrated broad-spectrum activity in the previous tested animal models (9, 30, 31). These results, combined with the little influence of it on the antimicrobial peptides in normal mice vaginas, suggested that N-9 berberine plural gel may prove to be useful as a vaginal spermicidal in human, and that clinical evaluation of its spermicidal and microbicidal activities were warranted.

Acknowledgments

The present work was supported by the Grant of Hubei Province Family Planning Special Fund (No.JS-20100001) and Wuhan Science and Technology Projects (No.200960323131).

Conflict of interest

The authors declare that they have no competing interests.

References

- Hickey DK, Patel MV, Fahey JV, Wira CR. Innate and adaptive immunity at mucosal surfaces of the female reproductive tract: stratification and integration of immune protection against the transmission of sexually transmitted infections. *J Reprod Immunol* 2011; 88: 185-194.
- Baptista M, Ramalho-Santos J. Spermicides, microbicides and antiviral agents: recent advances in the development of novel multi-functional compounds. *Mini Rev Med Chem* 2009; 9: 1556-1567.
- Iyer V, Poddar SS. Update on nonoxynol-9 as vaginal spermicide. *Eur J Contracept Reprod Health Care* 2008; 13: 339-350.
- Aitken RJ, Carey AJ, Beagley KW. Dual purpose contraceptives: targeting fertility and sexually transmitted disease. *J Reprod Immunol* 2011; 88: 228-232.
- Abdool KS, Richardson BA, Ramjee G, Hoffman IF, Chirenje ZM, Taha T, et al. Safety and effectiveness of BufferGel and 0.5% PRO2000 gel for the prevention of HIV infection in women. *Aids* 2011; 25: 957-966.
- Obiero J, Mwethera PG, Wiysonge CS. Topical microbicides for prevention of sexually transmitted infections. *Cochrane Database Syst Rev* 2012; 6: D7961.
- Chen Z, Wang R, Ma YG. [Spermicidal and antifertility effects of Jieze NO.2 jel in rabbits]. *Matern Child Health Care China* 2009; 27: 3855-3858. (In Chinese)
- Kong XF, Chen Z, Xu P. [Spermicidal effect of Jieze NO.2 in vitro and its intravaginal contraceptive effect in rats]. *Matern Child Health Care China* 2009; 29: 4140-4143. (In Chinese)
- Chen Z, Wang R, Ma YG, Kong XF, Lu FE, Huang GY. [The effect of Jieze NO.2 jel on trichomonas vaginitis in rats]. *Matern Child Health Care China* 2009; 5: 344-346. (in Chinese)
- Chen Z, Wang R, Ma YG. [Effect of Jieze NO.2 on trichomonas vaginitis in vitro]. *Maternal Child Health Care China* 2009; 3: 344-346. (In Chinese)
- Chen Z, Kong XF, Wang R. [Investigation on prevention effects of Jieze NO.2 on candida albicans vaginitis]. *Matern Child Health Care China* 2009; 6: 788-790. (In Chinese)
- Buckner LR, Schust DJ, Ding J, Nagamatsu T, Beatty W, Chang TL, et al. Innate immune mediator profiles and their regulation in a novel polarized immortalized epithelial cell model derived from human endocervix. *J Reprod Immunol* 2011; 92: 8-20.
- Fidel PJ, Cutright J, Steele C. Effects of reproductive hormones on experimental vaginal candidiasis. *Infect Immun* 2000; 68: 651-657.
- Kumar R, Vicari M, Gori I, Achtari C, Fiche M, Surbeck I, et al. Compartmentalized secretory leukocyte protease inhibitor expression and hormone responses along the reproductive tract of postmenopausal women. *J Reprod Immunol* 2011; 92: 88-96.
- Imanshahidi M, Hosseinzadeh H. Pharmacological and therapeutic effects of *Berberis vulgaris* and its active constituent, berberine. *Phytother Res* 2008; 22: 999-1012.
- Yan D, Jin C, Xiao XH, Dong XP. Antimicrobial properties of berberines alkaloids in *Coptis chinensis* Franch by microcalorimetry. *J Biochem Biophys Methods* 2008; 70: 845-849.
- Iwasa K, Nanba H, Lee DU, Kang SI. Structure-activity relationships of protoberberines having antimicrobial activity. *Planta Med* 1998; 64: 748-751.
- Wei H, Chen Z, Xu P, Ma YG, Xu LJ. Effect of Jieze No.1 on cervicitis caused by ureaplasma urealyticum and on ureaplasma urealyticum in vitro. *Chin J Integr Med* 2008; 14: 88-93.
- Phillips DM, Sudol KM, Taylor CL, Guichard L, Elsen R, Maguire RA. Lubricants containing N-9 may enhance rectal transmission of HIV and other STIs. *Contraception* 2004; 70: 107-110.
- Roberts JN, Buck CB, Thompson CD, Kines R, Bernardo M, Choyke PL, et al. Genital transmission of HPV in a mouse model is potentiated by nonoxynol-9 and inhibited by carrageenan. *Nat Med* 2007; 13: 857-861.
- Beer BE, Doncel GF, Krebs FC, Shattock RJ, Fletcher PS, Buckheit RJ, et al. In vitro preclinical testing of nonoxynol-9 as potential anti-human immunodeficiency virus microbicide: a retrospective analysis of results from five laboratories. *Antimicrob Agents Chemother* 2006; 50: 713-723.
- Wira CR, Patel MV, Ghosh M, Mukura L, Fahey JV. Innate immunity in the human female reproductive tract: endocrine regulation of endogenous antimicrobial protection against HIV and other sexually transmitted infections. *Am J Reprod Immunol* 2011; 65: 196-211.
- King AE, Wheelhouse N, Cameron S, McDonald SE, Lee KF, Entrican G, et al. Expression of secretory leukocyte protease inhibitor and elafin in human fallopian tube and in an in-vitro model of Chlamydia trachomatis infection. *Hum Reprod* 2009; 24: 679-686.
- Nishimura J, Saiga H, Sato S, Okuyama M, Kayama H, Kuwata H, et al. Potent antimycobacterial activity of mouse secretory leukocyte protease inhibitor. *J Immunol* 2008; 180: 4032-4039.
- Jenssen H, Hancock RE. Antimicrobial properties of lactoferrin. *Biochimie* 2009; 91: 19-29.
- Sandrini SM, Shergill R, Woodward J, Muralikuttan R, Haigh RD, Lyte M, et al. Elucidation of the mechanism by which catecholamine stress hormones liberate iron from the innate immune defense proteins transferrin and lactoferrin. *J Bacteriol* 2010; 192: 587-594.
- Kishore U, Greenhough TJ, Waters P, Shrive AK, Ghai R, Kamran MF, et al. Surfactant proteins SP-A and SP-D: structure, function and receptors. *Mol Immunol* 2006; 43: 1293-1315.
- Teclé T, White MR, Gantz D, Crouch EC, Hartshorn KL. Human neutrophil defensins increase neutrophil uptake of influenza A virus and bacteria and modify virus-induced respiratory burst responses. *J Immunol* 2007; 178: 8046-8052.
- Wright JR. Immunoregulatory functions of surfactant proteins. *Nat Rev Immunol* 2005; 5: 58-68.
- Wei H, Chen Z, Xu P, Ma YG, Xu LJ. Effect of Jieze No.1 on Cervicitis Caused by Ureaplasma Urealyticum and on Ureaplasma Urealyticum in vitro. *Chin J Integr Med* 2008.
- Xu P, Chen Z, Xu L, Lu F. Spermicidal effect of Jieze No. 1 in combination with nonoxynol-9 in vitro. *J Huazhong Univ Sci Technol Med Sci* 2005; 25: 225-228.