

## Pelvic abscess after oocyte retrieval in women with endometriosis: A case series

*Bárbara Romero<sup>1</sup> M.D., Ph.D., Laura Aibar<sup>2</sup> M.D., Ph.D., Luis Martínez Navarro<sup>1</sup> M.D., Ph.D., Juan Fontes<sup>1</sup>, M.D., Ph.D., Maria-Angeles Calderón<sup>1</sup> M.D., Ph.D., Juan Mozas<sup>1</sup> M.D., Ph.D.*

1. Reproduction Unit, University Hospital Virgen de las Nieves, Granada, Spain.

2. Department of Obstetrics and Gynecology, Hospital of Santa Barbara, Puertollano (Ciudad Real), Spain.

### Corresponding Author:

Luis Martínez Navarro, Reproduction Unit, Virgen de las Nieves University Hospital, Avenida de las Fuerzas Armadas s/n, 18014 Granada, Spain.

Email: luis.martinez.navarro.sspa@juntadeandalucia.es

Tel/Fax: (+34) 958020052

Received: 2 December 2012

Accepted: 13 March 2013

### Abstract

**Background:** Pelvic inflammatory disease with progression to pelvic abscess is a rare complication after oocyte retrieval during in vitro fertilization cycles. However, in patients with endometriosis the risk appears to be increased. Many authors agree on the need for antibiotic prophylaxis during the oocyte retrieval in these patients, but there is no consensus regarding the best antibiotic.

**Case:** We discuss 3 clinical cases of tubo-ovarian abscess in women with endometriosis after oocyte retrieval despite antibiotic prophylaxis between 2004 and 2011 at our center, and discuss our experience in the context of earlier reports.

**Conclusion:** It is unclear whether antibiotic prophylaxis is necessary in these women, and which antibiotic is best. Only douching with povidone-iodine appears to decrease the rate of pelvic infection.

**Key words:** Oocyte retrieval, In vitro fertilization, Endometriosis, Pelvic inflammatory disease.

### Introduction

Endometriosis occurs in 25% to 50% of women with infertility (1, 2). In vitro fertilization is an effective treatment for these women, and although pelvic inflammatory disease (PID) is an infrequent complication of oocyte retrieval (OR) (0.3-0.4%), endometriosis is a risk factor to date only 9 cases of abscess after OR have been reported (3-15). We describe 3 cases of pelvic abscess after OR in women with endometriosis in southern Spain between 2004 and 2011.

### Case series

#### Case 1

A 29 year old woman with a history of right ovarian cystectomy for endometriosis and severe adhesion syndrome was given 1500 mg cefuroxime intravenously during OR. Two bilateral endometriomas were seen and were not punctured. She became pregnant but later miscarried. During the second cycle cefuroxime was again used for prophylaxis during OR and the endometriomas were not punctured. She did not get pregnant.

One month later she was hospitalized for an 8 cm pelvic abscess that required surgical

drainage after her clinical status had improved with intravenous antibiotics.

#### Case 2

A 32 year old woman with a 3 cm endometrioma diagnosed by ultrasound in her right ovary received vaginal douching during OR with povidone-iodine and saline solution. In addition, 1 g azithromycin was given orally and 1 g ceftriaxone was given intravenously in a single doses. Her endometrioma was punctured during OR. She did not get pregnant. Two months later she was hospitalized for a 9 cm pelvic abscess that did not resolve with intravenous antibiotics and required surgical drainage (Figure 1).

#### Case 3

A 37 year old woman with a history of right ovarian cystectomy for endometriosis received vaginal douching during OR with povidone-iodine and saline solution; in addition, 1 g azithromycin was given orally. A 4 cm endometrioma was seen and was not punctured. She did not conceive. Three weeks later she was hospitalized for a 9 cm pelvic abscess (Figure 2), and responded favorably to intravenous antibiotic treatment. However, her abscess required surgical drainage and necessitated right adnexectomy.

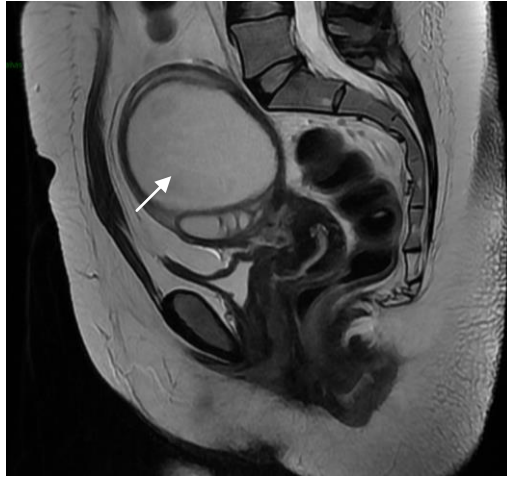


Figure 1. Pelvic abscess in a 32 years old women (Case 2).

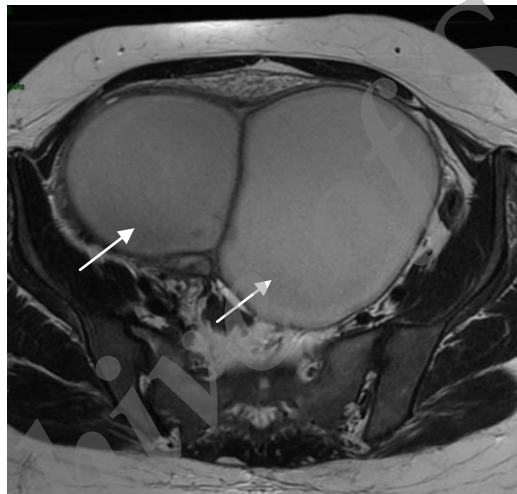


Figure 2. Pelvic abscess in a 37 years old women (Case 3).

## Discussion

The frequency of PID after OR is difficult to establish since it is a rare complication. At our center, of 4319 OR procedures done between 2004 and 2011, there were only 3 cases of pelvic abscess (0.07%), all in women with endometriosis. One of the limitations that may contribute to this low complication rate is the lack of a pathological diagnosis of endometriosis, although the sensitivity and specificity of the diagnosis of endometrioma with ultrasonography were shown to be high (16). In two of our patients the diagnosis was confirmed pathologically, but in the third patient the diagnosis was based on ultrasound findings only.

Moini *et al* identified 10 cases of PID among 5958 OR procedures, and 8 of these

women had endometriosis (7). Chen *et al* analysed the association between endometriosis and pelvic abscesses in 3215 women and concluded that old blood in the endometrioma was an excellent culture medium; accordingly, they considered endometriosis to be an important risk factor for PID (10).

Surgical treatment of endometriomas reduces the risk at the expense of diminishing follicular reserve, and thus prolonging stimulation cycles and increasing the cost of in vitro fertilization (17-20). Both the Royal College of Obstetricians and Gynecologists and the European Society of Human Reproduction and Embryology recommend resection for endometriomas measuring 4 cm or larger in order to reduce the risk of infection, among other aims (21, 22).

Although there is no evidence of the efficacy of antibiotic prophylaxis during OR, most authors have used prophylaxis for women with endometriosis (23). Benaglia *et al* attempted to determine the frequency of pelvic abscesses in women after OR who were treated prophylactically with ceftriaxone 1 g intramuscularly for 4 days (24). Among 214 OR procedures, the involved ovary was not punctured in 12% of the cases, and in 3% the endometrioma was punctured accidentally. There were no cases of abscess.

Egbase *et al* used ceftriaxone 2 g+ metronidazole 1 g intravenously, and among cultures of the embryo transfer catheter, 78% were negative, versus 30.9% in women who were not given prophylactic antibiotics (25). The conception rate was lower in women with a positive culture (18.7% vs. 41.3%). Weinreb *et al* treated oocyte donors prophylactically with cefoxitin 2 g or clindamycin 900 mg intravenously, and found that this reduced the risk of PID by 0.4% to 0% (26). However, the use of cefazolin for prophylaxis by Younis *et al* did not prevent the appearance of PID (9).

To our knowledge only 9 cases of pelvic abscess after OR in women with endometriosis have been reported in 7 different studies (7, 9, 11-15). Eight of these women had received antibiotic prophylaxis, and in 6 of them the endometrioma had been punctured. These numbers suggest that antibiotic prophylaxis is not effective in preventing PID, although it would be interesting to know how many cases have been prevented by prophylaxis. Pelvic abscesses after OR may be underreported, as the present case series appears to suggest.

At our centre all women with endometriosis who undergo in vitro fertilization are given antibiotics prophylactically during OR with azithromycin 1 g orally or ceftriaxone 1 g intramuscularly, or less frequently with cefuroxime 1500 mg or cefazolin 2 g intravenously. Yet despite antibiotic prophylaxis, 3 of the women at our centre developed pelvic abscesses (which required hospital treatment), and one woman, as in the study by Younis *et al* was resistant to antibiotic treatment (9). The endometrioma was punctured in only 1 of the 3 women described here, and 2 of them had a history of ovarian surgery- an antecedent that Chen *et al* identified as an additional risk factor (10).

Tsai *et al* showed that vaginal douching with povidone-iodine before OR decreased the risk of o PID, although Van Os *et al* reported a lower conception rate in these women (8, 27). Hannoun *et al* have suggested the use of povidone-iodine followed by saline solution (28). Other preventive measures are the use of strict asepsis in the surgical field, avoiding successive punctures of the vaginal wall and ovarian capsule, and avoiding puncture and aspiration of the endometrioma during OR (23, 24).

## Conclusion

Endometriomas 4 cm in diameter or larger should be respected. It is unclear whether antibiotic prophylaxis should be used during OR, or which agents are the most effective. Vaginal douching with povidone-iodine followed by saline solution appears to reduce the risk of PID.

## Acknowledgments

This case series was supported by the Virgen de las Nieves University Hospital in Granada. Consent was obtained from the patients for this presentation. We thank the staff of the Obstetrics and Gynecology Department for their help with the cases reported above, and K. Shashok for translating the manuscript into English.

## References

1. Verkauf BS. The incidence, symptoms, and signs of endometriosis in fertile and infertile women. *J Fla Med Assoc* 1987; 74: 671-675.
2. Coccia ME, Rizzello F, Cammilli, Bracco GL, Scarselli G. Endometriosis and infertility Surgery and ART: An integrated approach for successful management. *Eur J Obstet Gynecol Reprod Biol* 2008; 138: 54-59.
3. Barnhart K, Dunsmoor-Su R, Coutifaris C. Effect of endometriosis on in vitro fertilization. *Fertil Steril* 2002; 77: 1148-1155.
4. Kenedy S, Bergqvist A, Chapron C, D'Hooghe T, Dunselmar G, Greb R, et al. ESHRE Special Interest Group for Endometriosis and Endometrium Guideline Development Group. ESHRE guidelines for the diagnosis and treatment of endometriosis. *Hum Reprod* 2005; 20: 2698-2704.
5. Govaerts I, Devreker F, Delbaere A, Revelard P, Englert Y. Short-term medical complications of 1500 oocyte retrievals for in vitro fertilization and embryo transfer. *Eur J Obstet Gynecol Reprod Biol* 1998; 77: 239-243.

6. Bergh T, Lundkvist O. Clinical complications during in-vitro fertilization treatment. *Hum Reprod* 1992; 7: 625-626.
7. Moini A, Riazi K, Amid V, Ashrafi M, Tehraninejad E, Madani T, Owj M. Endometriosis may contribute to oocyte retrieval-induced pelvic inflammatory disease: report of eight cases. *J Assist Reprod Genet* 2005; 22: 307-309.
8. Tsai YC, Lin MY, Chen SH, Chung MT, Loo TC, Huang KF, et al. Vaginal disinfection with povidone iodine immediately before oocyte retrieval is effective in preventing pelvic abscess formation without compromising the outcome of IVF-ET. *J Assist Reprod Genet* 2005; 22: 173-175.
9. Younis JS, Ezra Y, Laufer N, Ohel G. Late manifestation of pelvic abscess following oocyte retrieval, for in vitro fertilization, in patients with severe endometriosis and ovarian endometrioma. *J Assist Reprod Genet* 1997; 14: 343-346.
10. Chen MJ, Yang JH, Yang YS, Ho HN. Increased occurrence of tubo-ovarian abscesses in women with stage III and IV endometriosis. *Fertil Steril* 2004; 82: 498-499.
11. Yaron Y, Peyser MR, Samuel D, Amit A, Lessing JB. Infected endometriotic cysts secondary to oocyte aspiration for in-vitro fertilization. *Hum Reprod* 1994; 9: 1759-1760.
12. Padilla SL. Ovarian abscess following puncture of an endometrioma during ultrasound-guided oocyte retrieval. *Hum Reprod* 1993; 8: 1282-1283.
13. den Boon J, Kimmel CE, Nagel HT, van Roosmalen J. Pelvic abscess in the second half of pregnancy after oocyte retrieval for in-vitro fertilization: case report. *Hum Reprod* 1999; 14: 2402-2403.
14. Matsunaga Y, Fukushima K, Nozaki M, Nakanami N, Kawano Y, Shigematsu T, et al. A case of pregnancy complicated by the development of a tubo-ovarian abscess following in vitro fertilization and embryo transfer. *Am J Perinatol* 2003; 20: 277-282.
15. Sharpe K, Karovitch AJ, Claman P, Suh KN. Transvaginal oocyte retrieval for in vitro fertilization complicated by ovarian abscess during pregnancy. *Fertil Steril* 2006; 86: 219.e11-13.
16. Mais V, Guerriero S, Ajossa S, Angiolucci M, Paoletti AM, Melis GB. The efficiency of transvaginal ultrasonography in the diagnosis of endometrioma. *Fertil Steril* 1993; 60: 776-780.
17. Demirel A, Guven S, Baykal C, Gurgan T. Effect of endometrioma cystectomy on IVF outcome: a prospective randomized study. *Reprod Biomed Online* 2006; 12: 639-643.
18. Geber S, Ferreira DP, Spyer Prates LF, Sales L, Sampaio M. Effects of previous ovarian surgery for endometriosis on the outcome of assisted reproduction treatment. *Reprod Biomed Online* 2002; 5: 162-166.
19. Esinler I, Bozdogan G, Aybar F, Bayar U, Yarali H. Outcome of in vitro fertilization/intracytoplasmic sperm injection after laparoscopic cystectomy for endometriomas. *Fertil Steril* 2006; 85: 1730-1735.
20. Tsoumpou I, Kyrgiou M, Gelbaya TA, Nardo LG. The effect of surgical treatment for endometrioma on in vitro fertilization outcomes: a systematic review and meta-analysis. *Fertil Steril* 2009; 92: 75-87.
21. Royal College of Obstetricians and Gynaecologists. The investigation and management of endometriosis. London: RCOG; 2006. Green-top Guideline No.24.
22. Kennedy S, Bergqvist A, Chapron C, D'Hooghe T, Dunselman G, Greb R, et al. ESHRE guidelines for the diagnosis and treatment of endometriosis. *Hum Reprod* 2005; 20: 2698-2704.
23. de Repetición A. In: Matorras R, Hernández J (eds): Estudio y tratamiento de la pareja estéril: Recomendaciones de la Sociedad Española de Fertilidad, con la colaboración de la Asociación Española para el Estudio de la Biología de la Reproducción, de la Asociación Española de Andrología y de la Sociedad Española de Contracepción. Adalia, Madrid; 2007.
24. Benaglia L, Somigliana E, Iemello R, Colpi E, Nicolosi AE, Ragni G. Endometrioma and oocyte retrieval-induced pelvic abscess: a clinical concern or an exceptional complication? *Fertil Steril* 2008; 89: 1263-1266.
25. Egbase PE, Udo EE, Al-Sharhan M, Grudzinskas JG. Prophylactic antibiotics and endocervical microbial inoculation of the endometrium at embryo transfer. *Lancet* 1999; 354: 651-652.
26. Weinreb EB, Cholst IN, Ledger WJ, Danis RB, Rosenwaks Z. Should all oocyte donors receive prophylactic antibiotics for retrieval? *Fertil Steril* 2010; 94: 2935-2937.
27. Van Os HC, Roozenburg BJ, Janssen-Caspers HAB, Leerentveld RA, Scholtes MCW, Zedilmaker GH. Vaginal disinfection with povidone-iodine and the outcome of in-vitro fertilization. *Hum Reprod* 1992; 7: 349-350.
28. Hannoun A, Awwad J, Zreit T, Ghaziri G, Abu-Musa A. Effect of betadine vaginal preparation during oocyte aspiration in in-vitro fertilization cycles on pregnancy outcome. *Gynecol Obstet Invest* 2008; 66: 274-278.