

# The Role of Immune System in Idiopathic Anterior Uveitis

Mansour Rahimi, Morteza Najafi

Department of Ophthalmology, Shiraz University of Medical Sciences, Shiraz, Iran

## ABSTRACT

**Background:** Idiopathic anterior uveitis is an anterior segment inflammation in which a detailed medical history, general and ocular physical examination is not associated with any defined clinical syndrome. Alterations in immune system parameters have been reported in patients with idiopathic posterior uveitis; however no data on the role of immune system in idiopathic anterior uveitis has yet been reported. In this study the immune system function in patients with idiopathic anterior uveitis was evaluated. **Objective:** To evaluate the immune system function in patients with idiopathic non-infectious anterior uveitis. **Methods:** 51 patients with anterior uveitis, 32 women (62.7%) and 19 men (37.3%), participated in this study. Intensity of intraocular inflammation was scored according to standard uveitis grading system. In all cases, serum levels of immunoglobulins A, G, M and E, C3 and C4 complement components, and autoantibodies against ds-DNA and ACLA, were measured using ELISA method. **Results:** 49 patients out of 51 (96%) showed altered serum levels of immunological parameters, compared with normal values. Changes in serum immunoglobulin concentration were present in 44 patients, with increased IgA levels being the most common. Serum values of C3 and C4 complement proteins were also increased in 29 subjects. ds-DNA autoantibody was positive in 15 and equivocal in 19 cases. ACLA was positive and equivocal in 3 and 9 patients, respectively. **Conclusion:** Immune abnormalities found in serum of 49 patients with idiopathic anterior uveitis may play a role in the pathogenesis of this disorder.

**Keywords:** Idiopathic Anterior Uveitis; IgG, IgA, IgE, IgM, C3, C4

\*Corresponding author: Dr. Mansour Rahimi, Ophthalmology Research Center, Shiraz University of Medical Sciences, Shiraz, Iran. Tel/Fax: (+) 98 711 6279373, P.O. Box: 71345 -1788, e-mail: [mrahimi@sums.ac.ir](mailto:mrahimi@sums.ac.ir)

## INTRODUCTION

Uveitis is a general term used to describe the inflammation of the middle vascular tunic of the eye, the uvea (1). The uvea comprises the iris, ciliary body, and the choroid. In practice, the term uveitis is often applied to any intraocular inflammation, even if the inflammation is not predominantly in the uvea. Many classifications have been proposed for uveitis. The International Uveitis Study Group (IUSG) has recommended that each episode of uveitis be evaluated and characterized regarding to its onset, duration, activity, and pattern (2). Uveitis can also be divided anatomically into anterior, intermediate, posterior, and panuveitis. Anterior uveitis includes iritis and iridocyclitis. The diagnosis and treatment of uveitis remains a significant challenge for ophthalmologists, especially those who work in the field of vitreoretinal diseases. Over the last decade, there has been tremendous progress in understanding the basis of intraocular inflammations, especially in the basic sciences fields (3). Idiopathic anterior uveitis is a form of anterior segment inflammation in which a through medical history and general and ocular physical examination, is not associated with any defined clinical syndrome. It has been reported that idiopathic posterior uveitis causes distinct immune responses (4). However, no study has been performed to evaluate the immunological parameter changes in patients with idiopathic anterior uveitis. Hence, we made an attempt to study the role of immune system in patients with idiopathic anterior uveitis.

## SUBJECTS AND METHODS

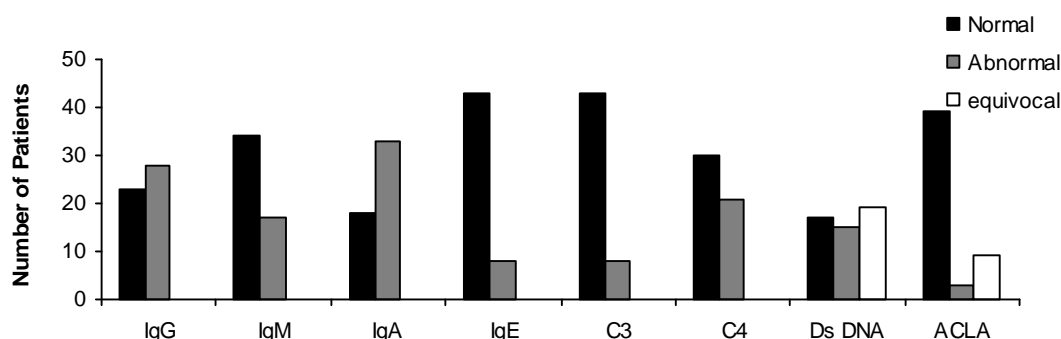
A cross-sectional study was performed by enrolling patients referred to the uveitis clinic at Khalili Hospital, Shiraz University of Medical Sciences, Shiraz, Iran. Fifty one patients compatible with the term of idiopathic anterior uveitis were participated in this study.

A detailed history was taken and review of systems was performed. Best-corrected visual acuity, age, sex, duration of disease, intraocular pressure, afferent papillary defect, and detailed slit lamp and fundus findings were determined. In all cases, selected parameters of immune system activity in serum including immunoglobulin A, G, M and E, and complement proteins C3 and C4 (Baharafshan, Iran) were measured by Nephelometry method. ds-DNA and ACLA autoantibodies were also evaluated by ELISA (IBL-Germany).

## RESULTS

Among 51 patients with idiopathic anterior uveitis, 32 were women (62.7%) and 19 were men (37.3%), with age range of 7 to 72 years (mean $\pm$  SD: 39.56 $\pm$ 15.56). The duration of disease was 2 to 180 months (mean $\pm$  SD: 49.05 $\pm$ 51.94). Forty (78.4%) patients had a positive history of disease recurrence.

Forty nine out of 51 patients had a distinguished change in the level of immune system parameters compared with normal values instructed by the kit manufacturer (Fig1). Rise in serum immunoglobulin values was detected in 44 patients: IgA in 33 cases, IgG in 28 cases, IgM in 17 cases, and IgE in 8 cases.



**Figure 1.** Results of lab data in patient with Idiopathic Anterior Uveitis

In 26 cases increased level of C3 and C4 complement components was present. C3 was increased in 8 cases and C4 in 21. ds-DNA autoantibody was positive in 15 cases and equivocal in 19. ACLA was positive and equivocal in 3 and 9 patients, respectively.

## DISCUSSION

Alterations in immune system in patients with active retinal vasculitis and posterior uveitis have previously been studied (4-11). Our study was the first to evaluate the role of immune system in patients with idiopathic anterior uveitis. In a study conducted by Kubicka-Trzaska on patients with idiopathic posterior uveitis, 28 of 50 patients had immunoglobulin abnormalities, with a rise in IgG titers being the most common (4). However, in our study the most common finding was the elevation in the serum IgA levels, followed by IgG, IgM and IgE.

In the present study 26 cases (50.8%) had elevated levels of complement system proteins versus 68 % of the patients with posterior uveitis in other studies (4). Therefore, abnormal serum complement levels are more common in patients with idiopathic posterior uveitis than those with idiopathic anterior uveitis.

In our study, ds-DNA was positive in 15 cases and equivocal in 19 other. ACLA was positive and equivocal in 3 and 9 patients, respectively. In the study on patients with idiopathic posterior uveitis, neither ANCA nor ACA were detectable.

According to literature, a thorough medical history and an ocular and general physical examination in almost 50% of patients with anterior segment inflammation is not associated with any other defined clinical syndromes (3). Many of the conditions initially diagnosed as idiopathic anterior uveitis are later found to be part of a specific disorder. Importantly, one should rule out Masquerade syndromes that present with an anterior uveitis. These syndromes comprise a group of disorders that present with intraocular inflammation and are often misdiagnosed as chronic idiopathic uveitis. Different conditions, such as intraocular foreign bodies, malignancies including leukemia and lymphoma, and pigment dispersion syndrome, can be misdiagnosed as an idiopathic anterior uveitis. Rifabutin has been associated with a hypopyon uveitis, and a number of glaucoma medications have been associated with anterior uveitis. Nevertheless, a specific etiology for anterior uveitis can not be determined in many patients. It has been hypothesized that these patients may have a change in immune responsiveness that may explain the development of anterior segment inflammation.

Patients with a history of acute anterior uveitis but with no signs of ocular inflammation at the time of diagnosis showed a high innate immune responsiveness compared with the control subjects (13). In a whole blood culture assay, levels of tumor necrosis factor- $\alpha$  and C-reactive protein were significantly higher in patients with a history of anterior uveitis compared with the control subjects.

In conclusion, autoimmunity and immune complex mediated hypersensitivity reactions may be involved in the formation and development of intraocular inflammation in certain cases of idiopathic anterior uveitis.

## ACKNOWLEDGEMENTS

This work was financially supported by a grant from Shiraz University of Medical Sciences, grant No: 82-1733, and in part by Shiraz Institute for Cancer Research.

## REFERENCES

1. Tasman W, Jaeger EA. Duane's clinical ophthalmology. Philadelphia; Lippincott; 2001
2. Bloch-Michel E NR. International Uveitis Study Group recommendations for the evaluation of intraocular inflammatory disease. *Am J Ophthalmol*. 1987;103:234.
3. Nussenblatt RB, Whitcup SM. Uveitis: Fundamentals and clinical practice. 3rd ed. Philadelphia: Mosby; 2005.
4. Kubicka-Trzaska A. Immunologic disturbances in patients with idiopathic posterior uveitis. *Klin Oczna*. 2000;102:253-8.
5. Wakefield D, Easter J, Penny R. Immunological abnormalities in patients with untreated retinal vasculitis. *Br J Ophthalmol*. 1986;70:260-5.
6. Jobin D, Thillaye B, de Kozak Y, Sainte-Laudy J, Faure JP, Le Hoang P. Severe retinohoroidopathy: variations of humoral and cellular immunity to S-antigen in a longitudinal study. *Curr Eye Res*. 1990;9:91-6.
7. Dick AD, Cheng YF, Purdie AT, Liversidge J, Forrester JV. Immunocytochemical analysis of blood lymphocytes in uveitis. *Eye*. 1992;6:643-7.
8. Sainte-Laudy J, Jobin D, Thillaye B, de Kozak Y, Faure JP, Le Hoang P. Diagnostic and predictive importance of the blast transformation test and basophil activation test in retinal vasculitis. *Allerg Immunol (Paris)*. 1993;25:103-5.
9. Kubicka-Trzaska A. Serum antiretinal antibodies titres in patients with endogenous posterior uveitis in 12 months follow-up period. *Klin Oczna*. 2002;104:226-30.
10. Kubicka-Trzaska A. Antiretinal antibodies (ARA) in patients with endogenous posterior uveitis in indirect immunofluorescence test. *Klin Oczna*. 2004;106:45-9.
11. Torun N, Callizo J, Orlic N, Scherer M, Hartmann C, Pleyer U. Serum cytokine receptor levels in noninfectious uveitis. *Ophthalmic Res*. 2005;37:112-6.
12. Wakefield D, Dunlop I, McCluskey PJ, Penny R. Uveitis: aetiology and disease associations in an Australian population. *Aust N Z J Ophthalmol*. 1986;14:181-7.
13. Huhtinen M, Repo H, Laasila K, Jansson SE, Kautiainen H, Karma A, Leirisalo-Repo M. Systemic inflammation and innate immune response in patients with previous anterior uveitis. *Br J Ophthalmol*. 2002;86:412-7.