

Congenital Esophageal Stenosis in a Patient with Turner's Syndrome; A Case Report

Hassan Saadatnia*, Ali Moatamedi

Department of Medicine, Ghaem hospital, Mashad University of Medical Sciences, Mashad, Iran

Abstract

A fifteen-year-old Torkaman girl with Turner's mosaic karyotype is presented. She has had congenital esophageal stenosis with severe dysphagia since birth and iron deficiency anemia in addition to other classical features of the syndrome. According to author's knowledge this is the first report of a new congenital structural gastrointestinal anomaly with this disease. *Govaresh* 2003; 8: 184-6

Keywords: Turner's syndrome, Congenital esophageal stenosis

INTRODUCTION

Since the original description of Henry Turner in 1938 of seven cases of rather uniform appearance; i.e., women with short stature, sexual infantilism, webbing of neck and cubitus valgus which bears his name⁽¹⁾, it has been recognized that there are multiplicity of findings in Turner's syndrome and its mosaic karyotypes⁽²⁾. A number of reports have called attention to gastrointestinal (GI) disorders in these patients including duodenal atresia, delayed gastric emptying and esophagotracheal fistula⁽³⁾; GI bleeding often of massive proportion due to intestinal telangiectasias and hemangiomatoses or dilated veins and venules has been reported⁽⁴⁾. A second cause of GI bleeding and dysfunction appears to be an increased incidence of inflammatory bowel disease⁽⁵⁾. The goal of this communication is to report congenital esophageal stenosis (CES) in a patient with Turner's syndrome.

CASE REPORT

A 15-year-old Torkaman girl was admitted to the hospital for evaluation of infantilism and dysphagia. The history dated back to birth when

she had persistent regurgitation of milk and later on she couldn't swallow solids at all. Her feeding continued with milk and liquids, meanwhile she was found to be underdeveloped, undernourished with visual and hearing impairment. Aside from short stature, she seemed to progress satisfactorily but she had no menses or evidence of puberty at the age of 15 years. During the past several years she was pale and had dyspnea on exertion. Physical examination revealed a thin pale immature appearing female (Fig 1).

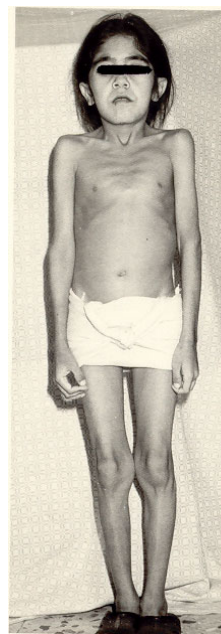


Figure 1: Patient

*Corresponding author: Hassan Saadatnia MD, Department of Medicine, Ghaem hospital, Ahmadabad Ave., Mashad, Iran.
Tel: +98 511 8425221, Fax: +98 511 8409612
E-mail: h_saadatnia@mums.ac.ir

Vital signs were as follows: BP: 100/65, PR: 90, RR: 18, T: 37.2. Her height was 145 cm, span 148 cm, head to symphysis pubis 74 cm, and symphysis to heel 71 cm. Her neck was short with no pterygium; posterior hair line was low; ears were prominent. Dental development was defective. She had a shield-like chest with no breast tissue and pre-pubertal nipples. An ejection systolic murmur II/VI was heard in left lower sternal border. Abdomen was normal; pubic and axillary hair was scant. External genitalia were infantile. Pelvic examination was hampered by a virginal hymenal ring. Rectal examination showed a small uterus without palpable ovaries. Neurologically she had horizontal nystagmus and bilateral optic atrophy with retinal degeneration. The hemoglobin level was 9.3 g/100 ml. Hematocrit was 27% with evidence of iron deficiency anemia (serum iron 20 µg percent, TIBC 420 µg percent, ferritin 12 µg/lit, absence of iron on bone marrow aspiration), white blood count was 6100 with a normal differential count. Platelets count was 282000/mm³. Stool was guaiac negative, thyroid and liver function tests, BUN, creatinine, fasting blood glucose, cholesterol, triglyceride, CPK, P, Ca, Na, K were all normal, urinalysis was normal. LH, FSH and estradiol were in the range of prepuberty. Urinary 17-ketosteroid was 4 mg/24 hours (normal 5-15 mg/24 hours). Occasional Bar bodies were seen in buccal smear. Chromosomal studies showed mosaic (45XO/46XX) Turner's syndrome. An audiogram showed sensorineural hearing impairment. Chest X-ray and abdominal ultrasound were normal except small prepubertal uterine and streak ovaries. Echocardiography was normal. An upper GI series showed a funnel shape long tapering esophageal stenosis in upper esophagus with dilation above. GI series was otherwise normal (Fig 2). Small bowel series and barium enema were normal. A skeletal survey showed incomplete fusion of iliac crests. An upper GI endoscopy with pediatric gastroscope revealed a funnel shape concentric stenosis in upper esophagus with irritated mucosa above it, tube could not be passed through the stricture; biopsy above and below the stricture showed

nonspecific esophagitis. Esophageal manometry was not available. Colonoscopy was normal. She was treated with conjugated estrogen, growth hormone, oral ferrous sulfate, vitamin supplements and repeated esophageal dilatation with marked improvement.

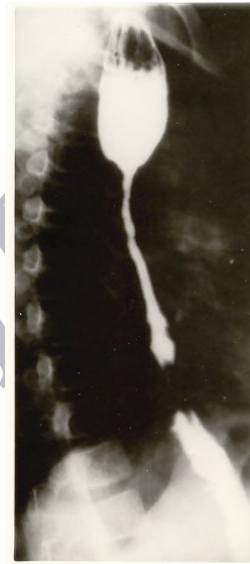


Figure 2: GI series of patient

DISCUSSION

Turner's syndrome is the most common sex chromosome abnormality in female affecting an estimated 3 percent of all females conceived. However the frequency among live-borne female is 1 in 2000 to 1 in 5000 and it's been estimated that only 1 in 1000 embryos with a 45, X karyotype survives to term⁽⁶⁾. This patient represents a typical case of Turner's syndrome. Classical findings of short stature, absence of secondary sex characteristics, primary amenorrhea and cytogenetic studies confirm the diagnosis of Turner's mosaic pattern. Mosaic karyotype is the second most common variant of Turner's syndrome⁽⁷⁾. In addition to classical features of disease numerous other anomalies has been reported with it. Nystagmus and sensorineural hearing loss as this patient had, has been reported previously⁽²⁾.

Congenital esophageal stenosis (CES) is also rare (1 per 25000 live birth) which usually

presents at birth or infancy⁽⁸⁾. There are basically three types of CES: esophageal web, esophageal muscular ring and fibromuscular stenosis⁽⁹⁾. Presence of persistent regurgitation since birth and later on solid dysphagia denotes to congenital nature of this finding and radiological appearance of a long tapering stenosis is compatible with fibromuscular variant of CES. Although the association of Turner's syndrome with CES may or may not be etiologically related, to author's knowledge this is the first report in English literature. Iron deficiency anemia in this case also merits comment. GI bleeding, often severe, occurs in patients with Turner's syndrome with an incidence of about seven percent⁽⁴⁾. Bleeding has been ascribed to intestinal telangiectasia and

hemangiomas. These vascular abnormalities are usually seen only at laparotomy which shows telangiectasia and or hemangiomas of small and large bowel serosa. Colonoscopy may show prominent mucosal vasculature which was not present in our patient. Another source of GI bleeding is an increased incidence of inflammatory bowel disease⁽¹⁰⁾. Although entire GI tract could not be studied in our patient, her iron deficiency anemia appears to be due to poor nutrition and / or esophageal mucosal inflammation around the stricture.

Acknowledgement: We are deeply indebted to Dr. Hassanzadeh Nazarabadi for doing cytogenetic studies and to our nurses at GI endoscopy unit.

References

1. Wilson JD, Griffin JE. Disorders of sexual differentiation. In: Braunwald E, Fauci AS, Kasper DL *et al.*, editors. *Harrison's Principles of Internal Medicine*. 15th ed. New York: McGraw Hill; 2001: p. 2172-84.
2. Saenger P. Current concept: Turner's syndrome. *N Engl J Med* 1996; **335**: 1749-54.
3. Saenger P. Current status of diagnosis and therapeutic intervention in Turner's syndrome. *J Clin Endocrinol Metab* 1993; **77**: 297-301.
4. Kenneth M, Rosen D, Siorta K. Gastrointestinal bleeding in Turner's syndrome. *Ann Intern Med* 1967; **67**: 145-50.
5. Lippe BM. Turner's syndrome. In: Sperling M, editor. *Pediatric endocrinology*. 3rd edition. Philadelphia: W.B Saunders; 1996: 387-421.
6. Cockwell A, MacKenzie M, Jacobs I. A cytogenetic and molecular study of a series of 45,X fetuses and their parents. *J Med Genet* 1999; **28**: 152-5.
7. Held KR, Kerber S, Kaminsky E *et al.* Mosaicism in 45,X Turner's syndrome: does survival in early pregnancy depend on the presence of two sex chromosome. *Hum Genet* 1998; **88**: 288-94.
8. Major PR, McNally DO, Capitan EH *et al.* Congenital esophageal stenosis. *Dig Dis Sci* 1990; **35**: 263-6.
9. Segev DL, Donahoe PK, Dooly DP. Congenital anomalies/Other congenital disorders in children. In: Pearson FG, Cofer JD, Deslauriers J *et al.*, editors. *Esophageal surgery*. Second edition. New York: Churchill Livingstone; 2002: 207-14.
10. Podolsky DN. Inflammatory bowel disease. *N Engl J Med* 2002; **347**: 417-28.