

Non HFE-Related Hemochromatosis; A Case Report from Iran

Amir Hooshang Mohamad Alizadeh¹, Mohsen Masoodi^{1*}, Rahim Aghazadeh²,
Mohamad Javad Ehsani Ardakani¹, Mozhgan Forootan¹, Mohamad Reza Zali²

¹Assistant Professor of Gastroenterology, Research Center for Gastroenterology and Liver Disease,
Shahid Beheshti University of Medical Science, Tehran, Iran

²Professor of Gastroenterology, Research Center for Gastroenterology and Liver Disease,
Shahid Beheshti University of Medical Science, Tehran, Iran

ABSTRACT

Hemochromatosis, especially with cardiac and liver problem, is rare in Iran. We report a young female with pulmonary hypertension and abnormal liver function tests due to non HFE- related hemochromatosis. *Govaresh* 2004; 9: 66-9

Keywords: Hemochromatosis, Pulmonary hypertension, Iran

INTRODUCTION

Hereditary hemochromatosis (HH) (also called genetic hemochromatosis) is the term used for the inherited disease of iron overload, that is *HFE*¹-related and that is characterized by an inappropriately elevated rate of intestinal iron absorption. Trousseau was the first to describe a case of hemochromatosis in the French pathology literature in 1865⁽¹⁾. Several population surveys have shown that the frequency of the homozygous disease ranges from 1 in 100 to 1 in 400 in white populations in several areas of the world⁽²⁾.

1. The gene involved in the most common form of hemochromatosis is termed HFE.

*Corresponding author: Mohsen Masoodi MD, Research Center for Gastroenterology and Liver Disease, Shahid Beheshti University of Medical Sciences, Tehran, Iran.
Tel: +98 21 2418871
Fax: +98 21 2402639
E-mail: masoodi47@yahoo.com

In 1996, the gene for HH, called *HFE*, was identified, thereby allowing genetic testing for the two major mutations (C282Y, H63D) that are responsible for HH⁽³⁾. Subsequently, numerous clinical and pathophysiologic studies have led to improved diagnosis, better family screening, and new insights into normal and abnormal iron homeostasis. Mutations in other genes, currently unidentified, are responsible for non-HFE associated hemochromatosis. But hemochromatosis seems to be a rare condition in Iran, so a few case reports about the subject exist in our country.

CASE REPORT

A 35-year-old woman presented with pallor, dyspnea and hypermenorrhea from many years ago. There was no history of jaundice, pruritus, smoking or alcohol use. The patient had been followed by a cardiologist with impression of pulmonary hypertension (Echocardiography: mild TR, mild MR, mean pulmonary artery pressure; 32 mmHg, EF; 70%, thickness of right

ventricle; 6 mm and mild dilated right ventricle) and had been treated with warfarin and nifedipine without significant improvement. She had normal

Table 1: Laboratory data

WBC: 5800/mL	Ca: 9 mg/dL
Hb: 9.2 g/dL	P: 4 mg/dL
MCV: 78 fl	Cholesterol: 165 mg/dL
Plat: 132000 / μ L	TG: 190 mg/dL
ESR: 5	BUN: 18 mg/dL
AST: 49 (0-35) U/L	Na: 143 meq/L
ALT: 112 (0-35) U/L	K: 4.5 meq/L
Alkaline phosphatase: 160 U/L	FBS: 105 mg/dL
Total protein: 7.8 g/dL	U/A: normal
Albumin: 4 g/dL	HBsAg: negative
Bilirubin: 0.6 mg/dL	HCV Ab: negative
PT: 15.5 (12) Sec with warfarin	Hb electrophoresis: normal
PT: 12 (12) Sec without warfarin	CXR: normal
PTT: 33 Sec	Abdominal sonography: normal
IRON: 192 (50-150) μ g/dL	Thyroid function tests: normal
TIBC: 223 (250-370) μ g/dL	ANA: negative
Transferrin saturation: 86% (20-45%)	Anti-smooth muscle antibody: negative
Ferritin: 3255 (10-200) μ g/L	Coombs test: negative
Stool OB: negative	Body Mass Index: 26 kg/m ²

physical exam except loud P₂. Pulmonary function test and arterial blood gas were normal. Patient had no hemolysis and no source of blood loss except vaginal bleeding. Recent evaluation of patient problems showed abnormal liver function test and iron saturation (Table 1).

Thereafter she was referred for liver biopsy and genetic study. Liver biopsy was reported as periportal and portal inflammation, no fibrosis, and diffuse significant deposition of golden

yellow iron granules in cytoplasm of hepatocyte, +++Prussian blue stain compatible with hemochromatosis (Figure 1) and liver iron concentration was 19 times (28000 μ g/g dry weight) above normal range. Genetic study for C282Y and H63D by genomic DNA extraction and then RFLP method was negative. Evaluation for other cases of liver disease also was negative. Patient treated with subcutaneous desferal, then after 3 months liver function test [AST: 32 (0-35) U/L, ALT: 42 (0-35)U/L] was improved. Also, hypermenorrhea treated by oral contraceptives, then after 6 months anemia was improved and serum ferritin decreased.

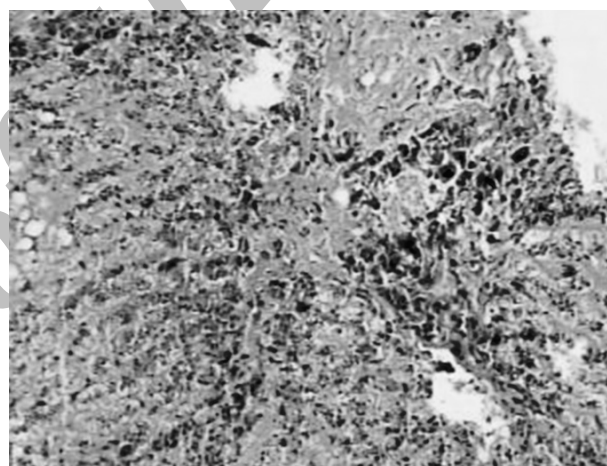


Figure 1: Prussian blue stain of liver biopsy, periportal and portal inflammation, no fibrosis, and diffuse significant deposition of golden yellow iron granules in cytoplasm of hepatocyte, +++Prussian blue stain.

DISCUSSION

Many patients with HH come to medical attention without any symptoms or physical findings. They are identified as homozygous relatives of probands who are detected by family screening studies or by serum iron studies performed as part of a routine screening blood chemistry panel^(4,5). Nonetheless, it is important to appreciate the typical clinical manifestations that may present in patients with symptomatic disease. Most patients with symptomatic HH are 40 to 50 years of age at the time of diagnosis. Although the defective gene is distributed

equally between men and women, most clinical series have identified more men than women, with ratios ranging from 8:1 to 2:1⁽⁶⁾. Thus, the frequency of HH in females is often underestimated when based solely on phenotypic expression, most likely because of iron loss from normal menses and childbirth⁽⁶⁾.

All patients with HH have increased hepatic iron stores, but the degree of iron loading is often not high enough to cause liver damage. In the late 1960s, cirrhosis was found in over 50% of patients with a diagnosis of HH^(6,7); more recent studies since 1985 have identified cirrhosis in only 5% to 10% of patients, because when HH is diagnosed and treated before the development of fibrosis or cirrhosis, long-term hepatic complications do not occur^(4,5). Two recent population screening studies from Western Australia⁽⁸⁾ and San Diego⁽⁹⁾ identified 59 patients with HH, in whom only 1 had cirrhosis. Extrahepatic clinical manifestations of HH depends on the degree of iron deposition in organs other than liver. Excess iron storage eventually produces pituitary, pancreatic, cardiac, and liver dysfunction and death may result from cardiac arrhythmias, congestive heart failure, and/or hepatic failure or cancer⁽¹⁰⁾. Cardiac manifestations are now rare because patients are diagnosed earlier than in the past. Cardiomyopathy, atrial and ventricular dysrhythmias, and congestive heart failure can occur⁽¹¹⁾.

Our patient is an interesting case, as she first presented with cardiopulmonary problem and

younger age than usual symptomatic patients, but whether pulmonary hypertension of this patient is related to pulmonary or cardiac problems of hemochromatosis or other cause is not known, because the patient had no pulmonary angiography and cardiac catheterization and there is no report of pulmonary hypertension without cardiac involvement in the literature. Also common genetic mutation in the patient was negative. Although the majority of HH cases are associated with an HFE gene mutation in the western world and in the northern Europe, there are families with familial iron overload disorder in whom neither the C282Y nor the H63D mutation was found. In addition, no genetic abnormality on chromosome 6p was identified in these latter families⁽¹²⁾. In four series; roughly 5 to 7 percent of patients appeared to have neither the C282Y mutation nor the H63D mutation^(3,13-15). These patients may have other mutations within the HFE gene or other gene such as 1q in juvenile hemochromatosis⁽¹⁶⁻¹⁸⁾. Our patient also may have other unusual mutations.

It should always be borne in minds that although relatively rare, hemochromatosis should be considered in differential diagnosis of liver and heart problems.

Acknowledgement: We would like to thank Dr. Samiee for pathology report and Dr. Mohammad Reza Agah for genetic study in Research Center for Gastroenterology and Liver Disease.

References

1. Bacon BR, Joseph H, Sheldon and hereditary hemochromatosis: Historical highlights. *J Lab Clin Med* 1989; **113**: 761-2.
2. Bacon BR, Powell LW, Adams PC *et al.* Molecular medicine and hemochromatosis: at the crossroads. *Gastroenterology* 1999; **116**: 193-207.
3. Feder JN, Gnirke A, Thomas W *et al.* A novel MHC class I-like gene is mutated in patients with hereditary haemochromatosis. *Nat Genet* 1996; **13**: 339-408.
4. Adams PC, Kertesz AE, Valberg LS. Clinical presentation of hemochromatosis: a changing scene. *Am J Med* 1991; **90**: 445-9.
5. Bacon BR, Sadiq SA. Hereditary hemochromatosis: presentation and diagnosis in the 1990s. *Am J Gastroenterol* 1997; **92**: 784-9.
6. Edwards CQ, Cartwright GE, Skolnick MH *et al.* Homozygosity for hemochromatosis: clinical manifestations. *Ann Intern Med* 1980; **93**: 519-25.
7. Niederau C, Fischer R, Sonnenberg A *et al.* Survival and causes of death in cirrhotic and noncirrhotic patients with primary hemochromatosis. *N Engl J Med* 1985; **313**: 1256-62.

8. Olynyk JK, Cullen DJ, Aquilia S *et al.* A population-based study of the clinical expression of the hemochromatosis gene. *N Engl J Med* 1999; **341**: 718-24.
9. Beutler E, Felitti V, Gelbart T *et al.* The effect of HFE genotypes on measurements of iron overload in patients attending a health appraisal clinic. *Ann Intern Med* 2000; **133**: 329 -37.
10. Walker EM Jr, Wolfe MD, Norton ML *et al.* Hereditary hemochromatosis. *Ann Clin Lab Sci* 1998; **28**:300-12.
11. Olson LJ, Edwards WD, Holmes DR *et al.* Endomyocardial biopsy in hemochromatosis: clinicopathologic correlates in six cases. *J Am Coll Cardiol* 1989; **13**: 116-20.
12. Bacon BR, Olynyk JK, Brunt EM *et al.* HFE genotype in patients with hemochromatosis and other liver diseases. *Ann Intern Med* 1999; **130**: 953-62.
13. Beutler E, Gelbart T, West C *et al.* Mutation analysis in hereditary hemochromatosis. *Blood Cells Mol Dis* 1996; **22**: 187-94.
14. Mura C, Ragueneas O, Ferec C. HFE mutations analysis in 711 hemochromatosis probands: evidence for S65C implication in mild form of hemochromatosis. *Blood* 1999; **93**: 2502-5.
15. Hanson EH, Imperatore G, Burke W. HFE gene and hereditary hemochromatosis: a HuGE review. *Human Genome Epidemiology. Am J Epidemiol* 2001; **154**: 193-206.
16. Pietrangelo A, Montosi G, Totaro A *et al.* Hereditary hemochromatosis in adults without pathogenic mutations in the hemochromatosis gene. *N Engl J Med* 1999; **341**: 725-32.
17. Piperno A, Arosio C, Fossati L *et al.* Two novel nonsense mutations of HFE gene in five unrelated Italian patients with hemochromatosis. *Gastroenterology* 2000; **119**: 441-5.
18. Papanikolaou G, Samuels ME, Ludwig EH *et al.* Mutations in HFE2 cause iron overload in chromosome 1q-linked juvenile hemochromatosis. *Nat Genet* 2004; **36**: 77-82.

Archive of SID