

## Pancreatic Tail Hydatid Cyst as a Rare Cause for Severe Acute Pancreatitis: A Case Report

Mahmud Baghbanian<sup>1</sup>, Hasan Salmanroghani<sup>1</sup>, Saeed Karegar<sup>2</sup>, Fariba Binesh<sup>3</sup>, Ali Baghbanian<sup>4</sup>

<sup>1</sup> Department of gastroenterology, Shaheed Sadoughi University of Medical Sciences, Yazd, Iran

<sup>2</sup> Department of General surgery, Shaheed Sadoughi University of Medical Science, Yazd, Iran

<sup>3</sup> Department of pathology, Shaheed Sadoughi University of Medical Science, Yazd, Iran

<sup>4</sup> Department of psychiatry, Tehran University of Medical Science, Tehran, Iran

### ABSTRACT

Iran is an endemic region for hydatid disease. Primary pancreatic hydatosis is a rare event; severe acute pancreatitis related to pancreatic hydatid cyst is extremely rare.

We present the case of a patient with severe acute pancreatitis and hydatosis of the pancreas without liver or lung involvement. All etiologies for acute pancreatitis were excluded. The patient underwent a distal pancreatectomy which led to the diagnosis of pancreatic hydatosis.

Since hydatid disease is endemic in some regions, it should be considered as one of the underlying etiologies for inflammation or infection of the pancreas (acute pancreatitis).

**Keywords:** *Echinococcosis*; Pancreas; Acute pancreatitis

*please cite this paper as:*

Baghbanian M, Salmanroghani H, Karegar S, Binesh F, Baghbanian A. Pancreatic Tail Hydatid Cyst as a Rare Cause for Severe Acute Pancreatitis: A Case Report. *Govaresh* 2013;18:

### INTRODUCTION

Hydatid cyst disease is a common parasitic infection of humans and animals in certain geographical regions. Consumption of *Echinococcus granulosus* eggs in vegetables contaminated with dog feces is a primary route for human infection. Hydatid cysts may be found in almost any site of the body but liver involvement is the most common manifestation

(0%)(1). Hydatosis of other organs such as the brain, heart, kidney, and pancreas is rare. Primary pancreatic involvement (without liver or lung disease) is found in less than 0.2% of cases of hydatidosis(2) and less than 1% in those countries where the disease is endemic(3). Pancreatic infestation can occur by the hematological route or by peripancreatic lymphatic invasion(4).

Preoperative diagnosis of a pancreatic hydatid cyst is difficult due to its rarity. Computed tomography (CT) scan is helpful for identifying presence of multiloculation, curvilinear calcification or daughter cysts. However, final diagnosis may be made only by surgical exploration and histopathologic examination. Clinical presentation of pancreatic hydatid varies with size and the anatomic location of the disease. A cyst located in the pancreatic head can cause obstructive jaundice(5) acute(6) or chronic pancreatitis(7). Cysts located in the pancreas body can be symptomless or an abdominal mass may be present(8). Lesions on

### Corresponding author:

Mahmud Baghbanian MD

Gastrointestinal Endoscopy and Haemodialysis

Sadighi Hospital, Yazd, Iran

Tel: +935 822000

Fax +935 822400

E-mail: [m.baghbanian133@gmail.com](mailto:m.baghbanian133@gmail.com)

Received 27 Nov. 2012

Edited 19 Feb 2013

Accepted 20 Feb 2013

the tail can also present with portal hypertension (9) or acute pancreatitis, as in our case.

## CASE REPORT

A 46-year-old man who was born and resided in central Iran was admitted to the hospital with complaints of severe constant epigastric pain, bilious vomiting and fever for 24 hours duration. On examination, the patient was distressed, with a temperature of 39°C, heart rate of 115 beats/minute and blood pressure of 100/80 mm/Hg. He was dehydrated and mildly icteric. The patient had generalized abdominal distention and mild tenderness without rebound in the upper abdominal area. There was no discoloration around the umbilicus or flanks. Chest, central nervous and musculoskeletal systems were normal on examination. Laboratory analyses revealed leukocytosis and increased serum amylase and lipase levels (Table 1).

Trans-abdominal ultrasound on the first day revealed mild enlargement of the pancreas without any stones, sludge or dilatation in the biliary and pancreatic

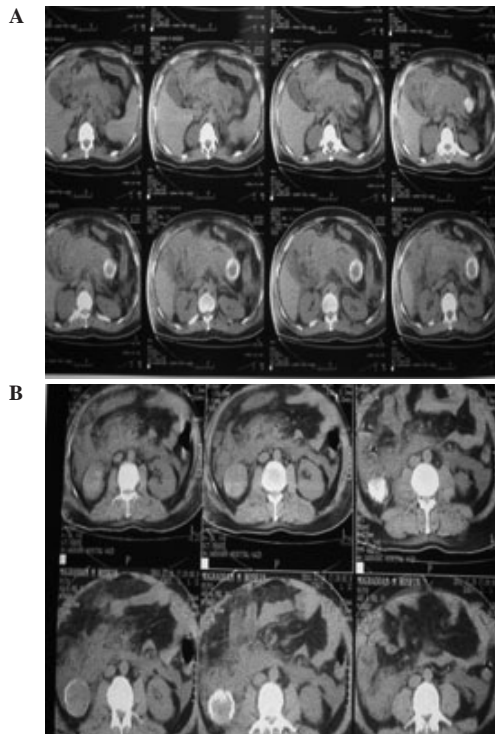
ducts. Chest radiology was normal, however plain abdominal X-ray revealed two areas of calcification in the abdomen. The patient was diagnosed as a case of acute pancreatitis and prescribed normal saline 250 milliliter per hour and imipenem.

The next day, the patient's abdominal pain diminished however his creatinine level increased to 2.5 mg/dl and urinary output decreased to 300ml/24h. The patient underwent an abdominal CT scan without contrast that revealed diffuse enlargement of the pancreas with approximately 50% necrosis and a 6×5 cm heterogeneous mass with thick peripheral calcification in the pancreatic tail. Ascites and bilateral plural effusion, and a 7×6 cm hypo-dense mass with peripheral thick calcification in the right kidney were other findings of the CT scan (Figure 1).

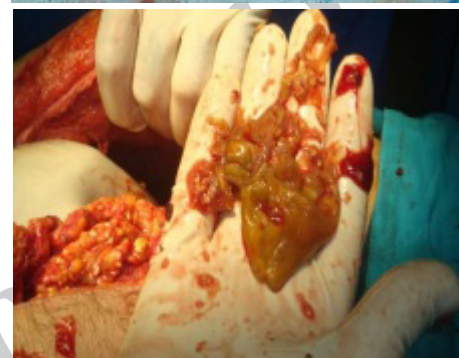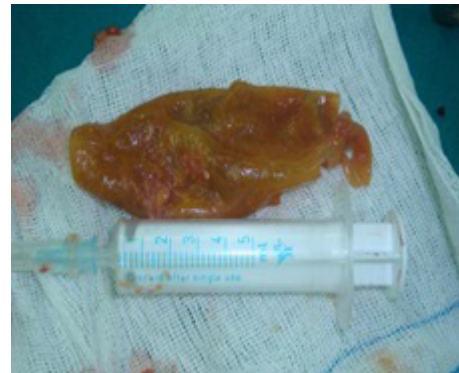The patient was admitted to the Intensive Care Unit on day three of his hospitalization. Fluid therapy continued because of the central vein pressure and urinary output. At this time, serum AST, ALT, ALP, and bilirubin levels normalized however fever (39-40°C) and nausea continued. On day four, the patient

**Table 1:** Patient's laboratory results on days 1, 3, and 6 after hospitalization.

Parameter	Results			Normal value
	Day 1	Day 3	Day 6	
White blood cell (mm <sup>3</sup> )	1060	10	100	3.0-10.0 <sup>3</sup>
Hemoglobin (g/dl)	14	14	11	13.3-16
Platelets (mm <sup>3</sup> )	385 × 10 <sup>3</sup>	9 × 10 <sup>3</sup>	5 × 10 <sup>3</sup>	145-400 <sup>3</sup>
Prothrombin time (s)	12	17	14	12-15
Partial thrombin time (s)	30	4	34	26-39
Aspartate transaminase (unit/L)	24	233	27	4
Alanine transaminase (unit/L)	31	24	32	4
Alkaline phosphatase (unit/L)	12	64	138	33-90
Total bilirubin (mg/dl)	1	2	1.2	0.3-1.3
Direct bilirubin (mg/dl)	0.2	1	0.3	<0.3
Blood culture	Negative	Negative	Negative	Negative
Echinococcus antibody	-	5	-	Negative: <1.1
Amylase (unit/L)	2807	230	4	20-90
Lipase (unit/L)	130	188	83	33
Creatinine (mg/dl)	1.4	4	9	0.6-1.2
Blood urea nitrogen (mg/dl)	12	5	8	20
Fasting blood sugar (mg/dl)	7	186	132	100
Triglycerides (mg/dl)	13	-	-	30-200
Carbohydrate antigen 19-9 (unit/ml)	105	-	-	<37



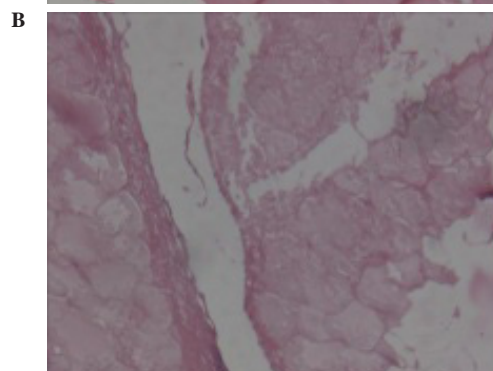
**Fig.1:** CT scan showing enlarged pancreas, necrosis and a 5×6 cm heterogenic mass with thick peripheral calcifications in the pancreatic tail (A). A similar lesion is observed in the right kidney (B).



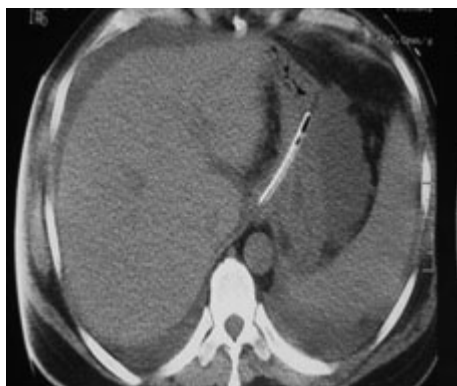**Fig.2:** Inner layer of the pancreatic cyst wall. No viable scolex were noted upon histopathologic examination.

became hypotensive, anuric, confused and tachypneic, and his creatinine increased to 9 mg/dl. Vasopressor, mechanical ventilation and daily hemodialysis were initiated at this time. A fluid tap of his ascites revealed dark fluid with 18000 white blood cells (96% neutrophils), 10000 red blood cells, amylase (54 unit/ml), bilirubin (0.8 mg/dl), protein (3g/dl) and glucose (45 mg/dl). A smear and culture of the ascites sample were negative.

Considering above clinical setting and paraclinic findings, septic shock due to severe necrotizing pancreatitis was suggested and a laparotomy and necrosectomy was performed on day eight. There was approximately 3 L of dark fluid in the abdomen. The tail and necrotic parts of the pancreas were removed during the distal pancreatectomy and necrosectomy. There was a 6×6 cm unilocular firm cystic lesion in the tail of the pancreas that had a thick, hard external wall with a soft, thin inner layer (Figure 2) and semisolid whitish creamy material. There was another mass in the lower pole of the right kidney which was excised as a partial nephrectomy. This mass was a 7×6 cm cystic lesion similar to the pancreatic mass.



**Fig.3:** Microscopic image of the pancreatic hydatid cyst wall (A) and fat necrosis (B).



**Fig.4:** No lesions were visualized in the liver. Note the presence of ascites fluid surrounding the liver.

Following laparotomy, the patient was returned to the ICU where vasopressor, mechanical ventilation, daily hemodialysis and enteral feeding were continued with no improvement in the patient's condition and after 15 days, he died.

Pathologic examination confirmed hydatid disease of both the pancreas and kidney lesions. The semisolid material observed in the pancreatic lesion was fat necrosis (Figure 3).

The pathologist was unable to find a distinct Connection between the pancreatic duct and hydatid cyst.

The presence of ascites fluid surrounding the liver and NG tube in the stomach (Figure 4).

## DISCUSSION

Pancreatic involvement is reported in 0.25%-0.75% of hydatid disease cases(10). Pre-operative diagnosis of pancreatic hydatid cysts is difficult because these cysts may be mistaken for pseudocysts, cystadenocarcinoma, congenital or post-traumatic cysts(11). Endoscopic ultrasound (EUS) is an effective, safe procedure for diagnosing pancreatic lesions, whether malignant or non malignant(12,13). This procedure is useful for further assessment in patients with pancreatic cystic lesions that

are suspicious for hydatosis.

The initial presentation of pancreatic hydatosis in this patient was the finding of severe, acute pancreatitis. Therapeutic management of pancreatic hydatosis is complicated, however in cases with acute pancreatitis it becomes quite problematic.

Hydatid disease of the kidneys or pancreas is rare. Simultaneous hydatosis of both the kidneys and pancreas, particularly in the absence of liver or lung involvement is even rarer. Acute pancreatitis due to a pancreatic tail hydatid cyst is extremely rare.

An interesting finding in our presented case is hydatosis of the pancreas and right kidney, which are unusual locations for a hydatid cyst, without liver or lung involvement.

*Echinococcus granulosus* cysts rarely rupture into the biliary tree or pancreatic duct. So they can produce biliary colic, obstructive jaundice, cholangitis(14), pancreatitis or even bronchobiliary fistula(15).

Although transient increases in AST, ALT, ALP and bilirubin levels in our case might have been evidence of passage of the hydatid cyst material into the pancreatic duct, however histopathologic examination of the surgical specimen did not determine any distinct communication between the wall of the hydatid cyst and the pancreatic duct. Pancreatic duct obstruction due to the pressure effect of the cyst might have been a probable etiology for acute pancreatitis in this patient.

Hydatid disease should be considered as a differential diagnosis for cystic lesions of the pancreas in acute pancreatitis, particularly in geographical areas where the disease is endemic.

## ACKNOWLEDGMENT

This work is supported in part by the Nutrition Research Center and Gastrointestinal and Liver Disease Research Center.

## REFERENCES

1. Eckert J, Deplazes P. Biological, epidemiological, and clinical aspects of echinococcosis, a zoonosis of increasing concern. *Clin Microbiol Rev* 2004;17:107-19.
2. Abi F. Unusual localisation of hydatid cyst. Apropos of 40 Cases. *J Chir (Paris)* 1989;126:307-12.
3. Serhal S, Sebai F, Mestiri S. Hydatid cyst of the pancreas. Apropos of 3 cases. *J Chir (Paris)* 1987;124:542-4.
4. Kayabali I, Gokcora IH, Ormeci N. Surgical treatment of hydatid cysts of the pancreas. *Int Surg* 1991;76:185-8.



5. Sinha AN, Rao AS, Vyas HG. Hydatid cyst in head of pancreas presenting with obstructive Jaundice. *Indian J Gastroenterol* 1997;16:32.
6. Mahir Ozmen M, Munevver Moran. Recurrent Acute Pancreatitis Due to a Hydatid Cyst of the Pancreatic Head: A Case Report and Review of the Literature. *J Pancreas (Online)* 2005; 6:354-8.
7. Regan JK, Brown RD, Marrero JA, Malik P, Rosenberg F, Venu RP. Chronic pancreatitis resulting from primary hydatid disease of the pancreas: a case report and review of the literature. *Gastrointest Endosc* 1999;49:791-3.
8. Yorganci K, Iret D, Sayek I. A case of primary hydatid disease of the pancreas simulating cystic neoplasm. *Pancreas* 2000;21:104-5.
9. Gonzalez EP, Gil-Grande L, del Arbol LR, del Pozo D, Miquel J, Vazquez M, et al. Presinusoidal portal hypertension secondary to portal invasive echinococcosis. *J Clin Gastroenterol* 2002;34:103-4.
10. Brown RA, Millar AIW, Steiner Z, Krige JE, Burkimsher D, Cywes S. Hydarid cyst of the pancreas: a case report in a child. *Eur J Pediatr Surg* 1995;5:121-4.
11. Lemmer ER, Krige JE, Price SK, Girdwood AH. Hydatid cyst in the head of the pancreas with obstructive jaundice. *J Clin Gastroenterol* 1995;20:136-8.
12. Baghbanian M, Shabazkhani B, Ghofrani H, Forutan H, Dariani N, Farahvash M, et al. Efficacy of endoscopic ultrasound guided fine needle aspiration in patients with solid pancreatic neoplasms. *Saudi J Gastroenterol* 2012;18:358-63.
13. Brugge WR, Lauwers GY, Sahani D, Fernandez-del Castillo C, Warshaw AL. Cystic neoplasms of the pancreas. *N Engl J Med* 2004;351:1218-26.
14. Baghbanian M, Shahbazkhani B. Photoclinic. *Arch Iran Med* 2012;15:585-6.
15. Zojaji H, Talaie R, Arjomand-Shabestary A, Zali MR. Endoscopic Treatment of a Bronchobiliary Fistula Due to Complicated Hydatid Cyst After Surgical Intervention: A Case Report. *Govaresh* 2008;13:198-201.