

An Atypical Presentation of Acute Appendicitis: A 77 Years Old Man with Left Lower Quadrant Pain

Hossein Ajdarkosh¹, Sanam Javid Anbardan², Zahra Azizi³, Nasser Ebrahimi Daryani⁴

¹ Assistant Professor, Gastrointestinal and Liver Disease Research Center, Firoozgar Hospital, Iran University of Medical Sciences, Tehran, Iran.

² Researcher, Tehran University of Medical Sciences, Tehran, Iran

³ Researcher, Iran University of Medical Sciences, Tehran, Iran

⁴ Professor, Department of Internal Medicine, Division of Gastroenterology, Imam Khomeini Hospital, Tehran University of Medical Sciences, Tehran, Iran

ABSTRACT

With an occurrence of 7%, appendicitis is one of the most common abdominal emergencies requiring surgery. Since the variation in positions and length of the appendix may produce varying symptoms and signs which mimic other diseases, having knowledge of the variations in the position of the appendix is of significant importance.

Here, we present a 77-year-old man with acute appendicitis presenting with lower abdominal pain, fever, chills, and dysuria. Physical examination revealed tenderness and rebound tenderness in the left lower quadrant more pronounced in the right lower quadrant with leukocytosis on blood tests. Both ultrasonography and abdominopelvic computed tomography scan demonstrated a severe inflammation at paracecal mesenteric fat with extension to para sigmoid portion which was in favor of diverticulitis rather than appendicitis. A 2-week treatment with intravenous antibiotic regimen was initiated for the patient and from the second day of antibiotic therapy, the patient's fever and abdominal pain improved. A second CT-scan performed three weeks after completion of a 14-day course of antibiotics, revealed a dilated long appendix (diameter: 12mm, length: 10 cm) with extension of its tip to the medial wall of sigmoid. Physicians should consider appendicitis when evaluating an acute abdomen to prevent any delay in diagnosis of atypical presentations and decrease the mortality and morbidity related to the complications.

Keywords: Appendicitis; Atypical; Left lower quadrant pain; Diagnosis

please cite this paper as:

Ajdarkosh H, Javid Anbardan S, Azizi Z, Ebrahimi Daryani N. An Atypical Presentation of Acute Appendicitis: A 77 Years Old Man with Left Lower Quadrant Pain, *Govaresh* 2016;21:72-75.

INTRODUCTION

The appendix is a vermiform and tubular section of the alimentary tract located at the ileocaecal junction. In terms of position, the appendix is the most variable organ in the abdomen with the retro-cecal and retro-

colic locations being the most common positions (1-5). With a lifetime occurrence of 7%, appendicitis is one of the most common abdominal emergencies requiring surgery(6,7).

While abdominal pain and anorexia are the prominent symptoms of appendicitis, the variable positions of the appendix are capable of influencing the clinical presentation. The variable positions may produce inconstant symptoms and signs which mimic other diseases. On rare occasions, acute appendicitis may present as left iliac fossa pain resembling diverticulitis. Furthermore, the length of the appendix is also an important factor affecting differential diagnosis (2,8-10).

Considering the fact that even with high prevalence of appendicitis, its diagnosis is still a challenge and any

Corresponding author:

Nasser Ebrahimi Daryani, MD
No.130, Second floor, Shahid Naseri Street, Valiasr Ave, Tehran, Iran
Telefax: +98 21 88793896
E-mail: nebrahim@sina.tums.ac.ir
Received: 23 Jan. 2016
Edited: 09 Mar. 2016
Accepted: 10 Mar. 2016

Table 1: Paraclinical data on admission

Complete blood count		Urine analysis (U/A)%		Stool exam (S/E)	
White blood cell (per mm ³)	10,000	Proteins	-	Occult blood(OB)	-
Polymorphonuclear (%)	80	Blood	-	White blood cell(WBC)	-
Lymphocyte (%)	15	WBC/HPF*	0-1	Red blood cell(RBC)	-
Hemoglobin (g/dl)	15	RBC/ HPF	0-1		
Platelet (per mL)	115,000	Cast/HPF	none		
C-reactive protein(mg/l)	110				
Erythrocyte sedimentation rate (mm/h)	60				

*: high power field

delay in diagnosis increases the risk of complications including abscess formation and perforation and mortality rate(11). Thus, having knowledge of the variations in the position of the appendix is of significant importance(6).

We introduce a case of acute appendicitis presenting with both left lower quadrant and right lower quadrant pain more pronounced in the right lower quadrant that was clinically misdiagnosed as diverticulitis.

CASE REPORT

A 77-year-old white man, referred to the emergency department with a one-day history of constant lower abdominal pain in either left lower quadrant or right lower quadrant more pronounced in the right lower quadrant. The patient also complained of subjective fever, chills, and dysuria.

The patient's medical history was significant for ischemic heart disease for which he had a percutaneous coronary intervention four years ago. Furthermore, he had undergone an angiography and stent placement two weeks prior to his current presentation due to emergence of new cardiovascular symptoms including vertigo. Meanwhile, he was receiving appropriate medications including Losartan, Atorvastatin, Aspirin, and Plavix. Physical examination revealed tenderness and rebound tenderness over lower quadrants of the abdomen (left and right) which were more pronounced on the right side.

Blood tests showed leukocytosis with bandemia along with elevated erythrocyte sedimentation rate (ESR) and C-reactive protein (CRP) levels (table1). Moreover, abdominal ultrasonography showed inflammation around both the appendix and the sigmoid bowel. An abdominopelvic computed tomography scan (CT-scan) with contrast was performed which

demonstrated a severe inflammation at paracecal mesenteric fat with extension to parasigmoid portion (figure1) which was in favor of diverticulitis rather than appendicitis. Given the presence of inflammation around both appendix and sigmoid, it was not possible to differentiate between diverticulitis and appendicitis. Likewise, considering the patient's medical history he was not a suitable candidate for surgical interventions based on cardiovascular consultation.

In the meantime, he developed high grade fever (oral temperature=39°C) followed by anorexia, nausea, vomiting. Thus, a 2-week treatment with intravenous antibiotic regimen containing Ciprofloxacin (200mg, every 12 hours) and Metronidazole (500 mg, every 8 hours) was initiated for the patient.

From the second day of antibiotic therapy, the patient's fever and abdominal pain improved while he was still anorexic. On the second week of therapy, the patient did well and his anorexia also improved and he was discharged in good condition and was advised to have a CT-scan 3 weeks later. Three weeks after completion of a 14-day course of antibiotics, a second CT-scan was performed which revealed a dilated long appendix (diameter: 12mm, length: 10 cm) with extension of its tip to the medial wall of sigmoid.

DISCUSSION

One of the commonly faced surgical emergencies is acute appendicitis with a reported annual rate of 9.38 per 10,000 in 2008(12,13). The condition is diagnosed in many cases by means of physical examination and laboratory tests. However, as the variations in size and position of the appendix related to the cecum influences the clinical picture of acute appendicitis; the classic presentation including a 48-hour periumbilical pain with localization to the right lower quadrant accompanied

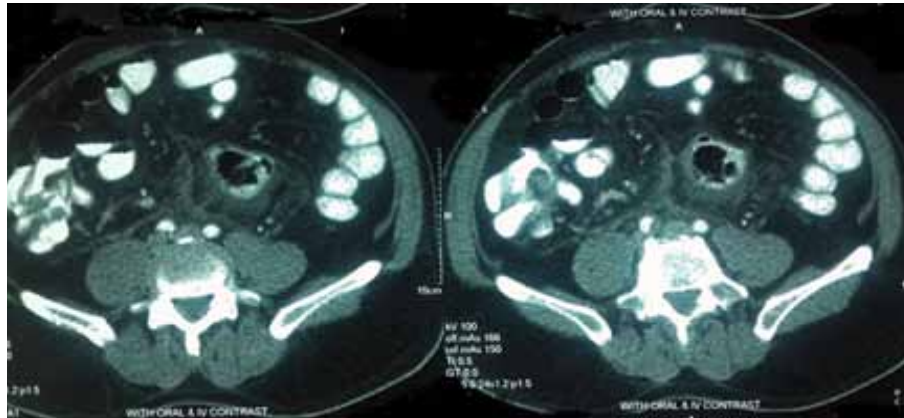


Fig. 1: Abdominopelvic computed tomography scan with contrast demonstrating a severe inflammation at paracecal mesenteric fat with extension to para sigmoid portion

by anorexia, nausea, and neutrophilic leukocytosis is only present in half of the patients(12,14,15).

Since variable positions of the appendix may mislead physicians and delay the diagnosis leading to devastating complications, diverse studies have evaluated the variations in anatomical positions, lengths, and morphology of the appendix. In a study performed by Ghorbani et al on 200 dead bodies in Zanjan province, Iran, the pelvic position was the most frequently detected location and the mean length was reported to be 91.2 mm and 80.3 mm in men and women, respectively(16).

In another study conducted on 100 Indian patients during appendectomy, a superomedial location was found to be the most prevalent location for the appendix(17). Likewise, a post-mortem study of 100 bodies in Bangladesh demonstrated that the pelvic position of the appendix was the most common position in all age groups(18). Moreover, a study conducted by Sudagar et al on 50 cadavers revealed that the retrocecal position was the commonest position(19).

Our case presented with constant lower abdominal pain in both left lower quadrant and right lower quadrant more pronounced in the right lower quadrant, which was in favor of diverticulitis rather than appendicitis. There are cases presented as cecal diverticulitis with the same signs and symptoms as acute appendicitis that can be misdiagnosed(20,21). Nevertheless, misdiagnosis of appendicitis with diverticulitis is a rare presentation of appendicitis. Meanwhile an early diagnosis is the most important factor influencing the prognosis of acute appendicitis thus it is crucial to diagnose atypical presentations to prevent missing acute cases and avoid

possible complications(13,15, 22). In recent decades, because of its high accuracy ranging from 93-99%, CT has become the optimal diagnostic modality in patients with suspected appendicitis specially the ones with atypical presentation including presentation with left lower quadrant pain(12, 23-26).

This case report highlights the importance of atypical appendicitis when evaluating an acute abdomen in order to prevent any delay in diagnosis of atypical presentations and decrease the mortality and morbidity.

REFERENCES

1. Boddeti RK, Kulkarni R, Murudkar PKH. Unique 28 cm long vermiform appendix. *Int J Anat Res* 2013;1:111-14.
2. Mwachaka P, El-busaidy H, Sinkeet S, Ogeng'o J. Variations in the Position and Length of the Vermiform Appendix in a Black Kenyan Population. *ISRN Anatomy* 2014; 871048.
3. Delić J, Savković A, Isaković E. [Variations in the position and point of origin of the vermiform appendix]. *Med Arh* 2002;56:5-8.
4. Ahmed I, Asgeirsson KS, Beckingham IJ, Lobo DN. The position of the vermiform appendix at laparoscopy. *Surg Radiol Anat* 2007;29:165-8.
5. Banerjee A, Kumar IA, Tapadar A, Pranay M. Morphological Variations in the Anatomy of Caecum and Appendix-A Cadaveric Study. *Nat J Clin Anat* 2012;1:30-5.
6. Shogilev DJ, Duus N, Odom SR, Shapiro NI. Diagnosing Appendicitis: Evidence-Based Review of the Diagnostic Approach in 2014. *West J Emerg Med* 2014;15:859-71.

7. Gwynn LK. The diagnosis of acute appendicitis: clinical assessment versus computed tomography evaluation. *J Emerg Med* 2001;21:119-23.
8. Pittman-Waller VA, Myers JG, Stewart RM, Dent DL. Appendicitis: why so complicated? Analysis of 5755 consecutive appendectomies. *Am Surg* 2000;66:548-54.
9. Ahangar S, Zaz M, Shah M, Wani SN. Perforated subhepatic appendix presenting as gas under diaphragm. *Indian J Surg* 2010;72:273-4.
10. Nayak SB, George BM, Mishra S, Surendran S, Shetty P, Shetty SD. Sessile ileum, subhepatic cecum, and uncinata appendix that might lead to a diagnostic dilemma. *Anat Cell Biol* 2013;46:296-8.
11. Welte FJ, Grosso M. Left-sided appendicitis in a patient with congenital gastrointestinal malrotation: a case report. *J Med Case Rep* 2007;1:92.
12. Stathaki MI, Koutroubakis IE, Koukouraki SI, Karmiris KP, Moschandreas JA, Kouroumalis EA, et al. Active inflammatory bowel disease: head-to-head comparison between 99mTc-hexamethylpropylene amine oxime white blood cells and 99mTc (V)-dimercaptosuccinic acid scintigraphy. *Nucl Med Commun* 2008;29:27-32.
13. Lee BF, Chiu NT, Wu DC, Tsai KB, Liu GC, Yu HS, et al. Use of 99mTc (V) DMSA Scintigraphy in the Detection and Localization of Intestinal Inflammation: Comparison of Findings at Colonoscopy and Biopsy 1. *Radiology* 2001;220:381-5.
14. Berry Jr J, Malt RA. Appendicitis near its centenary. *Ann Surg* 1984;200:567-75.
15. Gomes P, du Boulay C, Smith C, Holdstock G. Relationship between disease activity indices and colonoscopic findings in patients with colonic inflammatory bowel disease. *Gut* 1986;27:92-5.
16. Ghorbani A, Forouzes M, Kazemifar AM. Variation in Anatomical Position of Vermiform Appendix among Iranian Population: An Old Issue Which Has Not Lost Its Importance. *Anat Res Int* 2014;2014: 313575.
17. Hegde D, Hegde SD. Variables in right iliac fossa anatomy and their relevance to appendectomy: improving knowledge and practices. *Clin Anat* 2008;21:165-70.
18. Rahman M, Khalil M, Rahman H, Mannan S, Sultana S, Ahmed S. Anatomical positions of vermiform appendix in Bangladeshi people. *J Bangladesh Soci Physiol* 2006;1:5-9.
19. Sudagar M, Sivakumaran G, Raziya Banu M. Anatomical Variations in the Position of Vermiform Appendix—A Cadaveric Study. *J Advan Med Life Sci* 2014; 2:10.
20. Shin JH, Son BH, Kim H. Clinically distinguishing between appendicitis and right-sided colonic diverticulitis at initial presentation. *Yonsei Med J* 2007;48:511-6.
21. Pastore R, Lenza Rd M, Rodrigues FB, Tostes LV, Guerra NC, Crema E. Cecal diverticulitis or appendicitis. When should I suspect? A case report. *J Coloproctol (Rio de Janeiro)* 2012;32:180-3.
22. Tamburrini S, Brunetti A, Brown M, Sirlin CB, Casola G. CT appearance of the normal appendix in adults. *Eur Radiol* 2005;15:2096-103.
23. Akbulut S, Ulku A, Senol A, Tas M, Yagmur Y. Left-sided appendicitis: review of 95 published cases and a case report. *World J Gastroenterol* 2010;16:5598-602.
24. See T, Watson C, Arends M, Ng C. Atypical appendicitis: the impact of CT and its management. *J Med Imaging Radiat Oncol* 2008;52:140-7.
25. Levine C, Aizenstein O, Wachsberg R. Pitfalls in the CT diagnosis of appendicitis. *Br J Radiol* 2004;77:792-9.
26. Pinto Leite N, Pereira JM, Cunha R, Pinto P, Sirlin C. CT evaluation of appendicitis and its complications: imaging techniques and key diagnostic findings. *AJR Am J Roentgenol* 2005;185:406-17.