

Comparison of the Success Rate and Complications of Blind Liver Biopsy and Ultrasound-Guided Liver Biopsy

Ahmad Hormati¹, Mohammad Reza Ghadir², Sajjad Rezvan³,
Abolfazl Mohammadbeigi⁴, Faezeh Alemi^{5,*}

¹ Assistant Professor of Gastroenterology, Gastroenterology and Hepatology Diseases Research Center, Qom University of Medical Sciences, Qom, Iran

² Professor of Gastroenterology, Gastroenterology and Hepatology Diseases Research Center, Qom University of Medical Sciences, Qom, Iran

³ Resident of Radiology, Rafsanjan University of Medical Sciences, Rafsanjan, Iran

⁴ Associate Professor of Epidemiology, Gastroenterology and Hepatology Diseases Research Center, Qom University of Medical Sciences, Qom, Iran

⁵ General Practitioner, Gastroenterology and Hepatology Diseases Research Center, Qom University of Medical Sciences, Qom, Iran

ABSTRACT

Background:

Liver biopsy is the gold standard method for the assessment of liver fibrosis and diagnosis of different liver diseases. The most common method of liver biopsy is transdermal biopsy, which can be performed under the guidance of ultrasound (US) or blindly. The present study aimed at comparing the success rate and complications of these two methods in patients undergoing liver biopsy.

Materials and Methods:

This interventional study was performed on 102 patients, who were candidates for liver biopsy without any contraindications. The patients were randomly divided in two groups of US-guided biopsy and blind biopsy. The patients' demographics, indications for biopsy, and complications were collected in a checklist. Data were analyzed using Chi-square test and independent sample t-test in SPSS version 16.

Results:

Among 102 participants, 51 patients (25 males and 26 females), with the mean age of 39.69 ± 12.93 years, underwent US-guided biopsy, while 51 patients (29 males and 26 female), with the mean age of 39.65 ± 13.73 years, underwent blind biopsy. Liver biopsy was successful in 88.2% of the patients in both groups. The most common complication was reduced hemoglobin level, which was not significantly different between the groups. Other complications, such as need for blood transfusion, platelet transfusion, or fresh frozen plasma (FFP) injection, were not observed. There was no significant difference in terms of complications between the groups.

Conclusion:

Since blind liver biopsy does not increase the rate of complications, application of this method is recommended for patients without any contraindications, leading to a reduction in the cost of diagnosis and treatment.

Keywords: Image-guided biopsy; Liver disease; Liver biopsy; Complications; Ultrasound-guided biopsy

please cite this paper as:

Hormati A, Ghadir MR, Rezvan S, Mohammadbeigi A, Alemi F. Comparison of the Success Rate and Complications of Blind Liver Biopsy and Ultrasound-Guided Liver Biopsy. *Govareh* 2019;24:58-62.

*Corresponding author:

Faezeh Alemi, MD

General Practitioner, Gastroenterology and Hepatology Diseases Research Center, Qom University of Medical Sciences, Shahid Beheshti Hospital, Qom, Iran

Telefax: + 98 25 36122053

E-mail: faezeh.alemi@gmail.com

Received: 24 Aug. 2018

Edited: 21 Jan. 2019

Accepted: 22 Jan. 2019

INTRODUCTION

In recent years, various non-invasive methods have been introduced to evaluate tissue damage and liver fibrosis in different liver diseases. Nevertheless, biopsy is still recognized as the gold standard method for the diagnosis of liver damage in many diseases. It is also helpful in adopting therapeutic policies and evaluating the effectiveness of treatment (1-4).

To diagnose a group of liver diseases, blood and laboratory tests are usually sufficient, whereas histological examination is required for the diagnosis of some diseases, especially liver diseases with unusual

clinical findings (5,6). For instance, liver biopsy is used to identify the severity of diseases, such as autoimmune hepatitis, alcoholic fatty liver disease, non-alcoholic fatty liver disease, drug reactions, metabolic diseases such as Wilson's disease and hemochromatosis, and liver cancer (7).

Today, there are several methods of liver biopsy, and their selection is based on the patient's accessibility, preference, and clinical condition. These biopsy methods include transdermal liver biopsy, biopsy through the jugular vein, laparoscopy, and ultimately open abdominal surgery. The most common liver sampling method is transdermal biopsy, which can be applied with or without ultrasound (US) guidance, creating a higher margin of safety (8). This method is especially recommended for patients with a small liver, coagulation disorder, or congenital malformation of the gallbladder. Moreover, if there is a localized lesion in the liver, US or CT scan-guided biopsy is necessary (9,10). The complications of liver biopsy are generally limited and include pain, bleeding, biliary peritonitis, and death in very rare cases.

So far, limited studies have compared two methods of blind liver biopsy using physical examination and US-guided biopsy. Previous studies have often considered cost-effectiveness in the selection of methods (11,12). With this background in mind, the aim of this study was to investigate and compare the complications and consequences of blind biopsy and US-guided biopsy. These findings can be helpful in determining the best treatment option with respect to the patient's clinical condition.

MATERIALS AND METHODS

This clinical trial was conducted on 102 patients with indications for liver biopsy, referred to the gastroenterology and liver clinic of Ahvaz Imam Khomeini Hospital, Iran. The inclusion criteria were as follows: 1) patient's consent; and 2) biopsy indications, such as abnormal liver tests, abnormal liver findings in radiological studies, diagnosis of parenchymal diseases, and histological responses to the treatment of liver disease.

On the other hand, the exclusion criteria were as follows: 1) patient's unwillingness to continue the study; 2) patient's inability to cooperate; 3) diagnosis of coagulation disorder or uncorrected thrombocytopenia; 4) use of nonsteroidal anti-inflammatory drugs (NSAIDs), anticoagulants, antiplatelet drugs, or aspirin in the past seven days; 5) unfeasibility of blood transfusion if needed; 6) suspected hemangiomas;

7) vascular tumors or hydatid cysts in radiological studies; 8) severe obesity; 9) ascites; 10) hemophilia; and 11) evidence of local infection.

Consecutive sampling, based on the mentioned criteria, continued in an accessible population until recruiting 102 samples. The samples were then randomly divided into two groups of blind biopsy with physical examination and US-guided biopsy. All the study procedures were explained to the participants by the physician, and informed consent forms were collected. None of the patients were diagnosed with cirrhosis. Demographic information, including age, gender, height, weight, underlying diseases, indications for biopsy, and medication use, was collected in a checklist.

Laboratory tests, including complete blood cell count (CBC), prothrombin time (PT), partial thromboplastin time (PTT), and international normalized ratio (INR), were requested for all patients. The patients were excluded in the event of platelet count below 60000 μ L, PT longer than four seconds, and INR above 1.5. The accurate history of medication use was taken from the patients, and in case of NSAID or aspirin use, it was recommended to discontinue drug use one week before biopsy due to the increased risk of bleeding. Also, patients in both groups underwent a US examination for anatomical variations, evidence of cirrhosis and ascites, and presence of sporadic liver tumors; given the infeasibility of blind biopsy in such cases, they were withdrawn from the study. All the information was recorded in a checklist.

Diabetic patients were advised not to use insulin or hypoglycemic agents on the morning of the biopsy. Venous access was established in all patients to replace fluids and blood if needed. Both types of biopsy were performed in the supine position with the right arm under the head. For inducing analgesia, 2-4 mL of 2% lidocaine solution was injected using a 5-mm syringe at the upper margin of the intercostal space. Samples from 51 patients in the blind biopsy group were collected by an experienced gastroenterologist. Percussion of the right hemithorax was done on the midaxillary line in the inspiration and expiration phases to determine the point with maximum dullness, which is normally between the sixth and ninth ribs in the eighth intercostal space; this point was marked after the examination.

Samples were collected using a semi-automatic TruCut biopsy needle (18 gauge). The length and diameter of the liver samples were 1-3 cm and 1.2-

Table 1: Patients' Demographics Divided by Groups

Variables			US Guided Biopsy	Blind Biopsy	Total	P-value
Gender	Male	Number	25	29	54	0.427
		Percent	54.9	56.9	52.9	
	Female	Number	26	22	48	
		Percent	45.1	43.1	47.1	
Age		39.69 ± 12.93	39.65 ± 13.73	-	0.988	
BMI		26.47 ± 7.59	24.76 ± 6.30	-	0.220	

2 mm, respectively. After the samples were added to sterile formalin, they were transferred to the laboratory. The US-guided biopsy was performed among 51 patients by an experienced radiologist, using a 5-MHz US probe (Siemens). In the hand-free technique, the radiologist held a semi-automatic biopsy needle (18 gauge; TruCut) and a US probe in two hands, and biopsy samples were collected from the target site under monitoring. Immediately after biopsy, radiological evaluation was carried out to determine complications, such as bleeding and perforation of the gallbladder; the results were recorded in each patient's checklist.

The patients relaxed in the right decubitus position for up to two hours after biopsy. The vital signs were monitored every 15 minutes during the first hour, every 30 minutes during the second hour, and every hour until discharge. As several studies have shown that the majority of complications occur within the first three hours after biopsy, it is recommended to hospitalize the patients for six hours following biopsy. Therefore, all the participants in this study were monitored in the hospital for at least six hours after biopsy.

The occurrence of any complications during or after the procedure, along with the therapeutic interventions, was recorded in each patient's checklist. After six hours, the patients' diet was initiated, and they were discharged in the absence of any specific problems. Upon discharge, the patients were advised to visit the hospital in the event of abdominal pain, fever, shortness of breath, or bleeding, and they were asked to avoid heavy physical activity and lifting more than 6-kg loads for the next 7 days.

Data were analyzed in SPSS version 20. For describing the data, mean and standard deviation were measured, and for comparing the groups, Chi-square and independent t-test were applied. *P*-value < 0.05 was considered statistically significant.

RESULT

The blind biopsy group included 51 patients with the mean age of 39.66 ± 13.73 years and the mean BMI of 27.40 ± 6.40 kg/m², while the US-guided biopsy group consisted of 51 patients with the mean age of 39.69 ± 12.93 years and the mean BMI of 26.47 ± 7.59 kg/m²; these characteristics were not significantly different between the groups. In the total population, 54 (52.94%) patients were male and 48 (47.06%) patients were female. Gender differences between the two groups were not significant (*p* = 0.427). Table 1 presents the demographic characteristics of the groups.

Biopsy was successful in 90 (88.2%) cases (45 cases in the US-guided group and 45 cases in the blind biopsy group), while it was unsuccessful in 12 (11.8%) cases (six cases in the US-guided biopsy group and six cases in the blind biopsy group). There was no significant difference in the success rate of biopsy between the two groups. The most frequent biopsy indication was liver enzyme disorder, as reported in 28 (27.45%) cases, while the least frequent indications were HIV and fatty liver disease (n, 1; 0.98%). figure 1 presents the frequency of biopsy indications in each group.

In terms of complications, 19 (18.6%) patients reported abdominal pain, while nine (8.8%) patients experienced bleeding. Based on the findings, one patient from each group needed platelet transfusions, two patients from each group required fresh frozen plasma (FFP) injections, and three patients from the US-guided group and four patients from the blind biopsy group required blood transfusions.

In the blind biopsy group, reduction of hemoglobin level was reported in six patients, with the mean reduction of 1.0 ± 0.3 g/dL. On the other hand, in the US-guided biopsy group, hemoglobin level reduced in six cases, with the mean reduction of 1.06 ± 0.24 g/dL. Based on the independent t-test, the difference in the mean reduction of hemoglobin level was not significant between the groups (*p* = 0.466).

Table 2: Complications of Biopsy Divided by Groups

Variables	US Guided Biopsy		Blind Biopsy		P-value
	Yes	Number (%)	Yes	Number (%)	
Need to Transfusion	Yes	3 (5.9)	Yes	4 (7.8)	0.695
	No	48 (94.1)	No	47 (92.2)	
Need to Platelet	Yes	1 (2)	Yes	1 (2)	1.000
	No	50 (98)	No	50 (98)	
Need to FFP	Yes	2 (3.9)	Yes	2 (3.9)	1.000
	No	49 (96.1)	No	49 (96.1)	
Hemoglobin Reduction	Yes	6 (11.8)	Yes	6 (11.8)	1.000
	No	45 (88.2)	No	45 (88.2)	
Fever	Yes	3 (5.9)	Yes	2 (3.9)	0.647
	No	48 (94.1)	No	49 (96.1)	
Hemoptysis	Yes	1 (2)	Yes	2 (3.9)	0.558
	No	50 (98)	No	49 (96.1)	

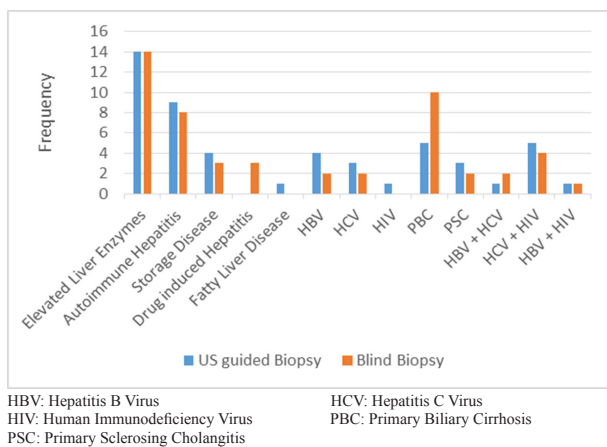


Fig. 1: Indications of Liver Biopsy, Divided by Groups

In addition, five cases of fever (4.9%) and three cases of hemoptysis (2.9%) were reported, while there was no gallbladder perforation or death. Table 2 summarizes different complications in the two groups. Based on the values presented in this table, the incidence of complications was not significantly different between the groups. Also, there was no significant difference in the biopsy indications between the groups ($p = 0.574$).

DISCUSSION

Blind liver biopsy is an old method, which was introduced for the first time in 1883. Despite significant technical advances for quality improvement and reduction of complications, image-guided biopsy, including US-guided biopsy, is more popular than blind biopsy today (13). In this regard, a study

conducted in the United States showed that more than 60% of gastroenterologists use sonography prior to biopsy to mark the appropriate biopsy point, and nearly 20% of biopsies are performed under direct US guidance by a radiologist (14). Similar studies from England suggest that more than 30% of liver biopsies are done by a radiologist (15). Considering the higher cost of US-guided biopsy and its similarity to blind biopsy in terms of efficacy and complications, it seems reasonable to apply blind biopsy in patients without any contraindications.

The aim of the present study was to evaluate the success rate and complications of US-guided liver biopsy in comparison with blind liver biopsy with routine examination. The most common biopsy indication was enzymatic disorder, while HIV infection and fatty liver were the least common ones (1% each). The biopsy indications were not significantly different between the two groups. Also, the success rate of biopsy was not significantly different between the groups.

Among the evaluated complications, hemoglobin reduction was the most frequent of all. The mean hemoglobin reduction was 1.10 ± 0.30 g/dL in the blind biopsy group and 0.610 ± 0.240 g/dL in the US-guided group; the difference between the groups was not significant. Other complications included need for blood transfusion, fever, need for FFP injection, hemoptysis, and need for platelet transfusion, respectively. However, there was no significant difference between the two groups in terms of the incidence of complications.

Moreover, a study by Nuiley et al. in 2003 reported abdominal pain and bleeding as the most common

complications. This study showed that the success rate of biopsy was not significantly different between the blind biopsy and US-guided biopsy groups. However, an increase in the number of biopsy attempts was associated with an increased risk of hemorrhage (16). Also, Mogahed et al. in 2016 compared the complications of blind biopsy in children using physical examination and US guidance. The results indicated that intrahepatic hematoma following biopsy was the most common complication. Major and minor complications were not significantly different between the groups (17).

In addition, a study by Cleaver et al. in 1999 compared the costs and advantages of US-guided biopsy with CT scan-guided biopsy. Based on the results, US-guided biopsy is preferable to CT scan, given its higher success rate, besides its time-saving and cost-effective procedures. Therefore, when performing a biopsy, regardless of the method, factors of cost and time should be taken into account, besides the complications (18).

Moreover, in a similar study by Gilmour et al., entitled "Indications, methods, and outcomes of percutaneous liver biopsy in England and Wales: An audit by the British Society of Gastroenterology and the Royal College of Physicians of London", use of US-guided biopsy was more desirable than blind biopsy due to reduced complications and better diagnostic performance. This finding is not compatible with the present results, and the researchers believe that the effect of cost can be influential in the selection of biopsy method (15).

CONCLUSION

According to the present results and previous research, there is no significant difference in the rate of success and incidence of complications between blind biopsy and US-guided biopsy; therefore, it seems reasonable to apply blind biopsy in patients without any contraindications for this method. Accurate selection of methods and patients, along with consideration of accuracy and expertise in biopsy performance, not only imposes no risk to patients, but also reduces the cost of diagnosis and treatment both for the patients and healthcare system.

ACKNOWLEDGEMENTS

We want to thank all the participants of this research.

CONFLICT OF INTEREST

The authors declare no conflict of interests related to this work.

REFERENCES

1. Bravo AA, Sheth SG, Chopra S. Liver biopsy. *N Engl J Med* 2001;344:495-500.
2. Seyedian SS, Hajiani E, Hashemi SJ, Masjedizadeh A, Akbar Shayesteh A, Alavinejad P, et al. Relationship between serum ferritin level and transient elastography findings among patients with nonalcoholic fatty liver disease. *J Family Med Prim Care* 2017;6:750-4.
3. Hormati A, Shakeri M, Iranikhah A, Afifian M, Sarkeshikian SS. Non-Alcoholic Fatty Liver Disease. *Govareh* 2019;23:168-77.
4. Hormati A, Hajiani E, Shayesteh AA, Masjedizadeh AR, Jalal Hashemi S, Seyedian SS, et al. The Diagnostic Value Non Invasive Tests in Predicting Liver Fibrosis. *Jundishapur Sci Med J* 2014;13:533-43.
5. Iranikhah A, Hormati A, Shakeri M, Aghaali M. Non-alcoholic Fatty Liver Disease in Children. *J Mazandaran Univ Med Sci* 2018;28:230-42.
6. General principles. In: Lee RG. *Diagnostic liver pathology*. St .Louis: Mosby-Year Book, 1994:1-21.
7. Lohse AW. Rolls Royce for everybody? Diagnosing liver disease by mini-laparoscopy. *J Hepatol* 2011;54:584-5.
8. Garcia-Tsao G, Boyer JL. Outpatient liver biopsy: how safe is it? *Ann Intern Med* 1993;118:150-3.
9. Colombo M, Del Ninno E, de Franchis R, De Fazio C, Fistorazzi S, Ronchi G, et al. Ultrasound-assisted percutaneous liver biopsy: superiority of the Tru-Cut over the Menghini needle for diagnosis of cirrhosis. *Gastroenterology* 1988;95:487-9.
10. Smith CI, Grau JE. The effect of ultrasonography on the performance of routine outpatient liver biopsy. *Hepatology* 1995;22:384A.
11. Pasha T, Gabriel S, Therneau T, Dickson ER, Lindor KD. Cost-effectiveness of ultrasound-guided liver biopsy. *Hepatology* 1998;27:1220-6.
12. Younossi ZM, Teran JC, Ganiats TG, Carey WD. Ultrasound-guided liver biopsy for parenchymal liver disease: an economic analysis. *Dig Dis Sci* 1998;43:46-50.
13. John A, Al Kaabi S, Soofi ME, Mohammadi M, Kandath SM, Derbala M, et al. Liver biopsy for parenchymal liver disease - is routine real time image guidance unnecessary? *Indian J Gastroenterol* 2014;33:50-4.
14. Angtuaco TL, Lal SK, Banaad-Omiotek GD, Zaidi SS, Howden CW. Current liver biopsy practices for suspected parenchymal liver diseases in the United States: the evolving role of radiologists. *Am J Gastroenterol* 2002;97:1468-71.
15. Gilmore IT, Burroughs A, Murray-Lyon IM, Williams R, Jenkins D, Hopkins A. Indications, methods, and outcomes of percutaneous liver biopsy in England and Wales: an audit by the British Society of Gastroenterology and the Royal College of Physicians of London. *Gut* 1995;36:437-41.
16. Nobili V, Comparcola D, Sartorelli MR, Natali G, Monti L, Falappa P, et al. Blind and ultrasound-guided percutaneous liver biopsy in children. *Pediatr Radiol* 2003;33:772-5.
17. Mogahed EA, Mansy YA, Al Hawi Y, El-Sayed R, El-Raziky M, El-Karaksy H. Blind percutaneous liver biopsy in infants and children: Comparison of safety and efficacy of percussion technique and ultrasound assisted technique. *Arab J Gastroenterol* 2016;17:168-75.
18. Kliewer MA, Sheafor DH, Paulson EK, Helsper RS, Hertzberg BS, Nelson RC. Percutaneous liver biopsy: a cost-benefit analysis comparing sonographic and CT guidance. *AJR Am J Roentgenol* 1999;173:1199-202.