

## A 68-Year-Old Man with Recurrent Upper Gastrointestinal Bleeding

Mohammad Hossein Somi <sup>1</sup>, Masood Faghih Dinevari <sup>1,\*</sup>, Amin Sadrazar <sup>1</sup>, Ali Riazi <sup>1</sup>,  
Reza Javadrashid <sup>1</sup>, Mohammad Bassir Abolghasemi Fakhri<sup>1</sup>

<sup>1</sup> Liver and Gastrointestinal Diseases Research Center, Tabriz University of Medical Sciences, Tabriz, Iran.

### ABSTRACT

In the present report, a 68-year-old man with recurrent hematemesis and melena is described. Upper gastrointestinal (UGI) endoscopy and colonoscopy showed normal findings. Abdominal computed tomography showed an aneurysm of left common iliac artery and duodenum located at the superior part of the aneurysm without contrast extravasation. So the aortoenteric fistula was suspected and surgical management of aortoenteric fistula (AEF) was done and the patient recovered successfully without complications. The diagnostic evaluation and management of AEF are discussed.

**Keywords:** Aortoenteric fistula; Upper gastrointestinal bleeding; Aneurysm

*please cite this paper as:*

Somi MH, Faghih Dinevari M, Sadrazar A, Riazi A, Javadrashid R, Abolghasemi Fakhri BM. A 68-Year-Old Man with Recurrent Upper Gastrointestinal Bleeding. *Govareh* 2019;24:184-188.

### INTRODUCTION

Primary aortoenteric fistula (PAEF) is the cause of massive gastrointestinal (GI) bleeding, which is resulted from aortic erosion and leads to communication between the aorta and GI system (1). Owing to the position of the third portion of the duodenum in the retroperitoneum and its proximity to the descending aorta, the PAEF is mostly occurring at this portion (2,3).

PAEF is mainly caused by atherosclerotic aneurysms traumatic or mycotic aneurysms, and less commonly, caused by metastases, pancreatic carcinoma, ulcers, gallstones, diverticulitis, and cystic medial necrosis (4).

Although PAEF is a rare clinical entity, if left untreated, it is fatal and early diagnosis is essential for a successful outcome. However, owing to insidious episodes of GI bleeding, a timely diagnosis may be challenging and the high index of clinical suspicion is critical for timely diagnosis and management (5).

PAEF is most frequently diagnosed by computed tomography (CT) and esophagogastroduodenoscopy (EGD). Contrast-enhanced CT of the abdomen is the preferred diagnostic test of choice (6).

In the present study, we report a case of a 68-year-old man with GI bleeding of unknown origin that was treated successfully.

This case demonstrates the importance of considering aortoenteric fistula (AEF) as one of the unusual causes of GI bleeding and the importance of early diagnosis and surgical treatment of aortoenteric fistula.

### \*Corresponding author:

Masood Faghih Dinevari, MD

Liver and Gastrointestinal Diseases Research Center,  
Tabriz University of Medical Sciences, Tabriz, Iran

Telefax: + 98 41 33347189

Email: Masood.dinevari@gmail.com

Received: 27 Apr. 2019

Edited: 28 Jul. 2019

Accepted: 29 Jul. 2019

### CASE REPORT

In the present report, a 68-year-old man who was admitted to Imam Reza Hospital, Tabriz, Iran for further evaluation of recurrent GI bleeding is described. He was born in Iran and worked as a farmer in the rural area of East Azarbaijan. He was a smoker (about 40 pack/year) with a medical history of hypertension and surgical history of inguinal

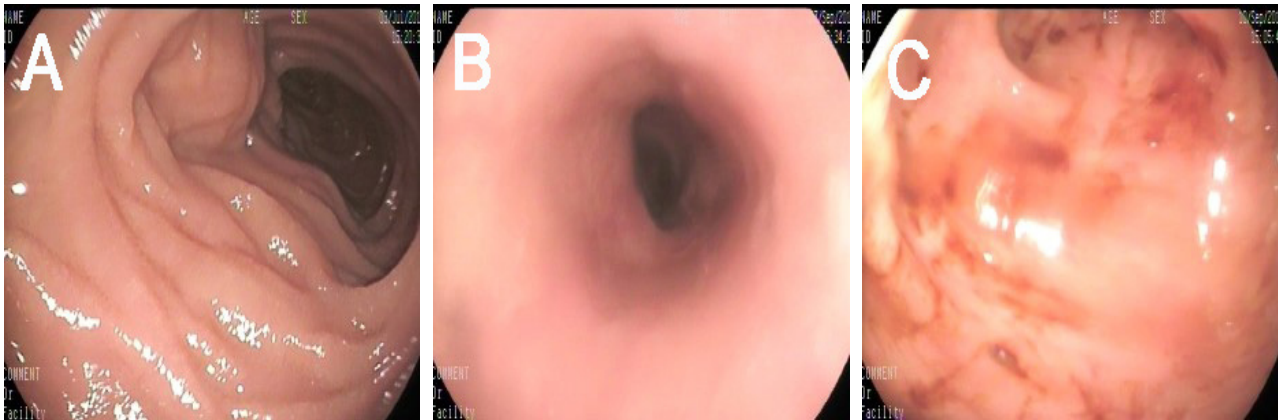


Fig.1: A: Unremarkable duodenum, B: unremarkable esophagus, C: Superficial erosions in the stomach

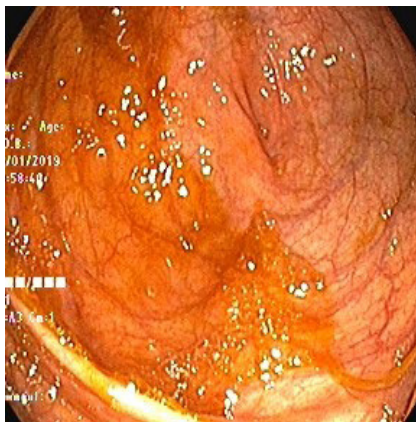

Fig.2: Unremarkable cecum

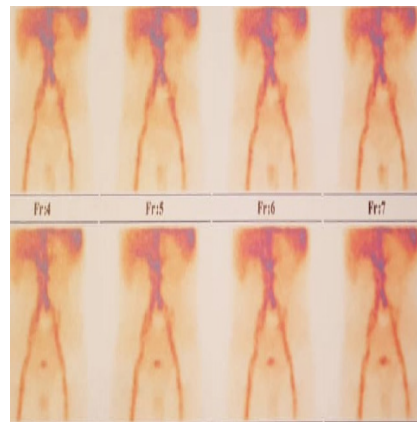


Fig.3: RBC Tc scan: active gastrointestinal bleeding in the midline of upper abdomen

herniorrhaphy. He was suffering from rest pain, coldness, and claudication of left lower limb because of atherosclerosis of popliteal artery, and was a candidate for angioplasty of popliteal artery.

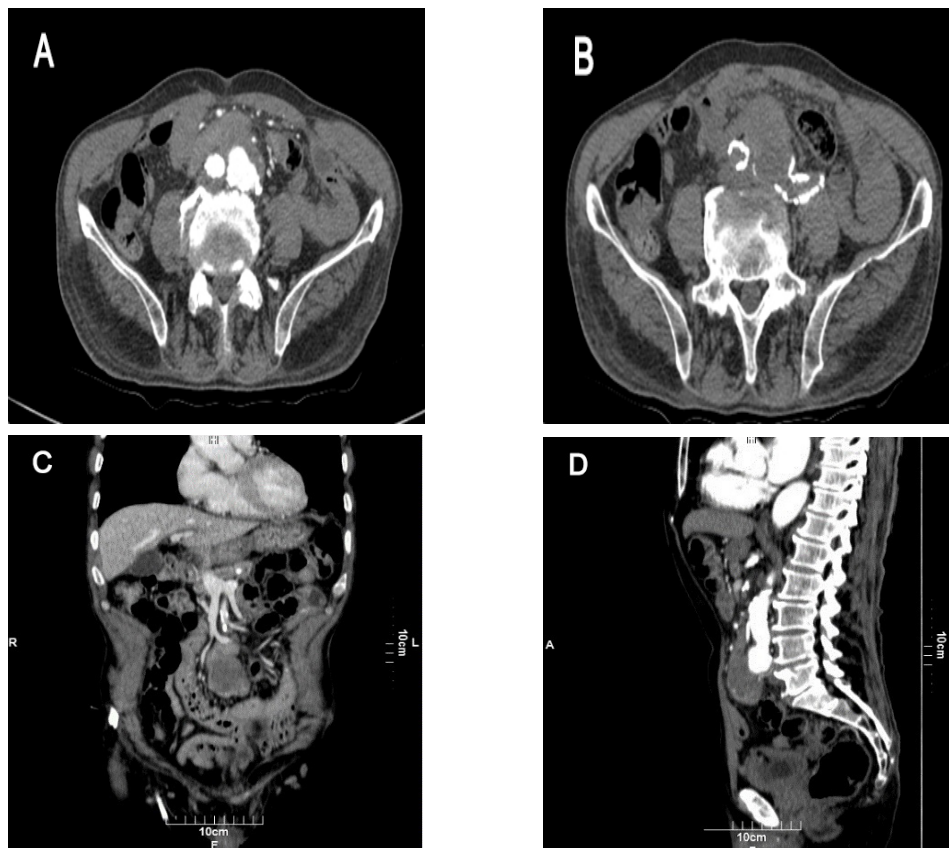
Four months before admission, the patient had hematemesis and complaining of “black stool”. The findings of esophagogastroduodenoscopy and colonoscopy were normal and because of anemia, four units of packed red cells were transfused in a 4-month period but the source of bleeding was remained unidentified.

He was admitted to our hospital complaining of hematemesis. At admission, he had the hemoglobin (Hb) and hematocrit levels of 5.9 g/dL and 20%, respectively. In standing and supine positions, his blood pressure was 170/90 mmHg and 180/90 mmHg, respectively, and his pulse rate was 90 and 75 beats per minute, respectively. Physical examination showed

filiform pulsation of the left posterior tibialis artery. There was neither abdominal tenderness nor pulsation mass on the abdomen. Other laboratory data such as electrolytes and liver function tests were normal. A stool specimen was black. The report of upper GI (UGI) endoscopy indicated unremarkable findings in esophagus and duodenum. Superficial erosions were seen in the stomach without active bleeding in the antrum (figure 1). As shown in figure 2, the colonoscopy showed normal findings up to cecum. The endoscopic biopsy of erosion showed chronic gastritis, negative for dysplasia, and helicobacter pylori infection.

The patient had hematemesis at current admission and was transfused two units of packed RBC. The results of RBC Tc scan was indicated an active GI bleeding in the midline of the upper abdomen (figure 3).

CT of the abdomen and pelvic with intravenous

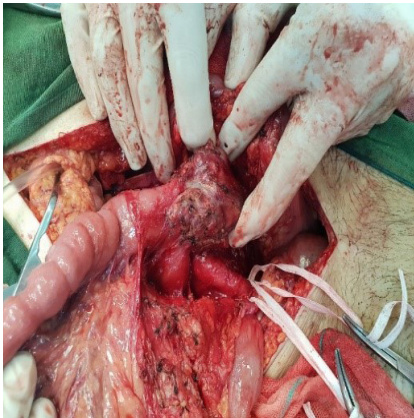


**Fig.4:** A, B: Axial. C: Coronal. D: Sagittal images show saccular aneurysm at left common iliac artery containing mural thrombosis

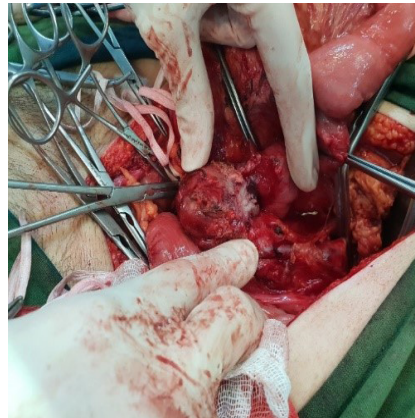contrast revealed “A 59-mm saccular aneurysm with mural thrombosis at the origin and left common iliac artery”. The aneurysm was projected superiorly. The transverse segment and duodenum were displaced inferiorly and located at supero-anterior aspect of the aneurysm. The fat plane between the aneurysm and the duodenum was obliterated. Mild wall thickening was noted at duodenum beside the aneurysm. There was no sign of active contrast extravasation from the aneurysm to the duodenum and also no sign of active extravasation at other part of GI tract (figure 4).

Considering the findings (recurrent hematemesis, and decreased Hb levels) ileo-enteric fistula was suspected and the findings of midline laparotomy suggested an inflammatory aneurysm at the origin of the left common iliac artery. The sigmoid colon and the fourth portion of the duodenum had dense adhesions to the aneurysm (figure 5). The diagnosis was the fistula of the duodenum to left common iliac aneurysm. It was possible to lyse adhesions of

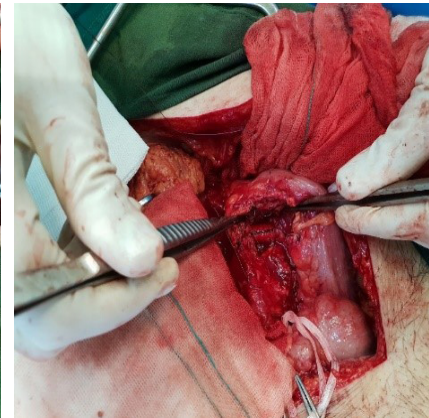
sigmoid colon, but the duodenum was firmly adhered to the aneurysm. After vascular control of aorta and both iliac arteries, duodenum was sharply dissected from the iliac aneurysm, causing the aneurysm to open (figure 6). Due to the lack of gross contamination, direct repair of the iliac aneurysm was done with 8-mm Dacron interposition graft (figure 7) and was covered by omentum. Forth portion of the duodenum was partially resected and repaired in two layers. The patient was transferred to surgical ICU. He was hemodynamically stable, and bilateral femoral pulses were normal. In the following days, there was no decrease in Hb levels. At 5th postoperative day, the oral diet was started, and the patient was discharged 2 days later with normal Hb level and no hematemesis or melena. During the follow-up period (1 week, 1 month, and 2 months after discharge), there was no melena or hematemesis and Hb levels were normal. At 2 post-operative months, the patient underwent balloon angioplasty of left popliteal artery and the



**Fig.5:** Dense adhesions of sigmoid colon and forth portion of the duodenum to the aneurysms



**Fig.6:** Dissection of the duodenum from the iliac aneurysms



**Fig.7:** Direct repair of the iliac aneurysm with 8-mm Dacron interposition graft

symptoms of coldness, rest pain, and claudication relieved. After angioplasty, he is on the treatment with ASA, Plavix, and atorvastatin.

## DISCUSSION

Aortoduodenal fistula (ADF) is a direct communication between the abdominal aorta and GI system, which could be primary (de novo communication between the duodenum and the aneurysmal aorta) or secondary (occurs from surgical repair of a prior aortic aneurysm). Primary ADF is rare (7) but with morbid diagnosis (mortality rate and perioperative mortality rate of 80–100% and 18–63%, respectively) (8-10). Atherosclerotic aneurysms are the main cause of PAEF (in 73% of the cases) but it may also occur due to traumatic or mycotic aneurysms (4).

The diagnosis and treatment of aortoenteric fistulas are difficult because of their non-specific and subtle clinical presentation (10, 11). The classical clinical presentation of PAEF include abdominal pain, GI bleeding, and pulsatile mass; however it is only presented in 11-38.5% of the patients. GI bleeding is the most prevalent presentation (which is seen in 94% of the patients) followed by abdominal pain (which is seen in 35% of the patients) and pulsatile mass (which is seen in 25% of the patients) (12, 13). In the present case, the classical triad was not observed and the patient's clinical presentation also included melena and hematemesis.

OGD(oesophago-gastroduodenoscopy), conventional contrast CT, and angiography UGI endoscopy (14) are the commonest methods for PAEF diagnosis. However,

as the bleeding in ADF is generally located in the distal duodenum, endoscopy's sensitivity to ADF is relatively low. However, a UGI endoscopy should still be employed as the first diagnostic method in order to exclude other causative factors (15).

Technetium 99 m-labeled red blood cell nuclear scan can detect GI bleeding at a rate of 0.1–0.4 mL/min. Due to its non-invasive nature and higher sensitivity, compared with angiography, this test has been considered useful for screening and localization of bleeding, prior to the use of selective angiography (16).

The most valuable tool for the diagnosis of PAEF is a contrast-enhanced CT of the abdomen, which has a detection rate of 61% (12,13). However, as Saers and Scheltinga concluded, any negative endoscopy for GI hemorrhage associated with AA (aneurysmal aorta) should be further evaluated by CT (8). The effacement of the periaortic fat planes, the presence of periaortic fluid or air, and the thickening of the bowel loops adjacent to the aorta are the commonly observed findings (8).

In the presented case, the effacement of the fat planes between the aneurysm of left common iliac artery and the duodenum, and the thickening of the intestinal walls without active contrast extravasation from the aneurysm to the duodenum were findings that were suggestive of ADF.

Surgery is a definite approach for a patient assumed to have ADF, both for diagnosis and treatment. During exploration, following the control of the proximal and distal parts of the aorta, the fistula should be disconnected. Primary repair of the

aorta and the duodenum, resection of an aneurysm and reconstruction with grafts, in situ grafts, and an extra-anatomic bypass are several methods of different reconstructive techniques that may be used. In the presented case, aortic reconstruction with a graft was performed because of the absence of local infection and no complication was observed in the postoperative period.

### CONCLUSION

Primary ADF is a rare cause of GI bleeding. However, because of the high mortality and morbidity of delayed diagnosis, it must be considered as a cause of UGI bleeding in patients with UGI of unknown etiology. The most useful diagnostic methods for detecting PADF are an abdominal CT with intravenous contrast, endoscopy, and arteriography. Endoscopy is the first step in the diagnosis, while CT and arteriography may be used for confirmation. An emergency exploratory laparotomy should be done as soon as the diagnosis is suspected.

### Learning points:

- Although aortoduodenal fistula is a rare cause of GI bleeding, it should be considered in all cases of GI bleeding especially those with unknown etiology.
- Although imaging and endoscopic findings are the mainstay of diagnosis of AEF, in this case, there was no sign of bleeding in imaging and endoscopic findings. However, according to the patient's complaint of recurrent bleeding, decreased Hb level, and high suspicious of AEF, surgery was done, which played the main role of diagnosis in this case.

### CONFLICT OF INTEREST

The authors declare no conflict of interests related to this work.

### REFERENCES

1. Beuran M, Negoï I, Negoï RI, Hostiuç S, Paun S. Primary aortoduodenal fistula: first you should suspect it. *Braz J Cardiovasc Surg.* 2016;31:261-3.
2. Parry DJ, Waterworth A, Kessel D, Robertson I, Berridge DC, Scott DJ. Endovascular repair of an inflammatory abdominal aortic aneurysm complicated by aortoduodenal fistulation with an unusual presentation. *J Vasc Surg* 2001;33:874-9.
3. Girotti M, Kibbe MR. Aortoenteric Fistula and Visceral Artery Aneurysms. *Shackelford's Surg Aliment Tract* 2019 ;2:1040-55.
4. Gad A. Aortoduodenal fistula revisited. *Scand J Gastroenterol* 1989;24:97-100.
5. Busuttill SJ, Goldstone J, editors. Diagnosis and management of aortoenteric fistulas. *Semin Vasc Surg* 2001;14;:302-11.
6. Matsubara Y, Ohta T, Tatsumi R, Takasaka T, Sakamoto J, Sato R, et al. Two cases of aortoenteric fistula with gastrointestinal bleeding. *Nihon Shokakibyō Gakkai Zasshi* 2016;113:1887-93.
7. Richards CRN, McMurray R, Criman E, Rinehart S. Primary aortoduodenal fistula: a rare entity with lethal effects. *BMJ Case Rep* 2016;2016.
8. Saers S, Scheltinga M. Primary aortoenteric fistula. *Br J Surg* 2005;92:143-52.
9. Bissacco D, Freni L, Attisani L, Barbetta I, Dallatana R, Settembrini P. Unusual clinical presentation of primary aortoduodenal fistula. *Gastroenterology Rep* 2014;3:170-4.
10. Peck JJ, Eidemiller LR. Aortoenteric fistulas. *Arch Surg* 1992;127:1191-4.
11. Shehzad KN, Riaz A, Meyrick-Thomas J. Primary aortoduodenal fistula—a rare clinical entity. *JRSM Short Rep* 2010;1:7.
12. Mehmood RK, Mushtaq A, Andrew DR, Miller GA. Clinical presentation of a missed primary aorto-enteric fistula. *J Pak Med Assoc* 2007;57:616-8.
13. Lee W, Jung CM, Cho E-H, Ryu DR, Choi D, Kim J. Primary aortoenteric fistula to the sigmoid colon in association with intra-abdominal abscess. *Korean J Gastroenterol* 2014;63:239-43.
14. Ödemiş B, Başar Ö, Ertuğrul İ, İbiş M, Yüksel İ, Uçar E, et al. Detection of an aortoenteric fistula in a patient with intermittent bleeding. *Nat Clin Pract Gastroenterol Hepatol* 2008;5:226-30.
15. Guner A, Mentese U, Kece C, Kucuktulu U. A rare and forgotten diagnosis of gastrointestinal bleeding: primary aortoduodenal fistula. *BMJ Case Rep* 2013;2013:bcr2013008712.
16. Voeller G, Bunch G, Britt L. Use of technetium-labeled red blood cell scintigraphy in the detection and management of gastrointestinal hemorrhage. *Surgery* 1991;110:799-804.