

Intussusception in Pregnancy Caused by Ascariasis; Report of a Rare Case

Saeed Madani¹, Jamshid Vafaemanesh^{2,3,*}

¹ Department of Surgery, Qom University of Medical Sciences. Qom. Islamic Republic of Iran

² Clinical Research Disease Center. Qom University of Medical Sciences. Qom. Islamic Republic of Iran

³ Associate Professor, Internist, Gastroenterology and Hepatology Disease Research Center, Qom University of Medical Sciences, Qom, Islamic Republic of Iran

ABSTRACT

Ascariasis is a helminthic infection of humans caused by the nematode *Ascaris lumbricoides*. A 25-year-old woman with a gestational age of 17 weeks presented with acute onset abdominal pain with nausea and vomiting. Clinical and sonographic evaluations were supportive of acute bowel obstruction and small intestine intussusception due to *Ascaris lumbricoides* who undergone treatment during pregnancy. As intestinal obstruction is a rare but serious event in pregnancy, the importance of a high index of suspicion in the evaluation of abdominal pain in pregnancy is emphasized. The usefulness of ultrasonography in the early diagnosis of intussusception in pregnancy is discussed.

Keywords: Intussusception, *Ascaris lumbricoides*, Pregnancy

please cite this paper as:

Madani S, Vafaemanesh J. Intussusception in Pregnancy Caused by Ascariasis; Report of a Rare Case. *Govareh* 2020;24:247-249.

INTRODUCTION

The small bowel intussusception is an uncommon condition in adults, which occurs in 1-5% of cases of mechanical bowel obstruction (1). In adults, bowel intussusception usually occurs as an abnormal lead point in the intestine, which in half of the cases is caused by malignancy (1).

Intussusception is uncommon in adults and rarely reported in women with pregnancy. The incidence of intestinal obstruction in pregnancy has been reported

between 1: 68,000 to 1: 1500 deliveries (2-4).

Intestinal obstruction in pregnancy is associated with high maternal and perinatal mortality. In the series of Perdue and colleagues (5), maternal and perinatal mortality were 6% and 26%, respectively. The high maternal and perinatal mortality has been attributed to the difficulty in the early diagnosis of intestinal obstruction during pregnancy, because the classical symptoms of abdominal pain, vomiting, and constipation are common complaints and liable to be overlooked or passed off as normal discomforts of the pregnancy state (6).

Continued natural peristalsis of the intestine in the presence of this abnormal lead point leads to intussusception. In recent years, an increased prevalence of adult intussusception has been observed among patients with acquired immune deficiency syndrome (AIDS) (7). This is due to the increased incidence of infections and neoplastic lesions in the intestine of patients with AIDS including lymphoid hyperplasia, Kaposi sarcoma, and non-Hodgkin lymphoma. Intussusception, based on the etiology, is categorized into several groups: benign causes such as polyps, Meckel's diverticulum, and malignant causes, or idiopathic causes.

*Corresponding Author:

Jamshid Vafaemanesh, MD

Gastroenterology and Hepatology Disease Research Center, Shahid Beheshti Hospital, Shahid Beheshti Boulevard, Qom, Iran

Tel: + 98 253 6122949

Fax: + 98 253 6122945

Email: jvafaemanesh@yahoo.com

Received: 06 Aug. 2019

Edited: 14 Dec. 2019

Accepted: 15 Dec. 2019

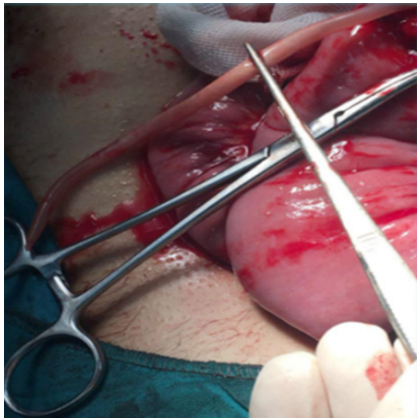


Fig.1: Removal of worms from the site of the intestinal incision after intussusception reduction

Ascaris lumbricoides (AL) is a common worm infection in the world causing major complications especially in developing countries (8). It has been stated that *Ascaris* is the most common worm contamination in the world, which has affected up to one-fourth of the world's population (9). Infection with AL can occur at all ages, but it often occurs in preschool children (10). Regarding the incidence of complications caused by this infection, bowel obstruction is the most common acute abdominal complication, which occurs in 50-65% of contamination cases in developing countries (7). In spite of the considerable mechanical bowel obstruction caused by AL, the incidence of intussusception caused by this disease is rare, and most patients who have been affected by this condition have been preschool children (11-12).

In this paper, we describe a pregnant woman with intussusception caused by AL who undergone treatment. Based on the obtained information, our patient is the first case reported with these characteristics.

CASE REPORT

The introduced patient was a 25-year-old woman with a gestational age of 17 weeks who referred to the healthcare center emergency due to severe abdominal pain. The abdominal pain of the patient had begun for several days before coming to the hospital's emergency room. The patient complained of nausea and vomiting, which had started for several days. In the examination, severe tenderness was detected in the left lower quadrant (LLQ) of the abdomen. In the laboratory tests, the patient had no notable abnormal results except for mild anemia. Abdominal ultrasonography was requested, in which intestinal intussusception was suspected. Concerning the severe abdominal pain, nausea, and vomiting, and abdominal examination representing acute bowel, the

patient was prepared for laparoscopy. After exploring the abdomen, intussusception was evident in the proximal small intestine, which was first reduced. Then, in examining and palpating the intestine, various *Ascaris* worms were detected, which were removed after resection of the intussuscepted part of the intestine (figure 1). Next, small intestine anastomosis was performed. After recovery and improvement, the patient received oral anti-parasite treatment with Pyrantelpamoate.

DISCUSSION

AL is an infection in humans, which is caused by this parasite living in the digestive system. This worm can cause different complications including pancreatitis, cholecystitis, bowel obstruction, and even bowel perforation (13). In adults, the most common manifestation is intermittent abdominal pain. However, sometimes relative bowel obstruction symptoms have been observed in some patients (7). The most common acute digestive complication of this worm is bowel obstruction, and the mortality rate caused by this complication in children younger than 10 years has been reported to be 5.7% (9). Relative bowel obstruction improves through conservative treatment such as bowel relaxation, administration of intravenous liquids, and decompressing the intestine through a nasogastric tube (14-15). However, when the mechanical obstruction remains unresolved, the worm mass acts as a lead point causing intestinal intussusception or volvulus (16). The important point is that *Ascaris* may secrete neurotoxins and anaphylatoxins causing small bowel spasm and inflammation. The complications of these toxins may also develop mechanical obstruction (17).

In cases when full obstruction does not respond to conservative treatment within 24-48 h, intussusception, volvulus, or corporation may occur, which require surgery.

Several reports have been published about special and rare complications caused by *ascaris*. Danny Darlington and colleagues reported a four-year-old child who had developed small bowel obstruction and ileus volvulus due to *Ascaris* infection (12). Another case was reported by Nikolic and co-workers. The patient was a five-year-old child who had developed small bowel intussusception (18). In the diagnosis of intussusception, simple abdominal radiography may indicate typical characteristics of small bowel obstruction. The diagnosis is often made based on abdominal computed tomography (CT) (7). In intussusception, the dilated bowel lumen may seem to have thickened, as it indicates two layers of the intestine (19). The "target sign" may be observed in the CT sagittal view, while in axial or coronal view, the development of intussusception is observed as a sausage-like mass (19).

Sharma and colleagues in reporting four cases of digestive manifestations of *Ascaris* considered sonography as a suitable diagnostic method for diagnosing ascariasis (20). Similarly, the initial diagnosis of intussusception in our patient was also made through sonography.

Pharmacotherapy leads to diminished morbidity caused by the worm. However, it may not completely prevent the relapse of the infection. The first-line therapy in children and adults (except for pregnant women) includes benzimidazoles such as albendazole or mebendazole. In pregnant women, due to the teratogenic effects of benzimidazoles in animals, pyrantel pamoate is recommended.

Note that in cases that intussusception and volvulus may cause necrosis of the bowel, resection of the intestine and primary anastomosis are recommended.

Due to high treatment response, replication of the stool test to examine the response to treatment is not recommended, possibly only for non-endemic regions where three months after the treatment stool test is recommended to check if the infection has been eliminated completely. In cases where the infection has not been resolved, the second time pharmacotherapy is recommended. In order to reduce the risk of infection relapse, stool test for other people living with the patient and treating them in case of infection are recommended.

CONCLUSION

Concerning the rare complications of parasitic and worm infections especially in less developed regions and in individuals with obstruction manifestations, paying attention to the causes of mechanical obstruction especially in those above 20 years of age and in all regions is important, and parasitic infections should be taken seriously into account for detecting the causes of obstruction.

ACKNOWLEDGEMENTS

We hereby thank dear professors and colleagues of the Clinical Research Development Unit of Shahid Beheshti Hospital who helped us.

CONFLICT OF INTEREST

The authors declare no conflict of interests related to this work.

REFERENCES

- Marinis A, Yiallourou A, Samanides L, Dafnios N, Anastasopoulos G, Vassiliou I, et al. Intussusception of the bowel in adults: a review. *World J Gastroenterol* 2009;15:407-11.
- Amias AG. Abdominal pain in pregnancy. In: Turnball A, Chamberlain G (eds). *Obstetrics Churchill Livingstone, Edinburgh* 1989;613-5.
- Davis MR, Bohon CJ. Intestinal obstruction in pregnancy. *Clin Obstet Gynecol* 1983;26:832-42.
- Dunselman GAJ. Intestinal obstruction in pregnancy. *Trop Doct* 1983;13:174-7.
- Roberts CA. Ogilvie's syndrome after caesarean delivery. *J Obstet Gynecol Neonatal Nurs* 2000;29:239 - 46.
- Badoe EA, Tandoh JKF. Acute intestinal obstruction. In: Badoe EA, Archampong EQ, Jaja MOA (eds) *Principles and practice of surgery including pathology in the tropics. Ghana Publishing Corporation* 1994;520 - 2.
- Gayer G, Zissin R, Apter S, Papa M, Hertz M. Pictorial review: adult intussusception--a CT diagnosis. *Br J Radiol* 2002;75:185-90.
- Chawla A, Patwardhan V, Maheshwari M. Primary ascariidial perforation of the small intestine: Sonographic diagnosis. *J Clin Ultrasound* 2003;31:211-3.
- Mukhopadhyay M. Biliary ascariasis in the Indian subcontinent: a study of 42 cases. *Saudi J Gastroenterol* 2009;15:121-4.
- Steinberg R, Davies J, Millar A. Unusual intestinal sequelae after operations for *ascaris lumbricoides* infestation. *Pediatr Surg Int* 2003;19:85-87.
- Darlington CD, Anitha GFS. Ascariidial Volvulus: An Uncommon Cause of Ileal Perforation. *Iran J Med Sci* 2018;43:432-5.
- Yetim I, Ozkan OV, Semerci E, Abanoz R. Rare cause of intestinal obstruction, *Ascaris lumbricoides* infestation: two case reports. *Cases J* 2009; 2:7970.
- Coskun A, Ozcan N, Durak AC, Tolu I, Gulec M, Turan C. Intestinal ascariasis as a cause of bowel obstruction in two patients: sonographic diagnosis. *J Clin Ultrasound* 1996, 24:326-8.
- de Silva NR, Guyatt HL, Bundy DA. Morbidity and mortality due to *ascaris*-induced intestinal obstruction. *Trans R Soc Trop Med Hyg* 1997; 91:31-6.
- Rode H, Cullis S, Millar A, Cremin B, Cywes S: Abdominal complications of *ascaris lumbricoides* in children. *Pediatr Surg Int* 1990;5:397-401.
- Cole GJ. Surgical manifestations of *ascaris lumbricoides* in the intestine. *Br J Surg* 1965; 52:444-7.
- Villamizar E, Méndez M, Bonilla E, Varon H, de Onatra S. *Ascaris lumbricoides* infestation as a cause of intestinal obstruction in children: experience with 87 cases. *J Pediatr Surg* 1996;31:201-5.
- Nikolić H, Palčevski G, Saina G, Peršić M. Chronic intussusception in children caused by *Ascaris lumbricoides*. *Wien Klin Wochenschr* 2011;123:294-6.
- Mullan CP, Siewert B, Eisenberg RL. Small bowel obstruction. *AJR Am J Roentgenol* 2012;198:W105.
- Sharma UK, Rauniyar RK, Bhatta N. Roundworm infestation presenting as acute abdomen in four cases--sonographic diagnosis. *Kathmandu Univ Med J (KUMJ)* 2005;3:87-90.