

Elham Ahmadi (DDS, MS)^{1,2}
Sasan Fallahi (MD)^{*3,4}
Mojgan Alaeddini (DDS)²
Masoomeh Hasani Tabatabaei
(DDS, MS)²

1- Shahrekord University of
Medical Sciences, Shahrekord, Iran.
2- Dental Research Center, Tehran
University of Medical Sciences,
Tehran, Iran.
3- Internal Medicine Division,
Baharloo Hospital, Tehran
University of Medical Sciences,
Tehran, Iran.
4- Rheumatology Research Center,
Tehran University of Medical
Sciences, Tehran, Iran.

*** Correspondence:**

Sasan Fallahi, Internal Medicine
Division, Baharloo Hospital,
Tehran University of Medical
Sciences, Tehran, Iran.

E-mail: drsfallahi@gmail.com
Tel: 00982155669300
Fax: 00982155648189

Received: 5 July 2012
Revised: 8 Aug 2012
Accepted: 13 Aug 2012

Severe dental caries as the first presenting clinical feature in primary Sjögren's syndrome

Abstract

Background: Sjögren's syndrome is an autoimmune syndrome involving the exocrine glands specially the salivary and lacrimal glands leading to xerostomia and xerophthalmia. This paper presents a case with primary Sjögren's syndrome that severe dental caries were the first clinical manifestation.

Case Presentation: A 42-year-old man was referred to the School of Dentistry, Tehran University of Medical Sciences due to unexplained severe dental decays. After systematic evaluation and consultation with the rheumatologist and the ophthalmologist, the diagnosis of primary Sjögren's syndrome was suggested and confirmed by serologic and histopathologic study.

Conclusion: Primary Sjögren's syndrome should be considered in the differential diagnosis of patients with early severe dental caries.

Keywords: Sjögren's syndrome, dental caries, Autoimmune

Caspian J Intern Med 2013; 4(3): 731-734

Sjögren's syndrome (SS) is a chronic systemic autoimmune disease by slow progression that affects principally the salivary and lacrimal glands leading to xerostomia and xerophthalmia. The involvement of the exocrine glands of the skin, pancreas, and vagina, respiratory and gastrointestinal systems has also been described. Extraglandular manifestations such as musculoskeletal, skin, renal, hematologic, neurologic, gastrointestinal and pulmonary involvement may coexist in some patients (1-4). Histopathological hallmark of the disease is persistent with progressive focal mononuclear cells infiltration, predominantly lymphocytes (2, 5). Primary SS patients have an enhanced risk of malignant lymphoma (non-Hodgkin's lymphoma), compared with the normal population (5). The etiopathogenesis of this syndrome is multifactorial and suggested infectious agents (Epstein- Barr virus, cytomegalovirus, parvovirus and retrovirus), immunologic changes in glandular homeostasis, humeral imbalance (6-12).

The extension of the pathological process beyond the lacrimal, salivary and other exocrine glands into peri-epithelial and extra-epithelial tissues can cause systemic manifestations that involve the lungs, kidneys and others. The appearance of the disease alone is called primary Sjögren's syndrome and the accompaniment with the other rheumatic diseases is named secondary Sjögren's syndrome (3). This case report explained a middle-aged man with the history of severe and unusual dental decays as the first troublesome feature of SS.

Case presentation

A 42-year-old man with multiple dental caries that compromised his esthetic appearance was referred to the postgraduate operative department of Tehran School of Dentistry in May 2011. His chief complaint (earliest symptom) was severe dental caries approximately 8 years ago.

Difficulty in swallowing dry food, continuous speaking, foreign body sensation and redness in eyes were the other problems which started about 2 years ago. Past medical history was unremarkable, besides consumption of nortriptyline 2 years ago for 1 year duration and also repeated restorative treatments for several carious teeth were done 8 years ago which eventually failed. The clinical oral exam by the dentist illustrated multiple dental caries (figure 1). No swelling and abnormalities were observed in the head and neck except red eyes and cracking of lips and oral corners. There was not any redness or thinning of oral mucosa. The primary treatment for dental health was the removal of acute caries and performing caries control process. The use of fluoride mouth wash, avoidance of cariogenic diet, chewing xylitol gum and good oral hygiene were recommended to him.

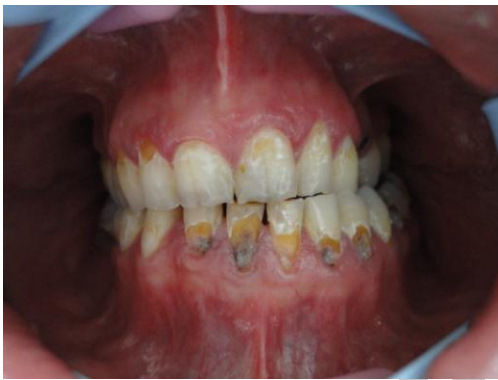

Figure 1. Severe dental decays in facial and cervical aspect of anterior mandibular teeth and cervical aspect of anterior maxillary teeth

Regarding the ophthalmic and oral manifestations and severe unusual dental caries even with good oral hygiene, systemic disease was suspected as the cause of the patient's problems. Therefore, consultation with rheumatologist and also ophthalmologist was performed. Systematic evaluation by rheumatologist revealed a history of intermittent arthralgia and also morning stiffness in peripheral joints without swelling. Ocular examination by the ophthalmologist showed conjunctivitis and mucosal threads and photophobia. With the request of the rheumatologist, Schirmer's test was done by ophthalmologist for measuring ocular tear. The result of the test established ocular dryness. So, the ocular manifestations were attributed to keratoconjunctivitis sicca. Considering the obtained findings include difficulty in swallowing dry foods, severe dental caries,

keratoconjunctivitis, subjective and objective manifestations of ocular dryness and also arthralgia, diagnosis of Sjögren's syndrome was suggested by rheumatologist. Blood chemistry tests, complete blood count and urinalysis were within the normal range, except mild lymphopenia (white blood cells: $4640/\text{mm}^3$, lymph: $1380/\text{mm}^3$). C-reactive protein (CRP) titer and ESR in first hour were normal. Abnormal immune serum tests included anti-RO (SSA): 178 RU/ml (normal: up to 20), RF titer: more than 150 IU/ml (normal: up to 15) and FANA: 1/1280 (normal: up to 1/80, pattern: fine speckled). The results of anti-LA (SSB), anti CCP, anti dsDNA and HIV (PCR) were negative.

The obtained biopsy from lip by otolaryngologist confirmed chronic sialadenitis in minor salivary glands. Histopathology assessment by the oral pathologist and also the physician pathologist clarified infiltration of lymphocytes compatible with Sjögren's syndrome (foci score: 2) (figure 2). Treatment was designed to relieve symptoms. Artificial tear and Liposic eye gel (as a lubricant) were prescribed by ophthalmologist for ocular symptoms. For arthralgia and morning stiffness, hydroxychloroquine (HCQ) 400 mg/day and prednisolone 5 mg/day were prescribed by the rheumatologist. For oral symptoms, the use of artificial saliva and fluoride mouthwash, drinking plentiful water and watery foods, chewing xylitol gum and good oral hygiene were recommended by the dentist and definitive resin composite restorations were performed. A dental health follow-up plan was also designed for him. A follow up of the patient after two months revealed moderate improvement of clinical manifestations.

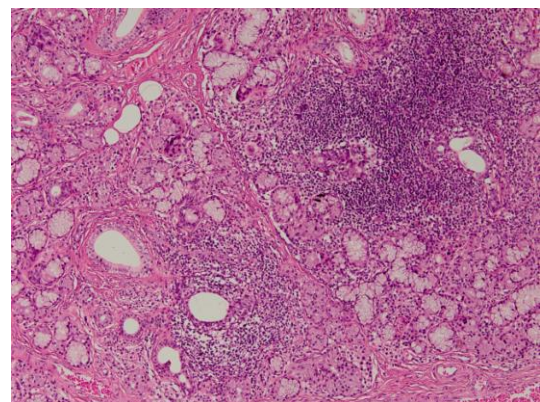


Figure 2. Histopathology study revealed at least two foci of lymphocytes, a cluster of at least 50 lymphocytes in 4 mm^2 , in minor salivary glands of patient's lip (focus score: 2)

Discussion

We presented a case of primary Sjögren's syndrome with early severe dental caries in which his disease was diagnosed with several years delay. Xerostomia is the main symptom of SS but some patients (like our case) may not complain about it. The other symptoms that often occur along with xerostomia include frequent thirst, burning sensation on the tongue, red and raw tongue, difficulty swallowing, taste problems, sore throat, hoarseness, problems with speech, dry and cracked lips, dental problems increment such as cavities and periodontal disease (1, 6). Our case had difficulty swallowing, dry and cracked lips, problems in continuous speech and severe early dental caries.

Common therapeutic management is based on controlling sicca features using topical and cholinergic agents. Extraglandular features are controlled with glucocorticoids and immunosuppressive drugs. Anti-tumor necrosis factor agents have not shown clinical efficacy. No significant improvement in sicca outcomes were seen for oral prednisone or hydroxychloroquine (13). But in an open study, hydroxychloroquine which increases the PH of endosomes and thus, decreases type 1 IFN secretion has been found effective for the treatment of decreasing saliva (14). Therefore, we used it for sicca features in our case, as well.

Concerning the history, characteristic features and diagnostic approach of the presented case may guide clinicians through some viewpoints and views in order to diagnose SS in early stages.

1) Some oral manifestations may occur before the progression of symptomatic xerostomia. The lack of knowledge about these features (such as severe dental caries) may lead to the underestimation or the later diagnosis of SS. In fact, changes in saliva biochemistry before the decrease of saliva, changes in pH and buffer capacity of saliva and also reduction in re-mineralization activity and antimicrobial properties of saliva may lead to early dental loss and unexplained early dental decays as showed by others (1, 3).

2) The dentist or physician should be suspicious to Sjögren's syndrome when severe and early dental caries (onset before 40 years old, especially in cervical aspect of teeth) or hypo-salivation accompanied with other comorbidities pertaining to this syndrome without history of xerostomia-inducing drugs, poor oral hygiene condition or incorrect dietary regimen and also when multiple dental decays reoccur in a short period of time even after repeated restorations.

3) Interdisciplinary approach for diagnostic and therapeutic management with cooperation of dentist, rheumatologist, ophthalmologist, otolaryngologist and pathologist, who will otherwise focus only on those symptoms that encompass their areas of expertise, can get a comprehensive image of the patient, leading to the earlier diagnosis and treatment of SS before irreversible destructive changes in salivary glands and other glandular or extraglandular complications.

Acknowledgments

The authors would like to thank Dr Hamed Safari for his cooperation in the dental restoration of the patient.

Conflict of interest: The authors declare no conflict of interest.

References

1. Carsons S. A review and update of Sjögren's syndrome: manifestations, diagnosis, and treatment. *Am J Manag Care* 2001; 7: S433-43.
2. Soyfoo MS, Steinfeld S, Delporte C. Usefulness of mouse models to study the pathogenesis of Sjogren's syndrome. *Oral Dis* 2007;13: 366-75.
3. Mignogna MD, Fedele S, Lo Russo L, Lo Muzio L, Wolff A. Sjogren's syndrome: the diagnostic potential of early oral manifestations preceding hyposalivation / xerostomia. *J Oral Pathol Med* 2005; 34:1-6.
4. Kassan S, Moutsopoulos H. Clinical Manifestations and Early Diagnosis of Sjo`gren Syndrome. *Arch Intern Med* 2004;164:1275-84.
5. Hayashi T. Dysfunction of Lacrimal and Salivary Glands in Sj`ogren's Syndrome: Nonimmunologic Injury in Preinflammatory Phase and Mouse Model. *J Biomed Biotechnol* 2011; 2011: 407031.
6. Gomes PS, Juodzbaly G, Fernandes MH, Guobis Z. Advances in the Aetiopathogenesis of Sjögren's Syndrome: a Literature Review *J Oral Maxillofac Res* 2012; 3: 1-11.
7. Bolstad AI, Wassmuth R, Haga HJ, Jonsson R. HLA markers and clinical characteristics in Caucasians with primary Sjogren's syndrome. *J Rheumatol* 2001; 28: 1554-62.

8. Mariette X, Gottenberg JE. Pathogenesis of Sjögren's syndrome and therapeutic consequences. *Curr Opin Rheumatol* 2010; 22: 471-7.
9. Nordmark G, Kristjansdottir G, Theander E, et al. Association of EBF1, FAM167A(C8orf13)-BLK and TNFSF4 gene variants with primary Sjögren's syndrome. *Genes Immun* 2011; 12: 100-9.
10. Appel S, Le Hellard S, Bruland O, et al. Potential association of muscarinic receptor 3 gene variants with primary Sjogren's syndrome. *Ann Rheum Dis* 2011; 70: 1327-9.
11. Jonsson R, Vogelsang P, Volchenkov R, et al. The complexity of Sjögren's syndrome: novel aspects on pathogenesis. *Immunol Lett* 2011; 141: 1-9.
12. Voulgarelis M, Tzioufas AG. Pathogenetic mechanisms in the initiation and perpetuation of Sjögren's syndrome. *Nat Rev Rheumatol* 2010; 6: 529-37.
13. Ramos-Casals M, Tzioufas AG, Stone JH, Siso A, Bosch X. Treatment of primary Sjogren syndrome: a systematic review. *JAMA* 2010; 304: 452-60.
14. Rihl M, Ulbricht K, Schmidt R, Witte T. Treatment of sicca symptoms with hydroxychloroquine in patients with Sjogren's syndrome. *Rheumatology (Oxford)* 2009; 48: 796-9.

Archive of SID