



Spontaneous Remission of Encephalopathy Associated with Autoimmune Thyroid Disease in a Patient with Graves' Disease: A Rare Occurrence in a Rare Clinical Picture

Yagoub Elfaki¹, Donal O'Shea¹, Gianluca Tamagno^{1*}

¹ Department of Endocrinology and Diabetes Mellitus, St Vincent's University Hospital, University College Dublin, Dublin, Ireland

ARTICLE INFO

Article type:
Case Report

Article history:
Received: 03 Jul 2011
Revised: 25 Aug 2011
Accepted: 27 Sep 2011

Keywords:
Encephalopathy
Autoimmune
Thyroid Disease
Graves' Disease

ABSTRACT

Encephalopathy associated with autoimmune thyroid disease (EAATD) is a rare condition that may occur in patients with an autoimmune thyroid disease. The clinical presentation of EAATD is characterized by a variety of neurological and/or psychiatric alterations and can show up with focal signs secondary to stroke-like events or generalized symptoms. From a nosological, epidemiological, and diagnostic point of view, EAATD still remains a controversial disorder. Indeed, a widely accepted definition of EAATD has not yet been established, and the diagnosis of this condition is often difficult because of the heterogeneous clinical presentation, the number of possible non-specific manifestations, and poorly defined diagnostic criteria. These factors may inevitably affect the exact estimation of the prevalence of EAATD. From a clinical perspective, the course of EAATD is variable and ranges from response, often dramatic and rapid, to corticosteroids to no or partial response and requirement of other immunosuppressive treatments. Occasionally, spontaneous remission or adverse outcomes have also been reported. Here, we describe the case of a 52-year-old woman who presented with right facial and upper limb numbness and perioral tingling. The laboratory, radiological, and electrophysiological investigations revealed no relevant abnormalities from a neurological point of view. The investigations carried out during hospital admission incidentally disclosed a clinical picture compatible with Graves' disease, including elevated levels of antithyroid antibodies. However, the cause of her stroke-like episode remained unclear, and the reported symptoms disappeared spontaneously in approximately 10 days. Finally, EAATD characterized by the spontaneous remission of the symptoms was diagnosed, and the patient did not show any relapse or reoccurrence of EAATD thereafter. This intriguing case allows us to focus on and discuss some of the most debatable aspects of EAATD, including its definition, diagnosis, and management.

Copyright © 2011 Kowsar M. P. Co. All rights reserved.

► Implication for health policy/practice/research/medical education:

This report discusses some of the most relevant clinical aspects of encephalopathy associated with autoimmune thyroid disease, with a particular regard to the definition, the diagnosis, and the management of such a condition.

► Please cite this paper as:

Elfaki Y, O'Shea D, Tamagno G. Spontaneous Remission of Encephalopathy Associated with Autoimmune Thyroid Disease in a Patient with Graves' Disease: A Rare Occurrence in a Rare Clinical Picture. *Int J Endocrinol Metab.* 2011;9(4):373-6. DOI: 10.5812/Kowsar.1726913X.3183

1. Introduction

Encephalopathy associated with autoimmune thyroid disease (EAATD) is a rare condition characterized by the acute or subacute onset of neurological and/or psychiatric symptoms, a relapsing or remitting course, and in the majority of the cases, a dramatic response to corticosteroid therapy (1). However, adverse outcomes or spontaneous remission have also been reported (2). EAATD appears

* Corresponding author: Gianluca Tamagno, Department of Endocrinology and Diabetes Mellitus, St Vincent's University Hospital, University College Dublin, 4 Elm Park, Dublin, Ireland. Tel: +35-312214407. Fax: +35-312094981, E-mail: gianlucatamagno@tiscali.it

DOI: 10.5812/Kowsar.1726913X.3183

Copyright ©2011 Kowsar M.P.Co. All rights reserved.

to have two distinctive clinical subtypes. A vasculitic subtype that typically presents with stroke-like episodes and a generalized subtype that presents with diffuse encephalopathy symptoms, including altered consciousness, cognitive abnormalities, seizures, gait impairment, headache, affective disorders or other psychiatric changes, and inflammatory signs of encephalitis or meningitis (1). In a single center prospective study, the estimated prevalence of EAATD was reported to be 2.1/100,000 (2). EAATD might potentially affect all patients with autoimmune thyroid disease, irrespective of the nature of the disease. Almost all EAATD patients are affected by Hashimoto's thyroiditis (HT), while a few have Graves' disease (GD) (3). Although the mechanism of EAATD is unknown, the bulk of evidence points to autoimmune vasculitis or other immune-mediated processes. The pathogenesis of EAATD is thought to involve focal or global brain hypoperfusion, cerebral tissue-specific autoimmunity with or without demyelination, and brain edema leading to neuronal dysfunction (1, 4-6). We present and discuss the case of a patient with GD, who developed EAATD symptoms with subsequent spontaneous recovery. This rare

but intriguing case highlights the importance of including EAATD in the differential diagnosis of neurological or psychiatric symptoms and excluding response to corticosteroids from the mandatory criteria for diagnosing EAATD.

2. Case Report

A 52-year-old woman was admitted to our institution following the appearance of right facial and right upper limb numbness and perioral tingling. Her medical history was significant only for arterial hypertension, which was controlled well with amlodipine 5 mg taken once daily. No history of other cardiovascular or cerebrovascular risk factors was present. A complete neurological examination yielded no abnormality apart from the reported sensory alterations. Her cognitive function and intellectual performance were normal. The findings of motor and sensory examinations were normal. Physical examination of the neck showed an enlarged and homogenous thyroid gland, and the findings of ophthalmological examination were unremarkable. The patient underwent a brain as computed tomography (CT), which

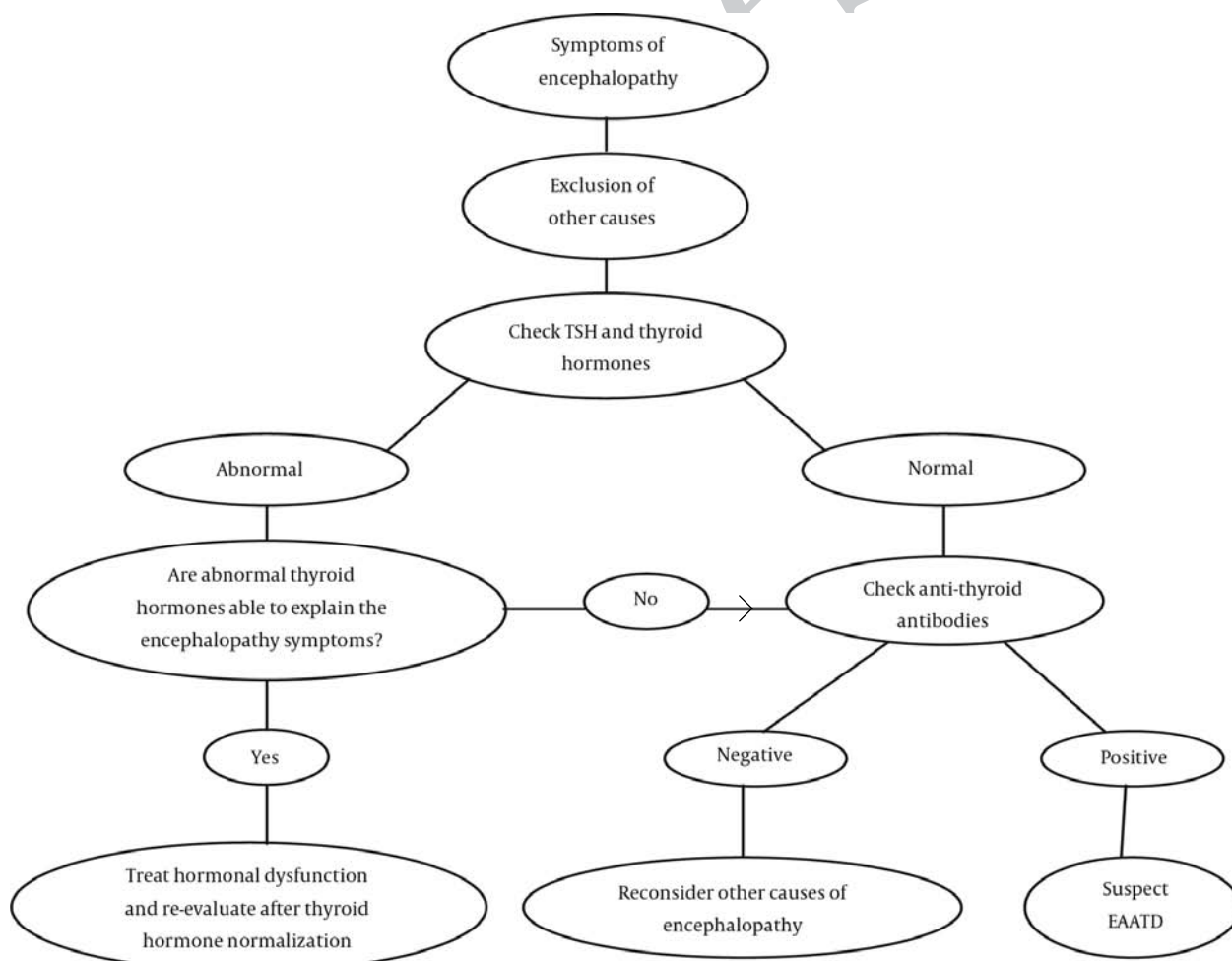


Figure 1. Proposed Flow-Chart for the First-Line Diagnostic Approach to a Patient With Neurological or Psychiatric Symptoms Compatible With EAATD. Further laboratory or radiological tests can help to confirm the diagnosis of EAATD.

revealed no abnormalities. Brain magnetic resonance imaging (MRI) scan showed minimal non-specific changes at the periventricular and subcortical levels. A Doppler ultrasonography (US) of the carotid arteries showed no significant stenosis. The routine biochemical and hematological profile was normal. Free T4 (27.3 pmol/L; normal range: 12.0–22.0) was slightly elevated, total T3 (2.59 nmol/L; normal range: 1.3–3.1) was normal, and there was a decrease in the TSH (< 0.02 mIU/L; normal range: 0.27–4.2) level. The levels of anti-TSH receptor antibodies (> 40.0 IU/L; normal range: < 1.5) and the anti-thyroid peroxidase antibodies (139 IU/mL; normal range: < 49) were also high. The patient underwent thyroid scintigraphy, which revealed a diffuse toxic thyroid compatible with GD, thereby corroborating the results of the laboratory tests. However, the patient had no recent or concomitant symptoms of hyperthyroidism. Cerebrospinal fluid (CSF) analysis was not performed. Despite a fairly exhaustive investigation under the guidance of the neurology team of our institution, a definite cause of the neurological symptoms was not identified. An incidental diagnosis of GD was made. Further, EAATD was suspected. However, considering the lack of a clinical worsening overtime, we did not prescribe any specific treatment for the neurological issue. Treatment with carbimazole 5 mg once daily was commenced and since the patient did not manifest any specific symptom of hyperthyroidism, beta-blockers were not administered. As a prophylactic measure, treatment with acetylsalicylic acid 75 mg once daily was started, and the amlodipine daily dose was increased to 10 mg daily for improving further the blood pressure control. The neurological symptoms remained unchanged for approximately 10 days and then spontaneously disappeared. Electroencephalogram (EEG) performed after the resolution of the neurological symptoms did not show any abnormality. EAATD with spontaneous remission of the symptoms was finally diagnosed. After discharge, the patient has been regularly followed-up with evaluation of the neurological and endocrine signs and symptoms, and the patient has remained free from relapse or recurrence of the neurological symptoms (follow-up period: 10 months). She has also remained completely asymptomatic from a thyroid-related point of view. During the follow-up period, her TSH and thyroid hormone levels improved slowly, but progressively, and were eventually normal.

3. Discussion

We present an intriguing case of EAATD in a patient with GD, which was incidentally diagnosed after the sudden onset of right-sided facial sensory alterations which spontaneously recovered over approximately 10 days. We believed that the appearance of neurological symptoms in the absence of a clear cause was consistent with an acute onset of EAATD. The diagnosis of EAATD is anything but straightforward and easy for the physician, because no specific laboratory, radiological, or electrophysiological disease markers have been defined thus far. A potentially useful marker

for EAATD is the antibody against the amino-terminal end of the enzyme alpha-enolase (7), but a pathogenic role of this autoantibody remains unclear. Since alpha-enolase is expressed by endothelial cells, it is believed that this antibody might mediate a vasculitic process. CSF analysis is abnormal in approximately 80% of the patients (8) and often facilitates the exclusion of other causes of encephalopathy, which is an important diagnostic step in patients clinically suspected of having EAATD. However, the CSF findings in EAATD are usually not specific. In the present case, CSF analysis was deemed unnecessary because of the benign evolution of the neurological symptoms. A number of studies have shown that EEG abnormalities are detected in many EAATD patients; these abnormalities are often represented by non-specific slowing of the background electric activity or, more rarely, focal spikes, sharp waves, triphasic waves, or frontal intermittent rhythmic delta activity (1, 3, 9, 10). The MRI findings in patients with EAATD are usually normal, except for non-specific signal abnormalities in the white matter in some cases (1, 3). In a few cases, the abnormal radiological findings disappear after successful immunosuppressive treatment (11, 12). The case illustrated above shows that EAATD may also occur in patients with GD, and not only in patients with HT, as previously hypothesized. This old and inadequate hypothesis determined the misleading use of Hashimoto's encephalopathy as the denomination for such a condition. We think that current evidence supports the choice of a more comprehensive definition, like EAATD, over such narrow one. Moreover, this case report supports the notion that EAATD symptoms can occasionally disappear spontaneously without any immunosuppressive treatment, including corticosteroids, as reported previously (13, 14). Reports thus far indicate that a minority of patients with EAATD do not respond or respond only partially to corticosteroids (3, 15). Thus, we believe that corticosteroid responsiveness cannot be considered as a mandatory criterion for establishing the diagnosis of EAATD. This indicates the need for a careful redefinition of the diagnostic criteria of EAATD, or maybe just a definition, since widely accepted diagnostic criteria have yet to be established (16). Currently, there is a lack of definite consensus on how to diagnose EAATD. However, according to the literature (1), the following criteria have been considered useful for the diagnosis of EAATD: (a) acute or sub-acute onset of neurological and/or psychiatric symptoms; (b) exclusion of other possible causes of encephalopathy; (c) association with an autoimmune thyroid disease with positive antithyroid antibodies in the blood and/or CSF; and (d) thyroid hormone changes unable to justify the neurological or psychiatric symptoms. Elevated protein concentration in the CSF, non-specific EEG abnormalities, and positive antibodies against the amino-terminal end of the enzyme alpha-enolase can further support the diagnosis of EAATD. We believe that response to corticosteroids can be enlisted as a notable but not mandatory criterion for the diagnosis of EAATD, because some patients with EAATD could be non-responders and some patients with encephalopathy due to other causes (i.e., inflam-

matory encephalopathies) could respond to corticosteroid treatment. Since a broad consensus has not been arrived at regarding the diagnostic criteria for EAATD, we propose a straightforward flow-chart depicting the approach to a patient with neurological or psychiatric symptoms consistent with EAATD (Figure 1). This could be useful for physicians encountering patients who present with unexplained neurological or psychiatric symptoms and are suspected of having EAATD. In the present case, the slightly elevated levels of thyroid hormones could not explain per se the neurological symptoms and, later, the remission of the neurological symptoms was not related to the anti thyroid treatment administered or the thyroid hormone normalization. The other possible causes of the neurological symptoms were excluded or considered to be extremely unlikely on basis of the clinical assessment and the specialist's judgment. Indeed, the presentation and evolution of the symptoms in this patient could be compatible with an ischemic event; it is possible that EAATD may have resulted in a vasculitic process, thereby providing a cerebral ischemic picture (12, 17). This possibility is particularly relevant in cases where the risk factors for cerebrovascular disease are otherwise poor. However, all comments remain speculative at this stage since no definitive proof was available, and the final diagnosis was inevitably impaired by a certain degree of uncertainty. In conclusion, this illustrative case highlights EAATD as a rare condition potentially affecting patients with an autoimmune thyroid disease, irrespective of the nature of the disease. Moreover, since the spontaneous remission of EAATD is occasionally possible, we think that response to corticosteroids should not be listed among the mandatory criteria for diagnosing EAATD. We believe that there is still a need for the development of an internationally acceptable and multidisciplinary characterization of EAATD, with particular regard to the definition, diagnosis, and management of this condition. Unfortunately, this is still lacking to date and the current clinical evidence is based solely on the report of single patients or small series of patients.

Acknowledgments

None declared.

Financial Disclosure

The authors have no financial supports to disclose in relationship to this manuscript.

Funding/Support

None declared.

References

1. Tamagno G, Federspil G, Murialdo G. Clinical and diagnostic aspects of encephalopathy associated with autoimmune thyroid disease (or Hashimoto's encephalopathy). *Intern Emerg Med*. 2006;**1**(1):15-23.
2. Ferracci F, Bertiato G, Moretto G. Hashimoto's encephalopathy: epidemiologic data and pathogenetic considerations. *J Neurol Sci*. 2004;**217**(2):165-8.
3. Tamagno G, Celik Y, Simo R, Dihne M, Kimura K, Gelosa G, et al. Encephalopathy associated with autoimmune thyroid disease in patients with Graves' disease: clinical manifestations, follow-up, and outcomes. *BMC Neurol*. 2010;**10**:27.
4. Castillo P, Woodruff B, Caselli R, Vernino S, Lucchinetti C, Swanson J, et al. Steroid-responsive encephalopathy associated with autoimmune thyroiditis. *Arch Neurol*. 2006;**63**(2):197-202.
5. Forchetti CM, Katsamakis G, Garron DC. Autoimmune thyroiditis and a rapidly progressive dementia: global hypoperfusion on SPECT scanning suggests a possible mechanism. *Neurology*. 1997;**49**(2):623-6.
6. Shaw PJ, Walls TJ, Newman PK, Cleland PG, Cartledge NE. Hashimoto's encephalopathy: a steroid-responsive disorder associated with high anti-thyroid antibody titers—report of 5 cases. *Neurology*. 1991;**41**(2):228-33.
7. Fujii A, Yoneda M, Ito T, Yamamura O, Satomi S, Higa H, et al. Autoantibodies against the amino terminal of alpha-enolase are a useful diagnostic marker of Hashimoto's encephalopathy. *J Neuroimmunol*. 2005;**162**(1-2):130-6.
8. Kothbauer-Margreiter I, Sturzenegger M, Komor J, Baumgartner R, Hess CW. Encephalopathy associated with Hashimoto thyroiditis: diagnosis and treatment. *J Neurol*. 1996;**243**(8):585-93.
9. Kaplan PW, Rossetti AO. EEG patterns and imaging correlations in encephalopathy: encephalopathy part II. *J Clin Neurophysiol*. 2011;**28**(3):233-51.
10. Rodriguez AJ, Jicha GA, Steeves TD, Benarroch EE, Westmoreland BE. EEG changes in a patient with steroid-responsive encephalopathy associated with antibodies to thyroperoxidase (SREAT, Hashimoto's encephalopathy). *J Clin Neurophysiol*. 2006;**23**(4):371-3.
11. Chang T, Riffsy MT, Gunaratne PS. Hashimoto encephalopathy: clinical and MRI improvement following high-dose corticosteroid therapy. *Neurologist*. 2010;**16**(6):394-6.
12. Utku U, Asil T, Celik Y, Tucer D. Reversible MR angiographic findings in a patient with autoimmune Graves disease. *AJNR Am J Neuroradiol*. 2004;**25**(9):1541-3.
13. Katoh N, Yoshida T, Shimojima Y, Gono T, Matsuda M, Yoneda M, et al. An 85-year-old case with Hashimoto's encephalopathy, showing spontaneous complete remission. *Intern Med*. 2007;**46**(18):1613-6.
14. Li L, Zheng FP, Wang G, Li H. Recurrent Hashimoto's encephalopathy, showing spontaneous remission: a case report. *Intern Med*. 2011;**50**(12):1309-12.
15. Mijajlovic M, Mirkovic M, Dackovic J, Zidverc-Trajkovic J, Sternic N. Clinical manifestations, diagnostic criteria and therapy of Hashimoto's encephalopathy: report of two cases. *J Neurol Sci*. 2010;**288**(1-2):194-6.
16. Tamagno G, Gaoatswe G. Time for the endocrinologists to expand their awareness of and contribution to the diagnosis and management of encephalopathy associated with autoimmune thyroid disease. *Hormones (Athens)*. 2011;**10**(1):36-8.
17. Becker H, Hofmann M, von Einsiedel H, Conrad B, Sander D. [Circumscribed vasculitis with posterior infarct in Hashimoto encephalopathy]. *Nervenarzt*. 2002;**73**(4):376-9.