

Original Article**Apoptotic Effect of Organophosphorus Insecticide Diazinon on Rat Ovary and Protective Effect of Vitamin E**

Zinat Sargazi¹, Mohammad Reza Nikravesh^{*2}, Mehdi Jalali², Hamid Reza Sadeghnia³, Fatemeh Rahimi Anbarkeh⁴

Received: 22.08.2015

Accepted: 03.10.2015

ABSTRACT

Background: Diazinon (DZN) is an organophosphate insecticide widely utilized in agriculture all over the world and causes many negative effects on plants and animal species, especially on human. The aim of present study was to evaluate the effects of DZN on apoptosis of ovarian follicles in adult rats and to assess the protective role of vit E.

Methods: Thirty adult female Wistar rats were divided into five groups: control group (without any intervention), sham group (received only pure olive oil, as solvent), experimental group 1 (DZN+olive oil, 60 mg/kg), experimental group 2 (vit E, 200 mg/kg), and experimental group 3 (DZN+vit E, the same dosage). All drugs were injected intraperitoneally, except vit E administrated by gavage. The animals were scarified after two weeks and left ovary was used to measure apoptosis of ovarian follicles.

Results: The number apoptotic cells experimental group 1 increased significantly in contrast control group in secondary and graffian follicles ($P < 0.001$). Administration vit E plus DZN, significantly reduced apoptotic cells compared to DZN group ($P < 0.001$).

Conclusion: DZN-induced apoptosis in secondary and graffian follicles and vit E inhibited apoptosis induced by DZN. Vit E might have a protective effect on DZN-induced ovarian toxicity.

Keywords: Apoptosis, Diazinon, Ovary, Vitamin E.

IJT 2016 (2):37-44

INTRODUCTION

Pesticides and herbicides are resistant and hazardous chemical compounds that their applications are commonly in agriculture. Among them, organophosphates pesticides are generally used as insecticides [1]. They are a main group of chemical insecticides, which their use has been raising worldwide, especially in developing countries [2]. Organophosphorus compounds can be highly toxic for animals, especially vertebrate animals and human kind [1, 3]. They have been utilized in agriculture, industry, farming, medicine, animal keeping and households to kill insects, nematodes fungi, worms and weeds for five decades [4-7]. Unfortunately, the indiscriminate use of these products harms the environment, animals, plants, soil, and water and creates persistence to them,

which is an increasing concern [8, 9]. OP residues have been detected in soil, water, vegetables and other foods [7, 9].

These pesticides are absorbed by body through the skin and mucous membranes via oral cavity and inhalation [10]. Organophosphate insecticides negatively affect several organs of the body including liver, kidneys, pancreas, immune system, urinary and reproductive systems and cardiac and vascular walls, and induce hematological and biochemical changes [1, 11-13].

One of the affected organs is the ovary, which has a key role in reproductive function by synthesizing hormones and producing oocyte [14, 15]. DZN (0, 0 -diethyl-0-[2-isopropyl-6-methyl-4-pyrimidinyl] phosphorothioate) is a commonly used organophosphorous insecticide. The main mechanism of action of DZN is acetyl-

1. Department of Basic Sciences, Torbat Heydariyeh University of Medical sciences, Torbat Heydariyeh, Iran.

2. Department of Anatomy and cell biology, Mashhad University of Medical Sciences, Mashhad, Iran.

3. Department of Pharmacology, Mashhad University of Medical Sciences, Mashhad, Iran.

4. Department of Anatomy and cell biology, Mashhad University of Medical Sciences, Mashhad, Iran.

*Corresponding Author: E-mail: nikraveshmr@mums.ac.ir

cholinesterase (AChE) enzyme inhibition activity [5, 9].

Additionally, it can increase formation of free radicals and so induce oxidative stress and tissue lipid peroxidation in mammals and other organisms [16, 17]. Chronic poisoning with OPS is more than just acetyl-cholinesterase (AChE) inhibition and is related to OPS ability to induce apoptosis through activating internal and external pathways [18]. Several studies had reported the induction of apoptosis in various organs through activating caspase pathways [19, 20]. In normal conditions, there is a fine balance between ROS and antioxidant enzymes in different tissues including the ovary and testis [21]. ROS affect multiple physiological procedures from oocyte maturation to fertilization. Although ROS may have a regulatory role in oocyte maturation, folliculogenesis, luteolysis and ovarian steroidogenesis, it can cause tissue damage as lipid peroxidation when it is produced in large amount [22-25].

Antioxidants, on the other hand, are scavengers that detoxify excessive ROS and play a key role in maintaining oxidant/antioxidant balance in the body. Antioxidants are of two types: enzymatic and nonenzymatic [17].

Vit E (α -tocopherol) is known as a fat soluble antioxidant and acts as an antioxidant in cells by protecting cellular membranes and lipoproteins from peroxidation. In addition, several studies have shown that Vit E inhibits free radical formation and so decreases lipid peroxidation in biological systems [7].

Furthermore, antioxidants have substantial role in the female reproductive system [26]. The aim of this study was to investigate the effects of DZN, an organophosphate insecticide, on apoptosis of ovarian follicles in adult rats and evaluate the protective role of vit E in rat ovarian tissue.

MATERIALS AND METHODS

Animals

Thirty adult female Wistar rats were obtained from the Animal Lab of Mashhad University of Medical Sciences, Mashhad, Iran. The kind of this study was experimental and was done in 2014. The animals were divided into five groups: control (without any intervention), sham group (received only pure olive oil, as solvent), experimental group 1 (DZN+olive oil, 60 mg/kg), and experimental group 2 (DZN+vit E,

with the same dose), experimental group 3 (Vit E, 200 mg/kg). Olive oil was used as solvent [27-32]. DZN and solvent were administrated by intraperitoneal injection and vit E was given by gavage. All of these animals were scarified after two weeks and left ovary was used to measure apoptosis and proliferation of ovarian follicles. The rats were fed a standard chow and water ad libitum, and exposed to a 12-h light/dark cycle, at a temperature of 22 °C. All the experimental protocols were approved by the Ethical Committee of Mashhad University of Medical Science.

Histological Analysis

Tissue samples were fixed in paraformaldehyde (4%) solved in phosphate buffer saline (PBS) (100 mL) for 14 to 16 h, dehydrated in ascending grades (20%-100%) of alcohol for 45 min to 1 h, then cleared in alcohol-xylene (50:50) and xylene (three times). Tissues were then fixed in paraffin; samples were cut in 5 μ m sections with a microtome and placed on poly L-lysine slides. Slides were deparaffinized and hydrated in descending grades of alcohol. Tissues were analyzed by the TUNEL technique and viewed with an optical microscope.

TUNEL Immunohistochemical Technique

Apoptosis in tissue was done by TUNEL peroxidase kit (In situ cell death detection Kit-POD, Roche, Germany). The sections were deparaffinized, hydrated and then incubated for 15 min in room humid temperature with 20 g/mL K protein kinase. The slides were then incubated with reactive TUNEL mixture consisting terminal deoxynucleotidyl transferase Enzyme Solution 450 μ L, Label Solution 50 μ L) for sixty minutes in temperature of 37 °C. Then DUTP (Deoxyuridine Triphosphate) conjugated by dioxigenperoxidase was added and the slides were covered with a lid. Afterwards dioxigen and hydrogen peroxide (Converter-POD) was added to the samples. The slides were incubated for 30 min and DAB (Diaminobenzidine) was added (DAB powder 6mg, PBS 10mL, H₂O₂ 3% 10 μ L). The slides were stained by hematoxylin. Apoptotic cells will appear in brown [33-37].

Stereology Technique

Quantification of Apoptotic Cells

The sections were scanned and were photographed using a light microscope (UPlan

FI, Japan), and images were transferred to a computer using a high-resolution camera (BX51, Japan). Morphometrical methods were used to count TUNEL positive cells per unit area in ovary. The numbers of TUNEL positive cells were counted using grades Unbiased frames. The mean number of TUNEL positive cells per unit area (NA) in different types of ovarian follicles in different groups of rats was calculated using the following formula [38]:

$$\frac{\Sigma Q}{a/f \cdot \Sigma P}$$

In this formula, “ΣQ” is the sum of counted particles appeared in sections, “a/f” is the area associated with each frame, and “ΣP” is the sum of frame associated points hitting space.

Statistical Analysis

Data were analyzed using SPSS 16 software (Chicago, IL, USA). Results are expressed as mean±SD. Statistical analysis was performed with ONE-WAY ANOVA followed by Tukey test to compare the differences between means. Differences were considered statistically significant at $P<0.05$.

RESULTS

Effect of DZN and Vitamin E on Apoptosis Cell Density in Ovarian Follicles

The results based on the types of ovarian follicles are as follows:

Primordial Follicles

These follicles in all of 5 groups of control, sham, experimental group1, experimental group 2 and vit E treated group, were free of apoptotic cells, however TUNEL-positive cells were observed in some primordial follicles 1 or 2.

Primary Follicles

In the majority of primary follicles almost all the cells were TUNEL positive in all 5 groups.

Secondary Follicles

This study showed that the number of apoptotic cells had increased significantly in the DZN-treated group compared with the control group ($P<0.001$).

In the control group, the majority of secondary follicles had no apoptotic cells and in some of follicles a few TUNEL positive cells were observed, while in DZN-treated group a lot of apoptotic cells were existed.

In the experimental group 2 (vit E+DZN-treated group), number of apoptotic cells decreased significantly compared with diazinon group ($P<0.001$).

The number of apoptotic cells in sham and vit E-treated groups was similar to the control group; there were no apoptotic cells and some of follicles had 1 or 2 TUNEL- positive cells (Figure 1 and 2).

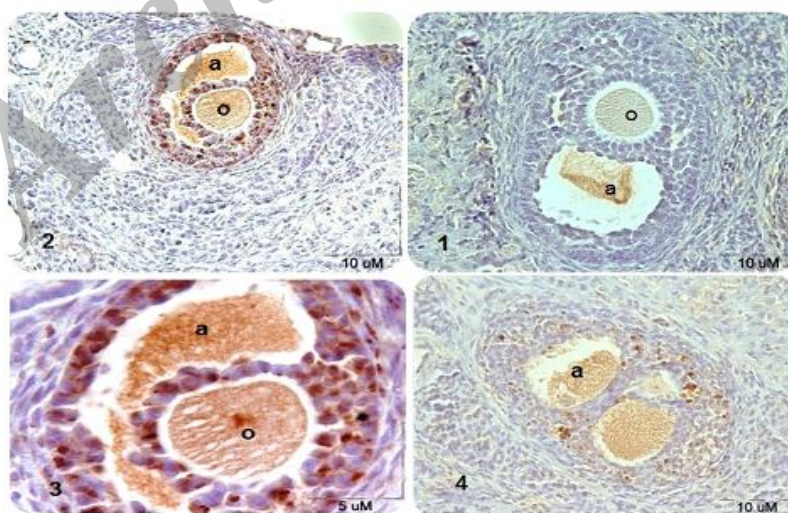


Figure 1. Microscopic sections of rat secondary ovarian follicles after TUNEL immunohistochemical technique. TUNEL-positive nuclei are seen in brown. 1) control group, absence of TUNEL-positive cells. 2) DZN-treated group that DZN increased significantly TUNEL-positive cells compared control group. 3) DZN-treated group by magnification $\times 100$. 4) DZN+vit E treated group that number of TUNEL-positive cells decreased significantly compared DZN group. a:antrum, o:oocyte.

Graffian Follicles

As it is shown in Figure 3 and 4, the highest number of apoptotic cells were observed in diazinon treated group. In the DZN-treated group, number of apoptotic cells increased significantly compared with control group ($P<0.001$). In the vit E+DZN-treated group, number of apoptotic cells decreased significantly

compared with DZN treated group ($P<0.001$) that was indicating the protective role of vit E. The number of apoptotic cells had no significant difference between control, sham and vit E-treated groups. The number of apoptotic cells in these groups was significantly less than DZN treated group and vit E+DZN-treated group ($P<0.05$).

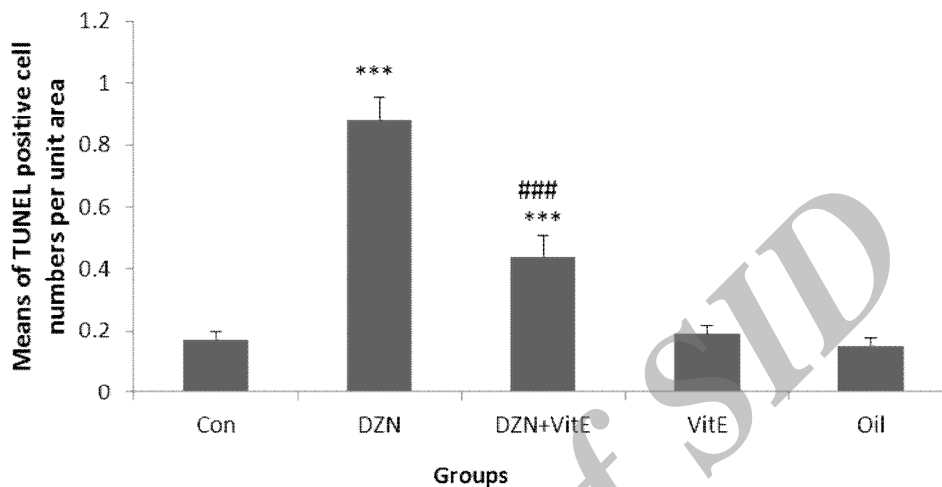


Figure 2. Comparison of apoptotic cell per unit area in secondary follicles in different groups (mean \pm SD).*** $P<0.001$ vs. control, ### $P<0.001$ vs DZN.

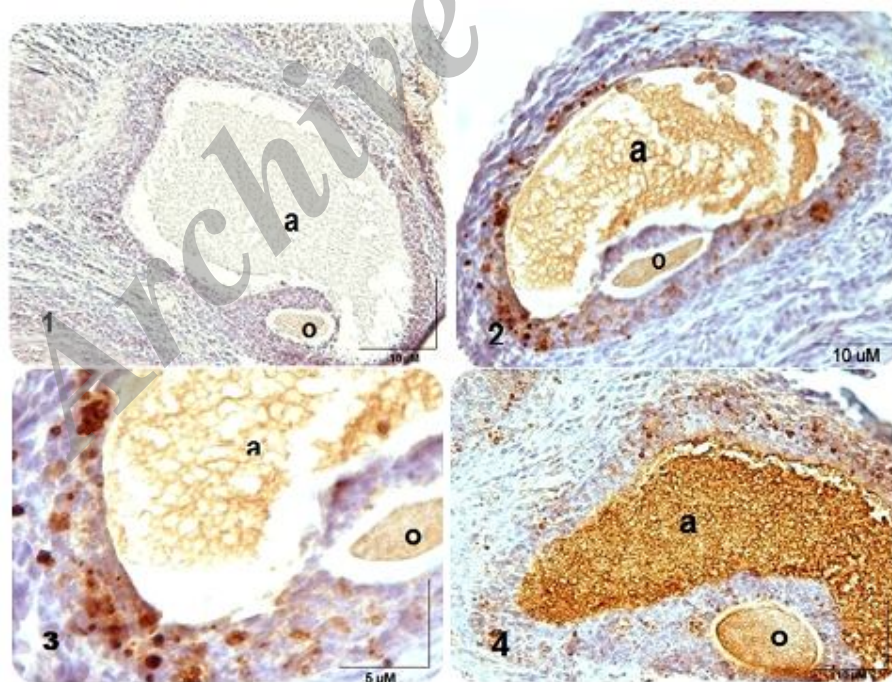


Figure 3. Microscopic sections of rat ovarian graffian follicles after TUNEL immunohistochemical technique. TUNEL-positive nuclei are seen in brown. 1) control group, absence of TUNEL-positive cells. 2) DZN-treated group that DZN increased significantly TUNEL-positive cells compared control group. 3) DZN-treated group by magnification $\times 100$. 4) DZN+vit E treated group that number of TUNEL-positive cells decreased significantly compared DZN group. a: antrum, o: oocyte.

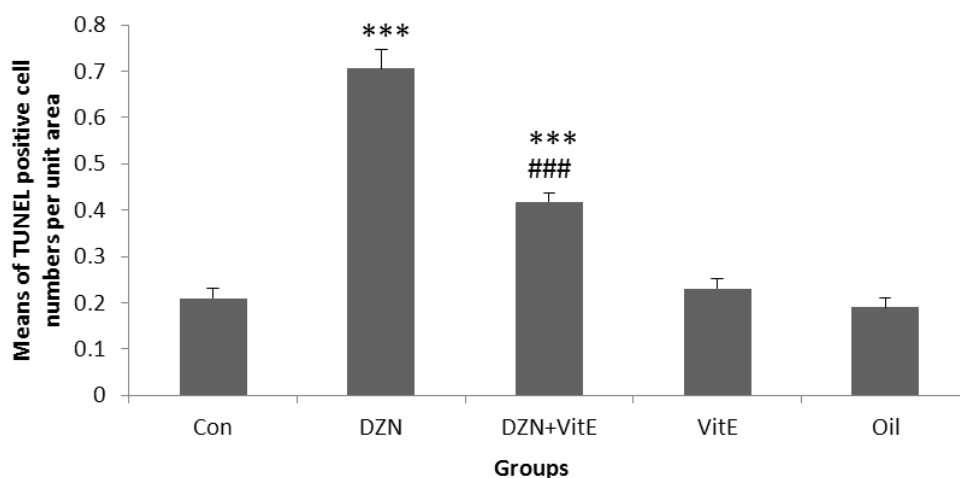


Figure 4. Comparison of apoptotic cell per unit area in graffian follicles in different groups (mean \pm SD).*** $P < 0.001$ vs. control, ### $P < 0.001$ vs DZN.

DISCUSSION

This study was performed to investigate the effects of DZN on apoptosis of ovarian follicles in adult rats and to evaluate the protective role of vit E.

DZN is not only used in pest control of fruits and plants, but it is also used as an ectoparasiticide for cattle in veterinary applications [39]. DZN is absorbed from the gastrointestinal tract and rapidly metabolized [14]. Organophosphate insecticides induce biochemical and histopathological changes in several organs, such as liver, kidney, immune system, pancreas, and cardiac and vascular walls [40]. One of the targeted organs is the ovary, which has a major role in reproductive function by synthesizing hormones and producing oocyte [15, 41].

The results of this study demonstrated that DZN raised the number of apoptotic cells in ovarian follicles and vit E administration, by its antioxidant activity, was able to improve the toxic effect of DZN. The main mechanism of DZN toxicity is inhibition of acetylcholinesterase (AChE) activity in the target tissues, which is the most important action of DZN compound [5]. AChE is an enzyme that catalyzes acetylcholine and prevents its accumulation at cholinergic synapses [1, 7].

DZN causes formation of ROS and induces oxidative stress. Mitochondria play important role in apoptosis. Mitochondrial dysfunction by oxidative stress release cytochrome C and activate caspase that lead to

apoptotic cell death [8]. We assessed the effects of DZN on the number of apoptotic cells in ovarian follicles of adult rats and the protective role of vit E.

This is the first study that evaluated the effects of DZN on follicle cells' apoptosis in the ovary of rats and the protective role of vit E. We found that primordial follicles were lacking apoptotic cells in all groups (control, sham, DZN-treated group, DZN+vit E treated group and vit E treated group). This fact indicates that apoptosis in follicular cells of ovary, starts from primary follicle formation phase. The lack of apoptotic cells in primordial follicles proves this hypothesis that approximately 99% of stored follicles are degenerated in early stages of primary follicles formation. Majority of primary follicles in all study groups were TUNEL positive, so DZN may not have any effect on these follicles. On the other hand, the administration of vit E plus DZN slightly decreased the number of apoptotic cells of primary follicles compared with DZN treated group, so it seems that vit E is not significantly able to maintain and prevent DZN induced apoptosis in follicular cells of primary follicles.

We also found that the number of apoptotic cells in secondary and Graafian follicles significantly increased in DZN groups compared with control. In addition, the vit E administration besides DZN significantly decreased number of apoptotic cells in these follicles compared with DZN group. This result

proves that antioxidants such as vit E, improve cells antioxidant defense system or protect cells from oxidative stress by inhibiting different pathways of apoptosis [42]. The impact of OPS on cell apoptosis in other tissues and protective role of antioxidants such as vit E had been reported that includes the following. Administration of vit E plus methidathion or OPS prevents the harmful effects of these chemicals on reproductive organs [43]. DZN had induced apoptosis by oxidative stress in liver, and Crocin was able to decrease it [44].

Furthermore, vit E may have the protective role against the heart destruction due to apoptosis [45]. OPS such as chlorpyrifos can harm the eye by inducing apoptosis in cells of retina, and vitamins E and C decrease these effects [46]. Endosulfan which is an organophosphate, cause toxic changes in heart tissues of rabbit but this toxicity decrease by vit C antioxidant [47]. Organophosphate pesticides are also toxic for immune cells by induction of apoptosis and necrosis [48]. In all of these studies that were consistent with our results, OPS induced oxidative stress, which was through releasing of cytochrome C that activate caspase 3 and 9 and induce apoptosis [44].

CONCLUSION

DZN induces apoptosis in secondary and graffian follicles and vit E inhibited apoptosis induced by DZN. Therefore, vitE can protect ovarian tissues against this toxicity.

ACKNOWLEDGMENTS

The study was part of MSc thesis in anatomical research. It was conducted under contract NO.91109, supported by a grant from Research Council of Mashhad University of Medical Sciences. The authors wish to declare their gratitude to Dr. Shabnam mohammadi, Mrs. Motajadded and Mrs. Ziaeei. The authors declare that there is no conflict of interests.

REFERENCES

1. Shah MD, Iqbal M. Diazinon-induced oxidative stress and renal dysfunction in rats. *Food Chem. Toxicol* 2010;48(12):3345-53.
2. Anbarkeh FR, Nikraves MR, Jalali M, Sadeghnia HR, Sargazi Z, Mohammadzadeh L. Single dose effect of diazinon on biochemical parameters in testis tissue of adult rats and the protective effect of vitE. *IJRM* 2014;12(11):731-6.
3. Sargazi Z, Nikraves MR, Jalali M, Sadeghnia HR, RahimiAnbarkeh F. Diazinon-Induced Ovarian Toxicity and Protection by Vitamins E. *Iran J Toxicol* 2014;8(26):1130-5.
4. Reece R, Handson P. Observations on the accidental poisoning of birds by organophosphate insecticides and other toxic substances. *Vet Record* 1982;111(20):453-5.
5. Yehia MA, El-Banna SG, Okab AB. Diazinon toxicity affects histophysiological and biochemical parameters in rabbits. *Exp Toxicol Pathol* 2007;59(3):215-25.
6. Jahromi VH, Koushkaki M, Kargar H. The effects of malathion insecticide on ovary in female rats. *National park forschung in der schweiz. Switzerland Res Park J* 2012;101(5):231-5.
7. Uzun FG, Kalender S, Durak D, Demir F, Kalender Y. Malathion-induced testicular toxicity in male rats and the protective effect of vitamins C and E. *Food Chem Toxicol* 2009;47(8):1903-8.
8. Casas E, Bonilla E, Ducolomb Y, Betancourt M. Differential effects of herbicides atrazine and fenoxaprop-ethyl, and insecticides diazinon and malathion, on viability and maturation of porcine oocytes in vitro. *Toxicol In Vitro* 2010;24(1):224-30.
9. Ogutcu A, Uzunhisarcikli M, Kalender S, Durak D, Bayrakdar F, Kalender Y. The effects of organophosphate insecticide diazinon on malondialdehyde levels and myocardial cells in rat heart tissue and protective role of vitamin E. *Pestic Biochem Physiol* 2006;86(2):93-8.
11. Altuntas I, Kilinc I, Orhan H, Demirel R, Koylu H, Delibas N. The effects of diazinon on lipid peroxidation and antioxidant enzymes in erythrocytes in vitro. *Hum. Exp Toxicol* 2004;23(1):9-13.
11. Amirkabirian N, Teimouri F, Esmaily H, Mohammadirad A, Aliahmadi A, Abdollahi M. Protection by pentoxifylline of diazinon-induced toxic stress in rat liver and muscle. *Toxicol Mech Meth* 2007;17(4):215-21.
12. Ahmadi S, Jafari M, Asgari A, Salehi M. Acute effect of diazinon on lipid peroxidation level and activities of antioxidant enzymes in rat spleen. *J Kermanshah Univ Med Sci* 2012;16(1):1-9.
13. Yilmaz N, Yilmaz M, Altuntas I. Diazinon-induced brain toxicity and protection by vitamins E plus C. *Toxicol Ind Health* 2011;28(1):51-7.
14. Kalender S, Ogutcu A, Uzunhisarcikli M, Acikgoz F, Durak D, Ulusoy Y, et al. Diazinon-induced hepatotoxicity and protective effect of vitamin E on some biochemical indices and ultrastructural changes. *Toxicol* 2005;211(3):197-206.
15. Güney M, Demirin H, Oral B, Özgüner M, Bayhan G, Altuntas I. Ovarian toxicity in rats

- caused by methidathion and ameliorating effect of vitamins E and C. *Hum.Exp. Toxicol* 2007;26(6):491-8.
16. Hariri AT, Moallem SA, Mahmoudi M, Memar B, Hosseinzadeh H. Sub-acute effects of diazinon on biochemical indices and specific biomarkers in rats: protective effects of crocin and safranal. *Food Chem. Toxicol* 2010;48(10):2803-8.
 17. Agarwal A, Aponte-Mellado A, Premkumar BJ, Shaman A, Gupta S. The effects of oxidative stress on female reproduction: a review. *Reprod Biol Endocrinol* 2012;10(1):49-51.
 18. Kaur P, Radotra B, Minz RW, Gill K. Impaired mitochondrial energy metabolism and neuronal apoptotic cell death after chronic dichlorvos (OP) exposure in rat brain. *Neurotoxicology* 2007;28(6):1208-19.
 20. Saulsbury MD, Heyliger SO, Wang K, Johnson DJ. Chlorpyrifos induces oxidative stress in oligodendrocyte progenitor cells. *Toxicol* 2009;259(1):1-9.
 20. Oral B, Guney M, Demirin H, Ozguner M, Giray SG, Take G, et al. Endometrial damage and apoptosis in rats induced by dichlorvos and ameliorating effect of antioxidant vitamins E and C. *Reprod Toxicol* 2006;22(4):783-90.
 21. Agarwal A, Gupta S, Sharma RK. Role of oxidative stress in female reproduction. *Reprod Biol Endocrinol* 2005;3(28):1-21.
 22. Behrman HR, Kodaman PH, Preston SL, Gao S. Oxidative stress and the ovary. *J Soc Gynecol Invest* 2001;8(1 suppl):40-2.
 23. Sabatini L, Wilson C, Lower A, Al-Shawaf T, Grudzinskas JG. Superoxide dismutase activity in human follicular fluid after controlled ovarian hyperstimulation in women undergoing in vitro fertilization. *Fertil Steril* 1999;72(6):1027-34.
 24. Ishikawa M. [Oxygen radicals-superoxide dismutase system and reproduction medicine]. *Nihon Sanka Fujinka Gakkai Zasshi* 1993;45(8):842-8.
 25. Possamai F, Fortunato J, Feier G, Agostinho F, Quevedo J, Wilhelm Filho D, et al. Oxidative stress after acute and sub-chronic malathion intoxication in Wistar rats. *Environ Toxicol Pharmacol* 2007;23(2):198-204.
 26. Ruder EH, Hartman TJ, Goldman MB. Impact of oxidative stress on female fertility. *Curr Opin Obstet Gynecol* 2009;21(3):219-22.
 27. Joshi SC, Mathur R, Gajraj A, Sharma T. Influence of methyl parathion on reproductive parameters in male rats. *Environ Toxicol Pharmacol* 2003;14(3):91-98.
 28. Mohseni Kouchesfahani H, Parivar K, Tahamtani Y. Effect of diazinon as a pesticide on oogenesis and ovary structure of balb/c mice strain. *J SCI* 2008;8(2):143-52.
 29. Oksay T, Naziroglu M, Ergun O, Dogan S, Ozatik O, Armağan A, et al. N-acetylcysteine attenuates diazinon exposure-induced oxidative stress in rat testis. *Andrologia* 2013;45(3):171-7.
 30. Hiremath M, Kaliwal B. Effect of endosulfan on ovarian compensatory hypertrophy in hemicastrated albino mice. *Reprod Toxicol* 2002;16(6):783-90.
 31. Dhondup P, Kaliwal BB. Inhibition of ovarian compensatory hypertrophy by the administration of methyl parathion in hemicastrated albino rats. *Reprod Toxicol* 1997;11(1):77-84.
 32. Sortur S, Kaliwal B. Effect of methyl parathion formulation on estrous cycle and reproductive performance in albino rats. *Indian J Exp Biol* 1999;37(2):176-8.
 33. Gavrieli Y, Sherman Y, Ben-Sasson SA. Identification of programmed cell death in situ via specific labeling of nuclear DNA fragmentation. *J Cell Biol* 1992;119(3):493-501.
 34. Charriaut-Marlangue C, Ben-Ari Y. A cautionary note on the use of the TUNEL stain to determine apoptosis. *Neuroreport* 1995;7(1):61-4.
 35. Ichimura E, Fukuda T, Oyama T, Kashiwabara K, Sakurai S, Sano T, et al. Formalin fixation by boiling. Is it suitable for the TUNEL staining? *Pathol Int* 1995;45(12):971-2.
 36. Clarke RG LE, Johnson IT, Pinder AC. Apoptosis can be using annexin V binding, but not by TUNEL assay or sub-Go DNA content. *Cytometry* 2000;3(40):252-7.
 37. Kraupp BG, Ruttkay-Nedecky B, Koudelka H, Bukowska K, Bursch W, Schulte-Hermann R. In situ detection of fragmented DNA (TUNEL assay) fails to discriminate among apoptosis, necrosis, and autolytic cell death: a cautionary note. *Hepatology* 1995;21(5):1465-8.
 38. Rajabzadeh AA, Bideskan E, Reza A, Haghir H, Fazel AR. Morphometrical study of polysialylated neural cell adhesion molecule positive cells in rat pups hippocampus following induction of seizure during pregnancy. *Iran Biomed J* 2011;15(4):157-63.
 39. Garfitt S, Jones K, Mason H, Cocker J. Exposure to the organophosphate diazinon: data from a human volunteer study with oral and dermal doses. *Toxicol Lett* 2002;134(1):105-13.
 40. Gomes J, Dawodu A, Lloyd O, Revitt D, Anilal S. Hepatic injury and disturbed amino acid metabolism in mice following prolonged exposure to organophosphorus pesticides. *Hum Exp Toxicol* 1999;18(1):33-7.
 41. Mattison DR, Thomford PJ. The mechanisms of action of reproductive toxicants. *Toxicol Pathol* 1989;17(2):364-76.

42. Buttke TM, Sandstrom PA. Oxidative stress as a mediator of apoptosis Immunol Today 1994;15(1):7-10.
43. Khorami S, Farrokhi F, Tukmechi A, Nowrozi R. Effect of pentoxifylline and vitamin E on ovarian follicles in Rats. J Shahrekord Univ Med Sci 2013;15(3):64-73.
44. Lari P, Rashedinia M, Abnous K, Hosseinzadeh H. Alteration of protein profile in rat liver of animals exposed to subacute diazinon: A proteomic approach. Electrophoresis 2014;35(10):1419-27.
45. Amara IB, Soudani N, Hakim A, Troudi A, Zeghal KM, Boudawara T, et al. Protective effects of vitamin E and selenium against dimethoate-induced cardiotoxicity in vivo: Biochemical and histological studies. Environ Toxicol 2013;28(11):630-43.
46. Yu F, Wang Z, Ju B, Wang Y, Wang J, Bai D. Apoptotic effect of organophosphorus insecticide chlorpyrifos on mouse retina in vivo via oxidative stress and protection of combination of vitamins C and E. Exp Toxicol Pathol 2008;59(6):415-23.
47. Ozmen O. Cardiotoxicity and apoptotic activity in subacute endosulfan toxicity and the protective effect of vitamin C in rabbits: a pathological study. J Environ Pathol Toxicol Oncol 2013;32(1):53-8.
48. Baba NA, Raina R, Verma PK, Sultana M, Malla R. Ameliorative effect of vitamin C and E on hematological alterations induced by chlorpyrifos alone and in conjunction with fluoride in Wistar rats. J Exp Med 2013;3(3):213-8.

Archive of SID