

Alterations in the Corpuscles of Stannius of *Euphorbia royleana* Treated Catfish, *Heteropneustes fossilis*

Maniram Prasad, Abhishek Kumar, Sunil Kumar Srivastav, Ajai Kumar Srivastav*

Received: 09.10.2016

Accepted: 16.11.2016

ABSTRACT

Background: We aimed to evaluate effect of *Euphorbia royleana* exposure on histocytology of corpuscles of Stannius in fish, *Heteropneustes fossilis*.

Methods: Fish were subjected to 2.47 mg/L and 0.618 mg/L of *E. royleana* for short-term and long-term exposure, respectively. Blood samples were collected on 24, 48, 72 and 96 h in short-term and after 7, 14, 21, and 28 d in long-term experiment and analyzed for serum calcium levels. Corpuscles of Stannius were fixed on these intervals.

Results: Serum calcium levels of *H. fossilis* decline progressively from 48 h until 96 h following the *E. royleana* exposures. Serum calcium levels decreased on 7 d. This decrease continued until close of the experiment. After 96 h treatment, AF-positive cells of CS exhibit increased granulation. Nuclear volume of these cells exhibited no change throughout short-term treatment. Increased nuclear volume of AF-negative cells of CS is noticed at 96 h. Nuclear volume of AF-positive cells decreases after 14 d and onwards. The AF-positive cells exhibit increased granulation following 21 d exposure. After 28 d these changes are intensified and few degenerating cells have been encountered. AF-negative cells of CS increase in their nuclear volume 21 d onwards.

Conclusion: The botanical pesticide induced severe changes in the corpuscles of Stannius of catfish. This gland controls the calcium level in fish and thus the use of *E. royleana* should not be done near water reservoirs.

Key words: Calcium, Corpuscles of Stannius, *E. royleana*, Fish.

IJT 2017 (3): 27-32

INTRODUCTION

Corpuscles of Stannius were considered unique to fish, as they have not been identified in other vertebrates [1-5]. A correlation between the CS and calcium regulation was first established [6] and only few laboratories around the world studied these glands. These structures (CS) were primarily considered the adrenal glands and, consequently, repeated efforts have been made until the mid-1960s to identify and characterize steroids and steroidogenic enzymes in CS tissue [7]. Few other workers [8, 9] also considered these glands as homologous of the adrenal glands of the terrestrial vertebrates. Identification of the interrenal tissues in the head kidney of fishes as the true adrenal homologue [10-12], led to consider that the CS bears no relationship to the adrenocortical tissue and these are endocrine glands possessing specific nature. The studied on

ontogeny of CS cells and entirely different; suggested that they produce adrenal steroids [13]. At ultrastructural level, corpuscles of Stannius cells possess an extensive network of rough endoplasmic reticulum and Golgi and secretory granules; they synthesized polypeptides, not steroids [14].

"Many plant species from different families which possess number of compounds such as - saponins, tannins, alkaloids di- and tri-terpenoids have been used for control of harmful snails, disease-causing insects such as mosquito larvae" [15-21]. The effects of *Euphorbia royleana* plant were studied on the histopathological parameters of catfish *H. fossilis* [22, 23].

This study was an attempt to investigate the effects of latex of *E. royleana* on the corpuscles of Stannius of a teleost, *H. fossilis*. The effects of *E. royleana* on the corpuscles of Stannius of catfish *H. fossilis* have not been reported, yet.

MATERIALS AND METHODS

Adult freshwater teleost *Heteropneustes fossilis* (both sexes body weight 27–38 g) were collected locally during the year 2012 from Ramgarh Tal, Gorakhpur. Healthy fish showing no external signs of injury and disease were selected for experiments and were acclimatized to laboratory conditions (under natural photoperiod 11.46–12.18 and temperature 26.74 ± 2.11 °C; pH 7.26 ± 0.09 ; hardness 167.97 ± 5.69 mg/L as CaCO_3 ; dissolved oxygen 7.85 ± 0.36 mg/L) for 15 d in dechlorinated tap water. The white milky latex of *E. royleana* was drained into glass tubes by cutting the stems and bark. The latex was lyophilized at -40 °C and the lyophilized powder was stored at -20 °C under dark until further use.

The Ethical Committee of Department of Zoology, DDU Gorakhpur University, approved all the experimental protocols.

In this experimental study, latex of *E. royleana* was used. The 96 h LC_{50} value of latex of *E. royleana* (3.090 mg/L for the fish *H. fossilis*) have been reported [24]. This was an experimental study performed for short-term and long-term duration. In short-term exposure, the fish were subjected to 2.47mg/L of latex of *E. royleana* (80% of 96 h LC_{50} value). In long-term exposure, the fish were subjected to 0.618 mg/L (20% of 96 h LC_{50} value) of latex of *E. royleana*. Simultaneously, a control group was also run for comparison by using the tap water containing ethanol. Fish were kept in groups of 10 in 40 L media. Latex of *E. royleana* was weight and stock solution (4 mg/ml) was prepared in 100% ethanol. Six fish were sacrificed on each time intervals from control and experimental (*E. royleana*) groups after 24, 48, 72 and 96 h in short-term exposure and after 7, 14, 21 and 28 d in long-term experiment.

Blood samples were collected by sectioning of the caudal peduncle of fish. The sera were separated by centrifugation at 3500 r. p. m. and analyzed for calcium levels (calcium kit, RFCL Limited India). After the collection of blood samples, the corpuscles of Stannius were fixed in aqueous Bouin's fluid. Tissues, thus fixed were routinely processed in graded series of alcohols, cleared in xylene, and then embedded in paraffin wax. Serial sections were cut at 6 μm and stained with aldehyde fuchsin (AF) for light microscopic examination (Olympus CH 20i). Photomicrograph was taken with the aid of Olympus E 420 camera.

Nuclear indices (maximal length and maximal width) of corpuscles of Stannius were determined (50 nuclei were measured per specimen; thus 300 nuclei were measured from six specimens) were taken with the aid of ocular micrometer and then the nuclear volume was calculated as $\text{volume} = 4/3 \pi ab^2$, where 'a' is the major semiaxis and 'b' is the minor semiaxis.

All samples were estimated in duplicate. All data were presented as the mean \pm S.E. of six specimens and student *t* test was used for the determination of statistical significance. In all studies, the experimental group was compared to its specific time control group. Two-way Analysis of Variance (ANOVA) was used for multiple group comparisons.

RESULTS

Short-Term Exposure

No alteration has been noticed in the serum calcium levels of *H. fossilis* at 24 h following the *E. royleana* exposure. The levels decline progressively from 48 h until 96 h (Figure 1). Analysis of variance indicated that the level of serum calcium were significantly different between groups (between intervals $F = 20.80$, $P < 0.0001$ between treatment $F = 169.51$, $P < 0.0001$).

The histological details of corpuscles of Stannius (AF-positive and AF-negative cells) of control fish were noticed after aldehyde fuchsin staining (Figure 2).

Up to 72 h following the treatment with latex of *E. royleana* there is no change in the histological structure of corpuscles of Stannius of fish. AF-positive cells of CS exhibit increased granulation after 96 h treatment (Figure 3). No change has been noticed in the nuclear volume of these cells (Figure 4) throughout the short-term exposure. Analysis of variance indicated that in short-term experiment the nuclear volume of AF-positive cells were not significant (among time intervals $F = 0.38$, ns; between treatments $F = 0.08$, ns)

AF-negative cells of corpuscles of Stannius of fish treated with latex of *E. royleana* depict an increased nuclear volume at 96 h (Figure 5). Analysis of variance indicated that in AF-negative cells the values were significant (among time intervals $F = 8.15$, $P < 0.0001$; between treatment $F = 7.70$, $P < 0.008$).

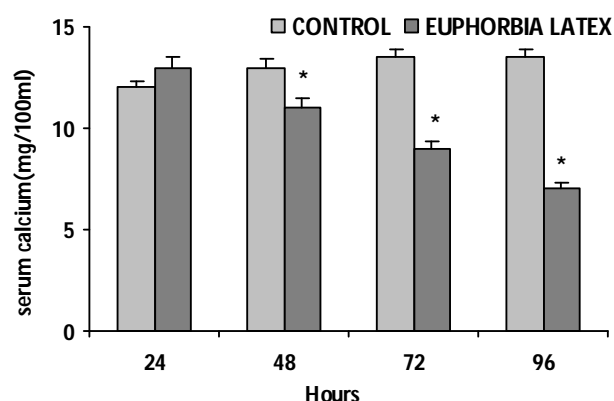


Figure 1. Serum calcium levels of short-term latex of *E. royleana*- treated *Heteropneustes fossilis*. Values are mean \pm S.E. of six specimens. Asterisk indicates significant differences ($P < 0.05$) from control.

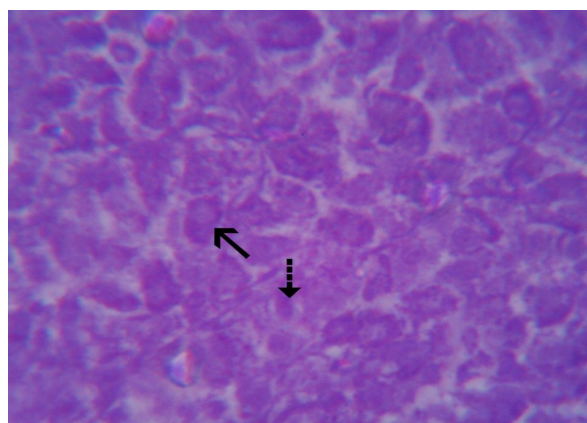


Figure 2. Corpuscles of Stannius of control fish exhibiting AF- positive (arrows) and AF- negative cells (broken arrows). AF x 500.

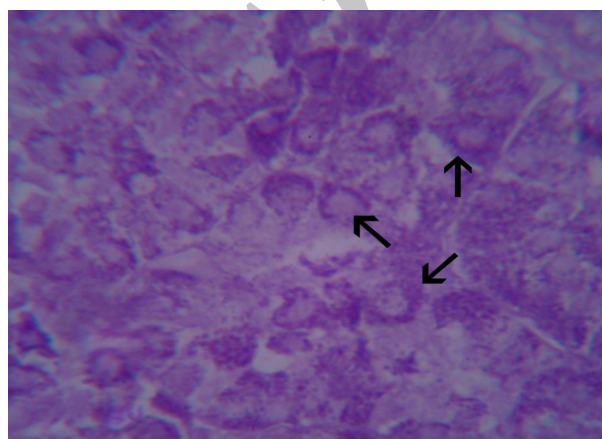


Figure 3. Corpuscles of Stannius of 96h latex of *E. royleana* treated *Heteropneustes fossilis* showing increased granulation (arrows) in AF-positive cells. AF X 500.

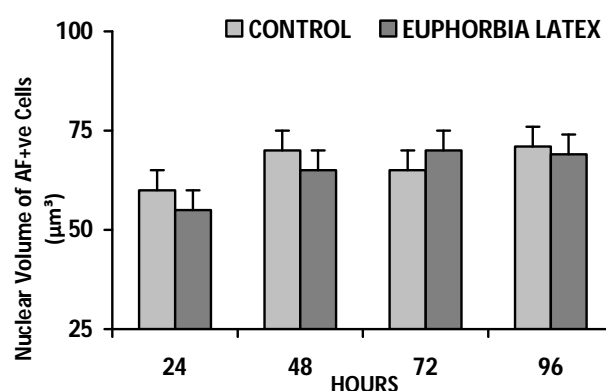


Figure 4. Nuclear volume of AF-positive cells of short- term latex of *E. royleana* treated *Heteropneustes fossilis*. Each value represents mean \pm S.E. of six specimens.

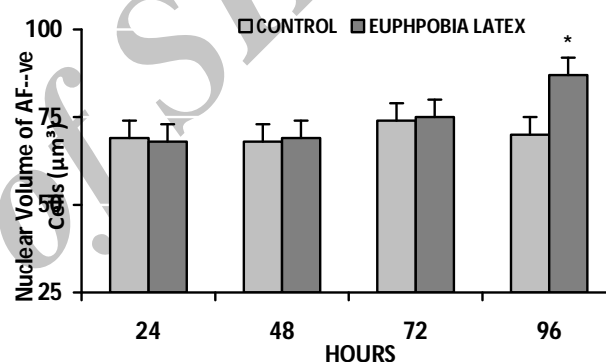


Figure 5. Nuclear volume of AF-negative cells of short- term latex of *E. royleana* treated *Heteropneustes fossilis*. Each value represents mean \pm S.E. of six specimens. Asterisk indicates significant differences ($P < 0.05$) from control.

Long-Term Exposure

Latex of *E. royleana* provoked a decrease in the serum calcium level on day 7. This decrease continued progressively until the close of the experiment (28 d) (Figure 6). Analysis of variance indicated that the level of serum calcium was significantly different between groups (between intervals $F=14.41$, $P < 0.0001$ between treatment $F=152.17$, $P < 0.0001$).

The corpuscles of Stannius of fish remain unaffected up to day 7 following treatment with latex of *E. royleana*. The nuclear volume of AF-positive cells decreased after day 14 following the treatment (Figure 7). The AF-positive cells exhibit increased granulation following 21 d exposure (Figure 8). The nuclear volume of these

cells is further decreased (Figure 7). After 28 d these changes are intensified and few degenerating cells have been encountered (Figure 9). Analysis of variance indicated that in long-term experiment the nuclear volume of AF-positive cells were significant (among time intervals $F=15.75$, $P<0.0001$; between treatments $F=0.126.94$, $P<0.0001$)

The AF-negative cells of CS exhibit no change up to 14 d following exposure with latex of *E. royleana*. These cells exhibits increase in their nuclear volume 21 d onwards (Figure 10). Analysis of variance indicated that in long-term experiment the nuclear volume of AF-positive cells were significant (among time intervals $F=18.74$, $P<0.0001$; between treatments $F=37.39$, $P<0.0001$)

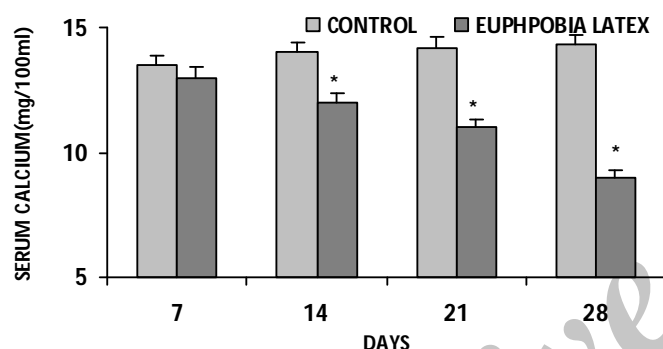


Figure 6. Serum calcium levels of long-term latex of *E. royleana*- treated *Heteropneustes fossilis*. Values are mean \pm S.E. of six specimens. Asterisk indicates significant differences ($P<0.05$) from control.

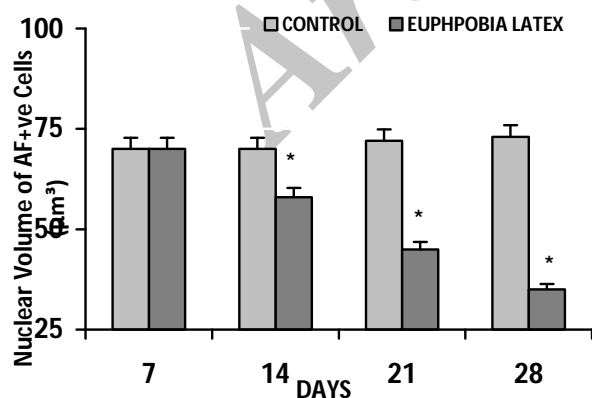


Figure 7. Nuclear volume of AF-positive cells of long-term latex of *E. royleana* treated *Heteropneustes fossilis*. Each value represents mean \pm S.E. of six specimens. Asterisk indicates significant differences ($P<0.05$) from control.

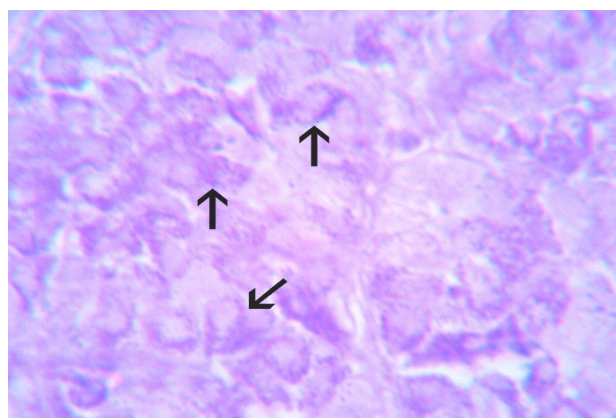


Figure 8. Increased granulation (arrows) in the AF-positive cells of 21 d latex of *E. royleana* treated *Heteropneustes fossilis*. AF X 500.

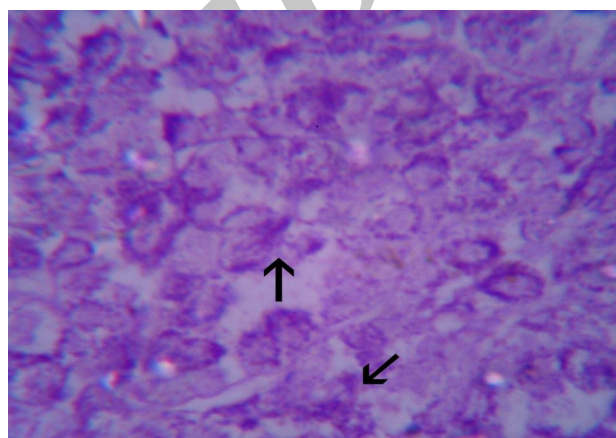


Figure 9. Corpuscles of Stannius of 28 d latex of *E. royleana* exposed *Heteropneustes fossilis* showing degeneration (arrows) in AF-positive cells. AF X 500.

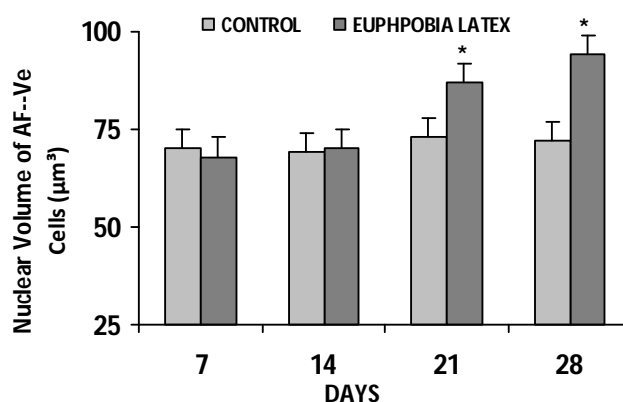


Figure 10. Nuclear volume of AF-negative cells of long-term latex of *E. royleana* treated *Heteropneustes fossilis*. Each value represents mean \pm S.E. of six specimens. Asterisk indicates significant differences ($P<0.05$) from control.

DISCUSSION

Increased accumulation of secretory granules and a decrease in nuclear volume of AF-positive cells have been noticed in *H. fossilis* treated with latex of *E. royleana*. Accumulation of secretory granules and decreased nuclear volume of AF-positive cells have been recorded earlier in response to exposure of fish to toxicants [25- 28]. Branchial calcium uptake in the fish is controlled by AF-positive cells through the secretion of stanniocalcin (a hypocalcemic hormone) [3, 4, 29-34]. Prolonged hypocalcemia observed in latex of *E. royleana* treated fish may be the possible reason for the increased granulation in the AF-positive cells and can be explained because of inhibition of the hormonal release and continued biosynthesis of stanniocalcin.

Accumulation of AF-positive granules in CS derives support from the earlier investigators in which similar observation is noticed in response to experimentally induced hypocalcemia in fishes kept in ambient acalcic freshwater [33, 35]. In mammals, accumulation of secretory granules in the calcitonin cells (responsible for the secretion of a hypocalcemic factor—CT) has also been noticed in response to hypocalcemia [36- 39].

CONCLUSION

E. royleana can severely affect the physiology of calcium homeostasis in fishes noticed to alterations in serum calcium content as well as cytological changes in corpuscles of Stannius of the freshwater fish, *H. fossilis*. Corpuscles of Stannius is responsible for calcium influx hence any alteration in calcium and CS causes physiological disturbances which might affect seriously the normal vital functions, growth rate, reproduction and their survival in nature. Hence, the botanical pesticides should be used carefully in agricultural fields as well as near fish inhabiting water reservoirs.

ACKNOWLEDGMENT

Authors are thankful to Head, Department of Zoology, DDU Gorakhpur University, Gorakhpur, for his help during the conduct of experiment. The authors declare that there is no conflict of interests.

REFERENCES

1. Krishnamurthy V, Bern HA. Correlative histologic study of the corpuscles of Stannius and the juxtaglomerular cells of teleost fishes. *Gen Comp Endocrinol* 1969;13(3):313-35.
2. Pang PK. Endocrine control of calcium metabolism in teleosts. *Am Zool* 1973:775-92.
3. Wendelaar Bonga SE, Pang PKT. Stannius corpuscles. In: *Vertebrate Endocrinology: Fundamentals and Biomedical Implications*. Pang PKT Schreibman MP eds. Academic Press:London. 1986 .p. 436-64.
4. Bonga SW, Pang P. Control of calcium regulating hormones in the vertebrates: parathyroid hormone, calcitonin, prolactin, and stanniocalcin. *Int Rev Cytol* 1991;128:139-213.
5. Wagner GF. 9 The Molecular Biology of the Corpuscles of Stannius and Regulation of Stanniocalcin Gene Expression. *Fish Physiol* 1994;13:273-306.
6. Fontaine M. Corpuscles de Stannius et regulation ionique (CA K NA) du milieu de l'anguille *Anguilla anguilla* L. *CR Acad Sci* 1964;259(4):875-&.
7. Krishnamurthy V. Cytophysiology of corpuscles of Stannius. *Int Rev Cytol* 1976;46:177-249.
8. Giacomini E. Sistema interrenale e il sistema chromaffine (sistema fecchromo) in aloune specie di teleostei con rene cephalico (pronephros) persistente, ceratteri differenziali fra interrenale anteriore e corpuscoli di Stannius. *Conno Sullo avilluppo di questiorgani nei Salmonidi*. *Rendic Acad Sci Inst Bologna, New Series* 1910; 14: 86-103.
9. Diamare V. Recherche isotofisologiche e morfologiche e annotazioni storche e critiche. *Atti Acad Della Sci Fish e Mat Napoli* 1953; 3: 1-69.
10. Aboim A. L'organe interrénal des cyclostomes et des poissons. *Port Acta Biol I, Ser A* 1946(4):353-83.
11. Rasquin P. Effects of carp pituitary and mammalian ACTH on the endocrine and lymphoid systems of the teleost *Astyanax mexicanus*. *J Exp Zool* 1951;117(2):317-57.
12. Youson J, Butler D, Chan A. Identification and distribution of the adrenocortical homolog, chromaffin tissue, and corpuscles of Stannius in *Amia calva* L. *Gen Comp Endocrinol* 1976;29(2):198-211.
13. Garrett FD. The development and phylogeny of the corpuscle of Stannius in ganoid and teleostean fishes. *J Morphol* 1942;70(1):41-67.
14. Ogawa M. Fine structure of the corpuscles of Stannius and the interrenal tissue in goldfish, *Carassius auratus*. *Cell Tissue Res* 1967;81(2):174-89.
15. Hostettman K, Lea PJ. Biologically active natural products. larendon press: Oxford; 1987.p. 283-4.

16. Okunji CO, Iwu MM. Control of schistosomiasis using hegerian edicinal plants as molluscicides. *Int j crude Drug Res* 1988; 26: 246-52.
17. Gopalsamy N, Guheo H, Owdally R, Hostettaman K. Molluscicidal saponins of polysacias *dechrostachya*. *Phytochem* 1990; 29: 793-95.
18. Alard F, Geerts S, Triest L. Toxicité d'Ambrosia maritima L., plante molluscicide, sur les organismes aquatiques non-cibles. *Toxicon*. 1991;29(6):745-50.
19. Singh A, Singh D, Misra T, Agarwal R. Molluscicides of plant origin. *Biol Agricult Horticult* 1996;13(3):205-52.
20. Singh K, Singh A, Singh D. The use of piperonyl butoxide and MGK-264 to improve the efficacy of some plant-derived molluscicides. *Pest Manage Sci* 1998;54(2):145-9.
21. Dubey N, Shukla R, Kumar A, Singh P, Prakash B. Prospects of botanical pesticides in sustainable agriculture. *Curr Sci* 2010;98(4):479-80.
22. Prasad M, Kumar A, Srivastav SK, Srivastav AK. Euphorbia royleana, a botanical pesticide affects ultimobranchial gland of the catfish *Heteropneustes fossilis*. *Egypt J Biol* 2011;13(1):14-20.
23. Prasad M, Kumar A, Suzuki N, Srivastav A. Botanical pesticide *Nerium indicum* alters prolactin cells of stinging catfish *Heteropneustes fossilis*. *Int J Zool Invest*. 2015;1:77-84.
24. Prasad M, Kumar A, Mishra D, Srivastav SK, Srivastav AK. Acute toxicity of *Euphorbia royleana* boiss (euphorbiaceae) latex on fresh water catfish, *Heteropneustes fossilis* (siluriformes, heteropneustidae). *Acta Toxicol Argent* 2010;18:5-9.
25. Srivastav AK, Srivastava S, Mishra D, Srivastav S, Suzuki N. Effects of deltamethrin on serum calcium and corpuscles of Stannius of freshwater catfish, *Heteropneustes fossilis*. *Toxicol Environ Chem* 2009;91(4):761-72.
26. Srivastav AK, Srivastava SK, Tripathi S, Mishra D, Srivastav SK. Chlorpyrifos-based commercial formulation: alterations in corpuscles of Stannius of catfish. *Int J Environ Health* 2010;4(4):323-32.
27. Mishra D, Srivastav S, Suzuki N, Srivastav Ajai K. Corpuscles of Stannius of a freshwater teleost, *Heteropneustes fossilis* in response to metacid-50 treatment. *J Applied Sci Environ Manage* 2009;13:69-77.
28. Mishra D, Tripathi S, Srivastav SK, Suzuki N, Srivastav AK. Corpuscles of Stannius of a teleost, *Heteropneustes fossilis* following intoxication with pyrethroids (cypermethrin). *North-Western J Zool* 2010;6(2):203-8.
29. Meats M, Ingleton P, Jones IC, Garland H, Kenyon C. Fine structure of the corpuscles of Stannius of the trout, *Salmo gairdneri*: Structural changes in response to increased environmental salinity and calcium ions. *Gen Comp Endocrinol* 1978;36(4):451-61.
30. Bonga SW. Effect of synthetic salmon calcitonin and low ambient calcium on plasma calcium, ultimobranchial cells, Stannius bodies, and prolactin cells in the teleost *Gasterosteus aculeatus*. *Gen Comp Endocrinol* 1980;40(1):99-108.
31. Pang PK, Pang RK. Hormones and calcium regulation in *Fundulus heteroclitus*. *Am Zool* 1986;26(1):225-34.
32. Singh S. Thesis for Ph.D. Studies of endocrine glands regulating calcium and inorganic phosphorus homeostasis in *Heteropneustes fossilis*, University of Gorakhpur, Gorakhpur, India. 1990.
33. Tiwari PR. Thesis for Ph.D. Endocrinal regulation of calcium in teleost, University of Gorakhpur, Gorakhpur, India. 1993.
34. Tseng D-Y, Chou M-Y, Tseng Y-C, Hsiao C-D, Huang C-J, Kaneko T, et al. Effects of stanniocalcin 1 on calcium uptake in zebrafish (*Danio rerio*) embryo. *Am J Physiol Reg Int Comp Physiol* 2009;296(3):R549-R57.
35. SINGH S, Kumar A. Vitamin D3-Induced Histological Changes in the Corpuscles of Stannius of a Freshwater Catfish, *Heteropneustes Fossilis* Kept Either in Artificial Freshwater, Calcium-rich Freshwater or Calciumdeficient Freshwater. *Okajimas Folia Anat Jpn* 1996;73(2-3):75-81.
36. Gittes RF, Toverud SV, Cooper CW. Effects of hypercalcemia and hypocalcemia on the thyrocalcitonin content of rat thyroid glands. *Endocrinol* 1968;82(1):83-90.
37. Leitz H, Donath K. Cytochemical evidence for the presence of hormonal peptides in thyroid C cells. London: William Heinemann Medical Books Ltd; 1970.p. 227-39.
38. Biddulph DM, Maibenco HC. Response of hamster thyroid light cells to plasma calcium. *Anat Rec* 1972;173(1):25-43.
39. Swarup K, Tewari N, Srivastav AK. Response of calcitonin cells, parathyroid glands and bone to prolonged calcitonin administration in the Indian palm squirrel, *Funambulus pennanti* (Wroughton). *Cells Tissues Organs* 1980;106(2):180-91.