

Comparing the Apical Microleakage of Lateral Condensation and Chloroform Dip Techniques with a New Obturation Method

Masoud Saatchi¹, Behnaz Barekatin², Masoumeh Behzadian³

ABSTRACT

Background: The final objective of root canal therapy is to create a hermetic seal along the length of the root canal system. For this purpose, many methods and materials have been introduced. The purpose of this study was to compare the apical microleakage in a new obturation technique (true-tug-back) with two other obturation techniques (lateral condensation and chloroform dip technique).

Methods: In this *in vitro* study 102 single canal teeth were selected. The crowns were removed, and the canals were prepared using step-back technique. The master apical file was K-file #40. The teeth were divided into 3 experimental groups of 32 teeth. First group were obturated with lateral condensation technique and second group with chloroform dip technique and the third group with true-tug-back technique. Six teeth were used as control group. The teeth were placed in incubator at 100% humidity and 37°C for three days. The roots of the teeth were coated with two layers of nail varnish except for the apical 2 millimeter. Teeth were placed in Methylene blue 2% for one week. The teeth were sectioned vertically and the depth of maximum dye penetration for each tooth was recorded by stereomicroscope. Data were analyzed using ANOVA and Duncan test.

Results: The mean liner dye penetration differences between lateral condensation group (6.88 ± 4.06 mm) and chloroform dip technique group (7.16 ± 3.37 mm) were not statistically significant ($P = 0.719$). The differences between true-tug-back group (3.15 ± 0.52 mm) and two other groups were statistically significant ($P < 0.001$).

Conclusion: The results of this study showed that the true-tug-back technique can improve apical seal. Further studies are needed for this purpose.

Keywords: Chloroform dip technique, Lateral condensation, Microleakage, Obturation.

Received: August 2010

Accepted: December 2010

Dent Res J 2011; 8(1): 22-27

Introduction

The obturation of root canal system needs a lot of attention.¹ Many failures in root canal treatment in long term are related to incomplete obturation.² A good filling should be perfectly dense and creates a complete seal in all three dimensions of the root canal.³

Root canal obturation should be ended to the apical constriction.^{4,5} Many obturation techniques and

equipments are presented so far to enhance and improve the quality of root canal seal. These include cold lateral condensation⁶, vertical condensation⁷, obtura II⁸, System B⁹, Ultrafill¹⁰, Thermafill¹¹, Successfill¹², Simplifill¹³, thermomechanical condensation¹⁴, and chloroform dip technique¹⁵. Lateral condensation technique is one of the most common methods of root canal obturation. In conventional

* This paper derived from a dissertation with the project No 384002 in Isfahan University of Medical Sciences.

¹ Associate Professor, Department of Endodontics and Torabinejad Dental Research Center, School of Dentistry, Isfahan University of Medical Sciences, Isfahan, Iran.

² Assistant Professor, Department of Endodontics and Torabinejad Dental Research Center, School of Dentistry, Isfahan University of Medical Sciences, Isfahan, Iran.

³ Dental Student, School of Dentistry, Isfahan University of Medical Sciences, Isfahan, Iran.

Correspondence to: Behnaz Barekatin, Email: barekatin@dnt.mui.ac.ir

obturation methods, the tug-back in the gutta-percha master cone is recommended in order to create and maintain the apical seal.^{16,17} Tug-back is the slight back-pull or resistance to dislodgement of the gutta-percha master cone that is felt when it is removed from the canal. If coming from the apical third, this tug-back would be an indication of good fit.¹⁸ Although tug-back is necessary to obturate the root canal, in some cases there are possibility of errors to fit the gutta-percha master cone into the 1 to 3 mm end of the root canal. These include; (i) in apexification cases that have large diameter at the end of the canal (Blunder Buss); (ii) in recently completed tooth apex (young teeth) the shape of canal in transverse plan is oval, so the fitting of gutta-percha master cone in the apical portion of the canal is only on two plan: (iii) despite canal preparation, there are some irregularities in the inner surface of the root. The gutta-percha master cone cannot fit in to these irregularities.

Chloroform dip technique is one of the methods to increase adaptation of gutta-percha master cone at the end of root canal. In this technique, the terminal 3 mm of gutta-percha master cone is placed in chloroform for 1 second and then compressed in to the canal. Then after 25 seconds it is emitted, covered with sealer and replaced into the root canal. Finally, the root canal is obturated using lateral condensation technique.¹⁹ Chloroform dip technique disadvantages include (i) irritating periapical tissue by chloroform²⁰ (ii) Chloroform affected gutta-percha to contract due to evaporation of excess chloroform (iii) disruption in adaptation of gutta-percha master cone as a result of emitting and again replacing gutta-percha into the root canal.

True-tug-back technique is a new described obturation method in which the heat is used instead of chloroform to make the end of the gutta-percha master cone soft. Therefore it does not have the disadvantages of chloroform dip technique. In this method, the gutta-percha master cone is selected so as to enter the root canal at the working length and not having primary adaptation (tug-back) at apical portion of root canal. Root canal is covered with sealer. The tip of a burnisher is heated until it turns red. The end of the gutta-percha master cone is held within one millimetre of the heated burnisher's tip for a second (Figure 1). Then immediately the gutta-percha master cone is interned into the canal so as its end which has become soft by heat is compressed in to the end of the canal (Figure 2). The rest of the canal is obturated using lateral condensation technique.

The purpose of this study was to compare the apical microleakage in a new obturation technique (true-tug-back) with lateral condensation and chloroform dip techniques.

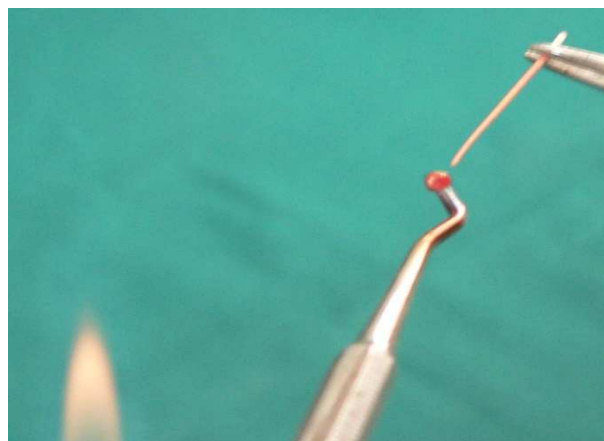


Figure 1. The end of the gutta-percha master cone is held within one millimetre of the heated burnisher's tip for a second.

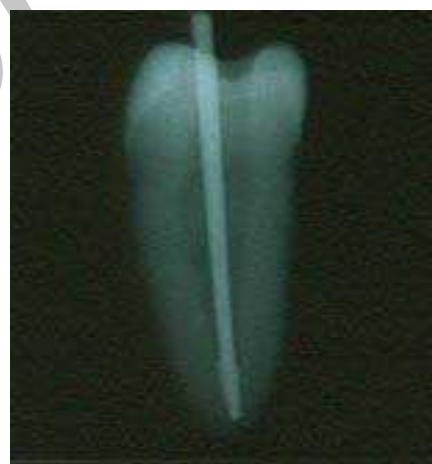

Figure 2. The heated gutta-percha master cone is interned and compressed in to the canal.

Materials and Methods

In this *in vitro* study, 102 single canal teeth were selected. The following inclusion criteria were applied to select the teeth: not having extensive root caries, calcification, internal resorption, severe curvature, open apex and having the first file at least equal to file number 20. The teeth were placed in 5.25% sodium hypochlorite solution, and then the soft periodontal tissues on the root surface were removed by periodontal curette and the teeth were kept in the normal saline. To ensure teeth having the entry requirement to the study, the initial radiographs were taken. The teeth crown were cut by

diamond disk (D&Z, Germany); to measure the working length, first the file #15 (MANI, Japan) was placed within the canal to the extent that the file tip was visible from the end of the apex. Then the working length was determined as one millimetre shorter than this size. Using the step-back technique, root canal prepared to the master apical file #40 and flared to the file #80. Gates Glidden #1, 2, and 3 (MANI, Japan) were used for coronal enlargement. File #10 was used as apical patency file. Sodium hypochlorite 2.5% was used as irrigation during each file exchange. Then the root canals were dried using paper point (Aria, Iran). Teeth were randomly divided into three experimental groups of 32 and two positive and negative control groups of 3.

Group one: including 32 teeth, gutta-percha master cone (DiaDent, Korea) with tug-back was selected. After that the canals were obturated by lateral condensation technique and AH₂₆ sealer (De Trey, Konstant, Germany). Tug-back in gutta-percha master cone was confirmed by tactile sense. The length of gutta-percha master cone was confirmed by direct observation and radiography.

Group two: including 32 teeth, the gutta-percha master cone with its length 1 to 1.5 mm shorter than the working length was selected. Terminal 1-3 mm of the gutta-percha master cone was placed in chloroform for 1 second and then compressed into the canal. After 25 seconds the gutta-percha master cone was removed, covered with sealer and was placed back in the canal again. Then obturation was continued using lateral condensation technique.

Group three: including 32 teeth; gutta-percha master cone was selected either without a tug-back or a poor tug-back. It was covered with sealer, and then the end of the gutta-percha master cone was held within one millimetre of the tip of a heated DFO 22 burnisher (Aesculap, USA) for a second and finally was compressed into the canal that already was covered with sealer. Then obturation was continued using lateral condensation technique. The

final radiographs of each sample were taken to assess the obturation of the canals.

Gutta-percha was removed from 2 mm coronal portion of the canal by heat carrier and temporary filling material (Coltene, Switzerland) was placed inside the cavity. Teeth were kept in the incubator at 100% humidity and 37°C for 3 days to set the sealer.

Then in the three experimental groups and positive control group the root surfaces were coated by two layers of nail polish and a wax layer, except from 2 mm of the apex. In negative control group the whole root surfaces were coated by two layers of nail polish and a wax layer. In positive and negative control groups the root canals were not filled by gutta-percha. All teeth were immerse in methylene blue 2% and kept in incubator at 37 °C for a week. Then the teeth were cut into two pieces by diamond disk (D&Z, Germany) in buccolingual direction. Stereomicroscope with 8 initial magnifications was used to measure the longitudinal penetration of methylene blue into the root canal. The length of dye penetration was measured in millimetre by two people who did not know the groups. The average was recorded. Data were analyzed using ANOVA and Duncan tests.

Results

In all samples tested there were varying degrees of dye penetration. In most cases, the dye penetration was created between the sealer and the root canal dentin wall. The mean and standard deviation of dye penetration in the three experimental groups are shown in Table 1. There were significant differences between the true-tug-back group and two other groups ($P < 0.001$). The difference between the lateral condensation group and the chloroform dip technique group was not significant ($P = 0.719$). In the positive control group, there was dye penetration throughout the whole root canal. In the negative control group, no dye penetration was found into the root canal.

Table 1: The mean and standard deviation (SD) of dye penetration in three experimental groups (mm)

Groups	Number	Mean	SD	Minimum	Maximum
Lateral Condensation	32	6.88	4.067	1.55	9.53
Chloroform Dip Technique	32	7.16	3.360	3.35	10.87
True Tug Back	32	3.15	0.523	2.25	4.10

Discussion

Almost 60 percent of endodontics failure is due to incomplete obturation.²¹ Many endodontic studies are on equipment, materials and methods which can improve the seal of root canal.²² Some methods such as dye penetration²³, radioisotopes²⁴, bacterial penetration²⁵, fluid infiltration²⁶, electrochemical²⁷, tomography²⁸, autoradiography²⁹ and electron microscopy³⁰ are used for microleakage study and evaluate the quality of root canal sealing. In this study, dye penetration method was used. Although some researchers believe that the dye's particle size or emulsion of the coloured solutions used are much smaller than the size of microorganisms or their products, and this may show a higher amount of leakage compare to the one shown in the clinical conditions, Torabinejad et al.³¹ believe that when a filler material does not let the passage of dye small molecules, this can also prevent the larger molecules such as bacteria and their products to permeate. Kucakayi et al.³² determined using centrifuge does not have any effect in dye penetration into the root canal. In our study centrifuge was not used. During the root canal obturation, the gutta-percha master cone should fit in to the 1 to 3 mm end of the canal walls. This adaptation creates a slight back-pull or resistance that is felt when removing the gutta-percha master cone from the canal which is called "tug-back". Allison et al.³³ studied the effect of the gutta-percha master cone fitness on the canal apical seal. In their study, the presence or absence of the tug-back had no effect on the apical seal. This result may be due to not use of patency file in their study. If patency file is not used, the apical preparation is in form of apical stop. Saatchi et al.³⁴ showed that tug-back is effective on enhancing of the apical seal, noting that, in this research patency file was used.

It is expressed that chloroform dip technique is one of the methods to improve master cone adaptation and increase the apical seal. Smith et al.¹⁵ concluded that the chloroform dip technique does not affect the quality of apical seal. Yanicich et al.³⁵ compared apical seal in lateral condensation technique, chloroform dip technique and eucalyptol dip technique. They did not find any significant difference between the groups. In their study as well as our study, the poor results obtained in sealing ability of chloroform dip technique could be due to contraction of gutta-percha after the chloroform evaporated. Kerezoudis et al.³⁶ suggested using the heat, to improve the gutta-percha master cone fitness into

the end of root canal. In their method the tip of gutta-percha master cone was connected to the tip of a heated metal spatula before placing into the root canal. Thus, the tip of gutta-percha master cone softens by heat. The drawback of this method is in connecting the tip of gutta-percha to the heated spatula. Direct contact of the gutta-percha with hot spatula produces very high and uncontrolled heat to the tip of gutta-percha. It can change the structure of gutta-percha from the beta phase to amorphous phase which is irreversible. The true-tug-back technique has the following advantages:

- 1) This method does not require sophisticated equipment and is easy to use.
- 2) Since in this method the gutta-percha is not directly heated but held within one millimetre to the tip of a heated burnisher for a second, therefore the heat into the gutta-percha is controlled
- 3) In this way, only the terminal 1 to 2 mm of the gutta-percha is softened by the heat, so the main part of the gutta-percha remains hard and therefore the softened end of gutta-percha can be compressed well in to the end of root canal.
- 4) Unlike chloroform dip techniques, in this method, there is no need for the gutta-percha master cone to be removed after placing it inside the root canal so adaptation of gutta-percha into the end of the canal will not be affected.
- 5) In cases where spreader may not initially enter the canal properly, such as severed curved root canals or long canals with a low degree of tapering, this method can have better results.

Based on the results of this study, it is concluded that the true-tug-back technique could improve the apical seal of the root canal. Further studies are required to confirm these findings.

Acknowledgment

This article is the outcome of the dissertation with the project number 384002 in Isfahan University of Medical Sciences. The Deputy Research of the Dental Schools's sponsorship is appreciated.

References

1. Farzaneh M, Abitbol S, Friedman S. Treatment outcome in endodontics: the Toronto study. Phases I and II: Orthograde retreatment. *J Endod* 2004; 30(9): 627-33.

2. Vire DE. Failure of endodontically treated teeth: classification and evaluation. *J Endod*.1991; 17(7): 338-42.
3. Hammad M, Qualtrough A, Silikas N. Evaluation of root canal obturation: a three-dimensional in vitro study. *J Endod* 2009; 35(4): 541-4.
4. Tamarut T, Kovacevic M, Glavicic S. Influence of the length of instrumentation and canal obturation on the success of endodontic therapy. A 10-year clinical follow-up. *Am J Dent* 2006; 19(4): 211-6.
5. Schaeffer MA, White RR, Walton RE. Determining the optimal obturation length: a meta-analysis of literature. *J Endod* 2005; 31(4): 271-4
6. Hembrough MW, Steiman HR, Belanger KK. Lateral condensation in canals prepared with nickel titanium rotary instruments: an evaluation of the use of three different master cones. *J Endod* 2002; 28(7): 516-9.
7. Peng L, Ye L, Tan H, Zhou X. Outcome of root canal obturation by warm gutta-percha versus cold lateral condensation: a meta-analysis. *J Endod* 2007; 33(2): 106-9.
8. Yilmaz Z, Deniz D, Ozcelik B, Sahin C, Cimilli H, Cehreli ZC, et al. Sealing efficiency of BeeFill 2in1 and System B/Obtura II versus single-cone and cold lateral compaction techniques. *Oral Surg Oral Med Oral Pathol Oral Radiol Endod* 2009; 108(6): e51-5.
9. De-Deus G, Maniglia-Ferreira CM, Gurgel-Filho ED, Paciornik S, Machado AC, Coutinho-Filho T. Comparison of the percentage of gutta-percha-filled area obtained by Thermafil and System B. *Aust Endod J* 2007; 33(2): 55-61.
10. Gencoglu N, Samani S, Gunday M. Evaluation of sealing properties of Thermafil and Ultrafil techniques in the absence or presence of smear layer. *J Endod* 1993; 19(12): 599-603.
11. Gencoglu N. Comparison of 6 different gutta-percha techniques (part II): Thermafil, JS Quick-Fill, Soft Core, Microseal, System B, and lateral condensation. *Oral Surg Oral Med Oral Pathol Oral Radiol Endod* 2003; 6(1) 91-5
12. Goldberg F, Massone EJ, Artaza LP. Comparison of the sealing capacity of three endodontic filling techniques. *J Endod* 1995; 21(1): 1-3.
13. Gopikrishna V, Parameswaren A. Coronal sealing ability of three sectional obturation techniques--SimpliFill, Thermafil and warm vertical compaction--compared with cold lateral condensation and post space preparation. *Aust Endod J* 2006; 32(3): 95-100.
14. Boussetta F, Bal S, Romeas A, Boivin G, Magloire H, Farge P. In vitro evaluation of apical microleakage following canal filling with a coated carrier system compared with lateral and thermomechanical Gutta-Percha condensation techniques. *Int Endod J* 2003; 36(5): 367-71.
15. Smith JJ, Montgomery S. A comparison of apical seal: chloroform versus halothane-dipped gutta-percha cones. *J Endod* 1992; 18(4): 156-60.
16. West JD. The cone fit: an essential step to creating exceptional endodontic obturation. *Dent Today* 2005; 24(5): 102-5.
17. Moule AJ, Kellaway R, Clarkson R, Rowell J, Macfarlane R, Lewis D, et al. Variability of master gutta-percha cones. *Aust Endod J* 2002; 28(1): 38-43.
18. Sadeghain A, Farhadian F. Invitro Study of the Effect of Tug-Back on apical seal. *Journal of Tehran Dental Medicine* 1998; 17: 51-8.
19. Stock C, Walker R, Gulabivala K. *Endodontics*. 3rd ed. St. Louis: Mosby Co; 2004.p. 186.
20. Chutich MJ, Kaminski EJ, Miller DA, Lautenschlager EP. Risk assessment of the toxicity of solvents of gutta-percha used in endodontic retreatment. *J Endod* 1998; 24(4): 213-6.
21. de Chevigny C, Dao TT, Basrani BR, Marquis V, Farzaneh M, Abitbol S, et al. Treatment outcome in endodontics: the Toronto study--phase 4: initial treatment. *J Endod* 2008; 34(3): 258-63.
22. Nawal RR, Parande M, Sehgal R, Rao NR, Naik A. A comparative evaluation of 3 root canal filling systems. *Oral Surg Oral Med Oral Pathol Oral Radiol Endod* 2011; 111(3): 387-93.
23. Chailertvanitkul P, Abbott PV, Riley TV, Sooksuntisakoonchai N. Bacterial and dye penetration through interim restorations used during endodontic treatment of molar teeth. *J Endod* 2009; 35(7): 1017-22.
24. Clark DM, del Rio CE. Radioisotope determination of apical seal integrity of silver point-filled endodontic teeth after ultrasonic vibration. *Oral Surg Oral Med Oral Pathol* 1977; 43(5): 771-7.
25. Jalalzadeh SM, Mamavi A, Abedi H, Mashouf RY, Modaresi A, Karapanou V. Bacterial microleakage and post space timing for two endodontic sealers: an in vitro study. *J Mass Dent Soc* 2010; 59(2): 34-7.
26. Vasiliadis L, Kodonas K, Economides N, Gogos C, Stavrianos C. Short- and long-term sealing ability of Gutta-flow and AH-Plus using an ex vivo fluid transport model. *Int Endod J* 2010; 43(5): 377-81.
27. Inan U, Aydemir H, Tasdemir T. Leakage evaluation of three different root canal obturation techniques using electrochemical evaluation and dye penetration evaluation methods. *Aust Endod J* 2007; 33(1): 18-22.
28. Zaslansky P, Fratzl P, Rack A, Wu MK, Wesselink PR, Shemesh H. Identification of root filling interfaces by microscopy and tomography methods. *Int Endod J* 2011; in press.

29. Ximenez-Fyvie LA, Ximenez-Garcia C, Carter-Bartlett PM, Collado-Webber FJ. Accuracy of endodontic microleakage results: autoradiographic vs. volumetric measurements. *J Endod* 1996; 22(6): 294-7.
30. Zhang W, Li Z, Peng B. Assessment of a new root canal sealer's apical sealing ability. *Oral Surg Oral Med Oral Pathol Oral Radiol Endod* 2009; 107(6): e79-82.
31. Torabinejad M, Watson TF, Pitt Ford TR. Sealing ability of a mineral trioxide aggregate when used as a root end filling material. *J Endod* 1993; 19(12): 591-5.
32. Karagoz-Kucukay I, Kucukay S, Bayirli G. Factors affecting apical leakage assessment. *J Endod* 1993; 19(7): 362-5.
33. Allison DA, Michelich RJ, Walton RE. The influence of master cone adaptation on the quality of the apical seal. *J Endod* 1981; 7(2): 61-5.
34. Saatchi M, Rostami F. An invitro study of the influence of "tug-back" on the apical seal in root canal therapy. *Journal of Dentistry Mashhad University of Medical Sciences* 2006; 30: 65-70
35. Yancich PP, Hartwell GR, Portell FR. A comparison of apical seal: chloroform versus eucalyptol-dipped gutta-percha obturation. *J Endod* 1989; 15(6): 257-60.
36. Kerezoudis NP, Valavanis D, Prountzos F. A method of adapting gutta-percha master cones for obturation of open apex cases using heat. *Int Endod J* 1999; 32(1): 53-60.

Archive of SID