

Original Article

The effect of fluoride varnish and chlorhexidine gel on white spots and gingival and plaque indices in fixed orthodontic patients: A placebo-controlled study

Shiva Alavi¹, Navid Yaraghi²

¹Department of Orthodontics, Dental Materials Research Center, School of Dentistry, Isfahan University of Medical Sciences, ²Department of Orthodontics, School of Dentistry, Isfahan University of Medical Sciences, Isfahan, Iran

ABSTRACT

Background: Difficulties to maintain good oral hygiene during orthodontic treatment can cause prolonged accumulation of dental plaque, thereby increasing the risk of developing gingival inflammation and periodontal disease as well as enamel demineralization and caries. The purpose of this study was to determine the effect of chlorhexidine (CHX) gel and fluoride varnish versus placebo and control groups on plaque and gingival indices as well as their influence on enamel demineralization prevention in orthodontic patients with fixed appliances.

Materials and Methods: In this clinical trial, forty patients with fixed orthodontic appliances were participated and were divided into control, CHX gel (0.2%), fluoride varnish (5%), and placebo groups. The parameters evaluated in this research were dental plaque index (DPI), index of gingival inflammation, and white spot lesion (WSL) index. For all the patients, each index was scored at the beginning of orthodontic treatment, then 3 months, 6 months, and 9 months afterward. Data were analyzed using Kruskal–Wallis and Mann–Whitney tests. The level of significance was set at 0.05.

Results: All the scores showed statistically significant differences ($P < 0.05$) between the four groups for each of the three time points. A statistically significant decrease of DPI, WSL index, and gingival index was observed 9 months after treatment in fluoride and CHX groups.

Conclusion: Adding CHX gel and fluoride varnish to the patients’ oral hygiene regimen can reduce the development of plaque and gingivitis and decrease WSLs in orthodontic patients.

Key Words: Chlorhexidine, dental plaque index, orthodontic appliance, periodontal index, white spot

Received: October 2017
Accepted: March 2018

Address for correspondence:
Dr. Navid Yaraghi,
Department of
Orthodontics, School of
Dentistry, Isfahan University
of Medical Sciences, Isfahan,
Iran.
E-mail: navidiyaraghi@
yahoo.com

INTRODUCTION

Dental caries is one of the most important oral cavity diseases, which initially appears as a white spot lesion (WSL) due to the loss of mineral content.^[1] After the introduction of orthodontic fixed appliances into the oral cavity, some rapid ecologic changes such as increase of *Streptococcus mutans* have been reported

in the saliva and plaque of patients.^[2] Prevention of demineralization and occurrence of new carious lesions in orthodontic patients is rather difficult. Besides, good oral hygiene and regular supplementation techniques are often needed.^[3,4]

This is an open access journal, and articles are distributed under the terms of the Creative Commons Attribution-NonCommercial-ShareAlike 4.0 License, which allows others to remix, tweak, and build upon the work non-commercially, as long as appropriate credit is given and the new creations are licensed under the identical terms.

For reprints contact: reprints@medknow.com

How to cite this article: Alavi S, Yaraghi N. The effect of fluoride varnish and chlorhexidine gel on white spots and gingival and plaque indices in fixed orthodontic patients: A placebo-controlled study. Dent Res J 2018;15:276-82.

Access this article online	
	<p>Website: www.drj.ir www.drjjournal.net www.ncbi.nlm.nih.gov/pmc/journals/1480</p>

After bracket placement, WSLs can be identified within 1 month although it takes at least 6 months before caries becomes notable.^[4] These lesions are predominantly in sites adjacent to brackets and are usually formed at the buccal surfaces, especially in the gingival region.^[5,6] Plaque also harbors the cariogenic bacteria, potentially capable of hard tissue damage, especially at the bracket margins.^[7]

Mechanical and chemical cleaning of tooth surface with regular brushing and mouth rinses can help reduce plaque formation and accumulation; therefore, it prevents gingival and dental diseases during orthodontic appliance therapy.^[8] Good plaque control is very difficult in patients with fixed orthodontic appliances. To improve mechanical plaque removal, incorporation of a chemotherapeutic agent such as an antibacterial mouth rinse into the oral hygiene regimen can be helpful.^[9,10]

Chlorhexidine (CHX) is the most potentially documented antimicrobial agent against mutans streptococci (MS) and dental caries. Different modes of administration are recommended for caries prevention.^[11-13] The form that CHX is delivered such as varnishes, gels, and rinsing solutions determines the mode of its effect. The contact time of CHX with intraoral tissues, its concentration and rate of release, are factors affecting its persistence of bacterial suppression. Depending on these particular factors, CHX varnishes establish the most persistent reduction in MS, followed by gels and mouthwashes.^[14,15] Studies have shown that a long-lasting suppression of MS concentrations can be achieved by application of CHX varnishes and gels compared with other forms of application.^[16,17] High and low concentrations have been reported to reduce the number of MS in plaque and saliva for considerable periods of time.^[18,19] The safety of CHX has been reportedly confirmed although a drawback of CHX is the associated staining of pellicle. The effect of subgingival irrigation with CHX on gingivitis in adolescents with fixed orthodontics has been reported by Morrow *et al.*^[20]

Topical application of fluoride varnish at least around anterior teeth is suggested in high-risk patients, for example, for orthodontic patients at every orthodontic adjustment appointment.^[21] However, the most recommended type of fluoride by orthodontists is daily use of 0.05% sodium fluoride rinse in conjunction with fluoridated dentifrice.^[22] Perhaps, this recommendation was based on the research done

on nonorthodontic adolescent patients, suggesting that this approach may significantly help reduce caries rates. Further, the efficacy of fluoride rinses in WSL prevention in patients undergoing orthodontic treatment is questionable, and there is weak and mixed evidence on this topic. Moreover, it should be noted that patients' compliance with such rinses is poor.^[23] There is evidence regarding the ability of amorphous calcium phosphate (ACP) in remineralization of WSL after orthodontic treatment. Some studies have reported no significant advantage for the use of ACP along with regular oral hygiene regimen including 1,000 ppm fluoride toothpaste.^[24,25]

Plaque accumulation which can lead to WSL formation and gingival inflammation represent a significant challenge to excellence in clinical orthodontics. The risk assessment methods and finding the best preventive materials may help to minimize this common problem in your patients; however, no matter how hard we strive, it is unlikely that this problem can be completely eliminated. For this reason, it is imperative for both orthodontists and general practitioners to have consistent protocols for caries risk assessment, prevention, intratreatment management, and treatment of WSL.

The purpose of this study was to evaluate the effect of CHX and fluoride varnishes on plaque and gingival indices as well as their efficiency in preventing demineralization in orthodontic patients with fixed appliances. An attempt was also made to compare the results of these groups with control and placebo groups.

MATERIALS AND METHODS

This clinical trial included 40 patients (20 females and 20 males), who were treated in the Department of Orthodontics of Dental School, Isfahan University of Medical Sciences. This trial is registered with IRCT registry ID: IRCT2016122531558N1. The participants were selected based on simple sampling and were randomly divided into four groups. The participants were qualified on the basis of the following criteria:

- Having orthodontic appliances in both jaws and undergoing a nonextraction orthodontic therapy
- Aged over 18
- Showing no allergic reaction to the materials used
- No history of previous orthodontic therapies
- No systematic diseases affecting teeth such as

amelogenesis and dentinogenesis imperfecta

- No systematic diseases affecting gum inflammation such as lichen planus and pemphigus
- No clinical evidence of periodontal diseases
- No medical problems or evidence of current antibiotic therapy or using drugs affecting salivary secretion.

Patients who did not follow the given oral hygiene instructions were excluded from this study (To exclude the patients who did not follow the oral hygiene program, participants were questioned each session).

The study population had a mean age of 23 years (range: 18–34). The patients were divided into control group ($n = 10$), CHX group ($n = 10$), fluoride group ($n = 10$), and placebo group ($n = 10$).

Clinical procedures

Before the beginning of examination, all of the selected volunteers were instructed on toothbrushing technique (bass technique) and flossing.

As shown, teeth were selected based on proposed method for plaque and gingival index (GI) and white spot by Silness and Loe:

Preparations

Prophylaxis

For all groups before varnish administration, plaque removal was done using toothbrush and toothpaste. Tested materials were applied to teeth surfaces around brackets, and patients were asked not to drink or eat anything for 2 h.

Bonding

All the brackets were bonded with nonfluoride adhesives according to standard procedures.

Clinical measurements

The materials used were CHX varnish (0.2%, Periokin, Spain), sodium fluoride varnish alcohol free (5%, Pascal, America) and 70% Wt% sorbitol solution for placebo group. They were applied in every 3 months.

The following parameters, including dental plaque index (DPI) of Silness-Löe and GI and index of gingival inflammation of Löe and Silness, were recorded at baseline (day 0), and after 3, 6, and 9 months.^[26]

The WSL index was assessed using the International Caries Detection and Assessment System (ICDAS).^[27]

ICDAS was also recorded through visual evaluation of selected tooth at baseline (day 0) and after 3, 6, and 9 months' surfaces. The scoring was performed as follows: (0) no visible WSL or surface disruption (no demineralization); (1) visible WSL covering less than one-third of the surface, without surface disruption (mild demineralization); (2) visible WSL covering more than one-third of the surface, with a roughened surface but not requiring restoration (moderate demineralization), and (3) visible cavitation, requiring restoration (severe demineralization).^[28]

Statistical analysis

Continuous variables were expressed as mean \pm standard deviation (SD), and *t*-test was used to compare the means among groups. Data were analyzed using Kruskal–Wallis and Mann–Whitney tests. SPSS version 21 (SPSS Inc., Chicago, Illinois, USA) was used for data analysis. $P \leq 0.05$ was considered statistically significant for all analyses.

RESULTS

A total of 40 (20 male, 20 female) orthodontic patients aged 18–34 years (mean \pm SD = 23.53 \pm 4.5) were included in this study and assigned into four subgroups of 10 (5 males, 5 females).

Descriptive statistics for DPI, GI, and WSL index in control and experimental groups (placebo, CHX, and fluoride) at each of the four time intervals are illustrated in Table 1.

The frequency rates of patients with WSLs at the beginning and after 3, 6, and 9 months of treatment are presented in Table 2.

Figures 1-3 display significant differences between the examined and control groups for the WSL index, DPI, and GI scores in the four time points (baseline, after 3, 6, and 9 months).

The results of Kruskal–Wallis test showed significant changes in all three indices and all groups after the 9-month period ($P < 0.05$).

After using fluoride and CHX for 9 months, GI decreases significantly ($P < 0.05$) while the changes in placebo and control groups were not statistically significant.

Based on the results of Mann–Whitney test, a significant decrease in plaque was observed when

Table 1: Descriptive statistics for dental plaque index, gingival index, and white spot lesion index in control and examined groups (placebo, chlorhexidine, and fluoride) at the beginning, after 3, 6, and 9 months

Group	Index	Mean±SD	Index	Mean±SD	Index	Mean±SD
Chlorhexidine	DPI (0)	0.235±0.11	WSL (0)	1.500±0.52	GI (0)	0.155±0.15
	DPI (3)	0.123±0.13	WSL (3)	1.200±0.42	GI (3)	0.056±0.06
	DPI (6)	0.009±0.01	WSL (6)	1.100±0.31	GI (6)	0.035±0.07
	DPI (9)	0.003±0.06	WSL (9)	1.100±0.00	GI (9)	0.014±0.03
Placebo	DPI (0)	0.269±0.14	WSL (0)	1.100±0.31	GI (0)	0.028±0.06
	DPI (3)	0.245±0.21	WSL (3)	1.300±0.48	GI (3)	0.042±0.07
	DPI (6)	0.173±0.16	WSL (6)	1.300±0.67	GI (6)	0.052±0.11
	DPI (9)	0.109±0.16	WSL (9)	1.200±0.63	GI (9)	0.028±0.06
Fluoride	DPI (0)	0.058±0.16	WSL (0)	1.400±0.51	GI (0)	0.107±0.14
	DPI (3)	0.233±0.22	WSL (3)	1.100±0.31	GI (3)	0.056±0.07
	DPI (6)	0.215±0.18	WSL (6)	1.200±0.42	GI (6)	0.012±0.02
	DPI (9)	0.249±0.21	WSL (9)	1.000±0.00	GI (9)	0.002±0.00
Control	DPI (0)	0.212±0.17	WSL (0)	1.100±0.31	GI (0)	0.043±0.08
	DPI (3)	0.198±0.18	WSL (3)	1.100±0.31	GI (3)	0.066±0.13
	DPI (6)	0.142±0.17	WSL (6)	1.100±0.31	GI (6)	0.075±0.13
	DPI (9)	0.135±0.18	WSL (9)	1.300±0.48	GI (9)	0.045±0.09

DPI: Dental plaque index; GI: Gingival index; WSL: White spot lesion; SD: Standard deviation

Table 2: Frequency of patients with white spot lesions at the beginning, 3, 6, and 9 months after treatment

Group	WSL (time intervals)	0 (%)	1 (%)	2 (%)	3 (%)
Control	WSL (0)	0	9 (90)	1 (10)	0
	WSL (3)	0	9 (90)	1 (10)	0
	WSL (6)	0	9 (90)	1 (10)	0
	WSL (9)	0	7 (70)	3 (30)	0
Fluoride	WSL (0)	0	6 (60)	4 (40)	0
	WSL (3)	0	9 (90)	1 (10)	0
	WSL (6)	0	8 (80)	2 (20)	0
	WSL (9)	0	10 (100)	0	0
Placebo	WSL (0)	0	9 (90)	1 (10)	0
	WSL (3)	0	7 (70)	3 (30)	0
	WSL (6)	0	8 (80)	1 (10)	1 (10)
	WSL (9)	0	9 (90)	0	1 (10)
Chlorhexidine	WSL (0)	0	5 (50)	5 (50)	0
	WSL (3)	0	8 (80)	2 (20)	0
	WSL (6)	0	9 (90)	1 (10)	0
	WSL (9)	0	10 (100)	0	0

WSL: White spot lesion

comparing CHX with control ($P = 0.00$) and CHX with placebo ($P = 0.03$). CHX effectiveness in WSL reduction was also significant compared to control group ($P = 0.001$) and placebo group ($P = 0.009$). Furthermore, decrease in WSLs was significantly more in CHX group compared to fluoride group ($P = 0.001$). Fluoride was significantly more effective in plaque reduction compared to control group although its difference with placebo group was not significant. The only difference between control and placebo groups was observed in plaque index, being significantly lower in placebo group ($P = 0.01$).

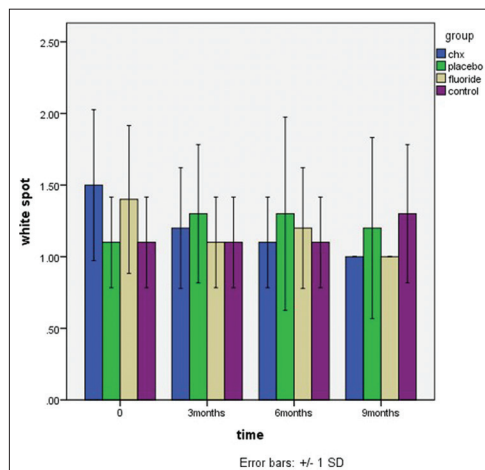


Figure 1: Mean white spot lesion values in control and examined groups (placebo, chlorhexidine, and fluoride) at time intervals.

DISCUSSION

High prevalence of dental caries, especially in high-risk patients, has made them the target of many interventions. The effect of using fluoridated toothpastes,^[29] other topically applied fluorides,^[30] fluoridated municipal water,^[31] and pit and fissure sealants^[27] in the prevention of plaque and caries still remains vague. There is controversy regarding the use of CHX for caries prevention. It has been reported that the most persistent reduction of MS can be achieved by CHX varnishes, followed by gels and mouth rinses. This evidence is rather suggestive but incomplete. Variable study designs and lack of data in high-risk

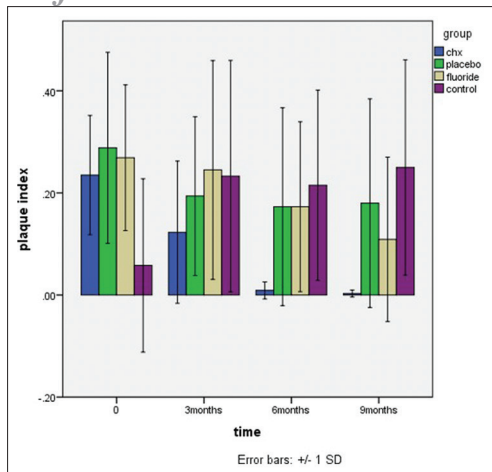


Figure 2: Mean plaque index values in control and examined groups (placebo, chlorhexidine, and fluoride) at time intervals.

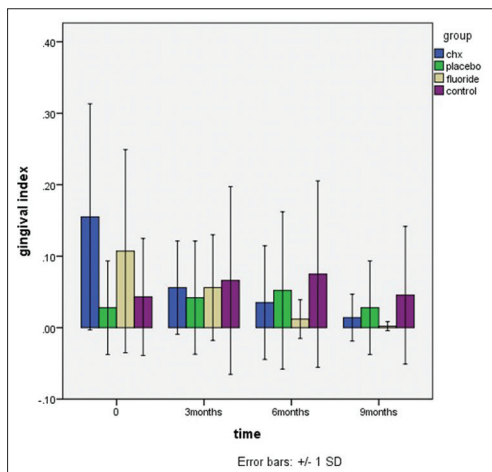


Figure 3: Mean gingival index in control and examined groups (placebo, chlorhexidine, and fluoride) at time intervals.

patients such as orthodontic patients support the need to continue conducting randomized, well-controlled clinical trials and search for a practical, effective mode of antimicrobial treatment.^[32,33]

Distinct difference has been reported in the caries-preventive effects of concentrated fluoride solutions, gels, or varnishes. Thus, several factors such as costs, convenience, patient acceptance, and safety can affect the choice of method. Fluoride varnishes are proven to be a feasible and safe approach for fluoride application. With fluoride varnishes, the amounts of fluoride exposure can be better controlled, and less chair time is required, compared with conventional solutions and gels. No dose-response effect on concentrated fluoride agents is apparent, and the benefit of frequent application is not clearly established.^[7-9]

In a systematic review done by Chen *et al.*, it was noted that there is lack of reliable evidence to support the effectiveness of remineralizing agents for the treatment of orthodontic WSLs.^[34]

In a systematic review done by Migliorati *et al.*,^[35] the efficacy of professional hygiene and prophylaxis on preventing plaque increase in orthodontic patients with multibracket appliances was assessed and it was found that an optimal oral health maintenance during orthodontic treatment should be a gold standard in today's practice; nevertheless, literature on this topic is lacking as well as high-quality studies like randomized controlled trial (RCT). Future high-quality research is recommended.

In a systematic review in 2016, the effects of CHX varnish on caries during orthodontic treatment were assessed and it was found that high-quality clinical trials to examine CHX varnish effectiveness on caries prevention during orthodontic treatment are clearly needed.^[36]

In a RCT done by Singh *et al.*,^[37] in 2016, the effects of various remineralizing agents on the outcome of postorthodontic WSLs was evaluated. It was found that the use of 5% NaF varnish in addition to twice daily use of 1000 ppm of fluoride toothpaste had no additional beneficial effect in the remineralization of orthodontic WSLs, which was in contrast with the result of our study.

The results of our study demonstrated a statistically significant decrease for DPI and GI in both groups of fluoride and CHX in all three times of follow-up.

CHX has known antiplaque and antigingivitis effect and it may be employed as an adjunct to other preventive measures such as professional care and patient-oriented instruction on an intermittent basis to reduce the plaque-induced iatrogenic side effects and to enhance the efficacy of oral hygiene measures in connection with orthodontic therapy with fixed appliances.^[15,38]

Several studies in the literature are in agreement with the results of our study, confirming that CHX and fluoride varnishes can decrease dental plaque and WSLs of orthodontic patients when added to routine oral hygiene treatment (brushing + flossing).^[39-41] CHX and fluoride groups demonstrated significantly better plaque index and GI scores at all treatment intervals after baseline measurements.

In Jayaprakash *et al.*^[42] study, it was concluded that a mouth rinse containing CHX and sodium fluoride

could elevate dental hygiene and decrease plaque and gingivitis, which is in agreement with the findings of our study.

In Esfahanian *et al.*^[43] study, they reported that CHX has a positive effect in plaque control and it was better when compared to Irsha mouth rinses.

Early detection of WSLs during orthodontic treatment is also very important as it would allow clinicians to implement preventive measures to control the demineralization process before progression of the lesions. In this study, we decided to use fluoride varnishes for two reasons; first, because we wanted to use it at 3-month intervals and second, based on the literature, it seems that this type of application of fluoride can provide the patients with the best possible outcome.^[44]

In this study, a statistically significant decrease of WSLs was registered in the participants of CHX and fluoride groups in all three follow-ups but not in the control or placebo groups. No significant differences were observed between the CHX and fluoride groups for demineralization.

To date, clinical detection of WSLs has been carried out primarily by means of traditional methods such as visual inspection after air drying and tactile examination by dental probing. We chose to use this approach in our study. However, the subjectivity and lack of reproducibility of these approaches, together with the prerequisite presence of a significantly advanced lesion, have led to the introduction of several optical techniques during recent decades, including optical caries monitor, use of quantitative laser and light-induced fluorescence, digital imaging with fiber-optic transillumination, laser fluorescence, and computer analysis of digital photographs.^[45] Enamel surface roughness affects its visual properties, plaque retention, abrasion, and bond strength.^[46]

Due to simple sampling, the unification of (Decay-missing-filling-surfaces) was difficult and one of the limitations of our study.

CONCLUSION

Adding CHX and fluoride to daily oral hygiene program reduces bacterial plaque accumulation and improves GI. Orthodontists are recommended to enhance their patients' oral hygiene by requiring the use of CHX and fluoride in addition to daily brushing.

Financial support and sponsorship

Nil.

Conflicts of interest

The authors of this manuscript declare that they have no conflicts of interest, real or perceived, financial or nonfinancial in this article.

REFERENCES

1. Shirani F, Sakhaimeanesh M. Effect of remineralizing agents on the color change of sound enamel and white spot lesions. *Journal of Isfahan dental school* 2013;9:358-68.
2. Lundström F, Krasse B. *Streptococcus mutans* and lactobacilli frequency in orthodontic patients; the effect of chlorhexidine treatments. *Eur J Orthod* 1987;9:109-16.
3. Ahn SJ, Lim BS, Lee SJ. Prevalence of cariogenic streptococci on incisor brackets detected by polymerase chain reaction. *Am J Orthod Dentofacial Orthop* 2007;131:736-41.
4. Øgaard B, editor. *White Spot Lesions during Orthodontic Treatment: Mechanisms and Fluoride Preventive Aspects. Seminars in Orthodontics.* University of oslo, Norway: Elsevier; 2008.
5. Geiger AM, Gorelick L, Gwinnett AJ, Griswold PG. The effect of a fluoride program on white spot formation during orthodontic treatment. *Am J Orthod Dentofacial Orthop* 1988;93:29-37.
6. Ahn SJ, Lim BS, Yang HC, Chang YI. Quantitative analysis of the adhesion of cariogenic streptococci to orthodontic metal brackets. *Angle Orthod* 2005;75:666-71.
7. Hickman J, Millett DT, Sander L, Brown E, Love J. Powered vs. manual tooth brushing in fixed appliance patients: A short term randomized clinical trial. *Angle Orthod* 2002;72:135-40.
8. Vizitiu T, Ecaterina I. *In vitro* evaluation of effectiveness in reducing bacterial plaque of antimicrobial substances in patients treated with orthodontic appliances. *Therapeutics, Pharmacol Clin Toxicol* 2011;15:245-48.
9. Tufekci E, Casagrande ZA, Lindauer SJ, Fowler CE, Williams KT. Effectiveness of an essential oil mouthrinse in improving oral health in orthodontic patients. *Angle Orthod* 2008;78:294-8.
10. Sekino S, Ramberg P, Uzel NG, Socransky S, Lindhe J. Effect of various chlorhexidine regimens on salivary bacteria and *de novo* plaque formation. *J Clin Periodontol* 2003;30:919-25.
11. Axelsson S, Söder B, Nordenram G, Petersson LG, Dahlgren H, Norlund A, *et al.* Effect of combined caries-preventive methods: A systematic review of controlled clinical trials. *Acta Odontol Scand* 2004;62:163-9.
12. Botelho MA, dos Santos RA, Martins JG, Carvalho CO, Paz MC, Azenha C, *et al.* Efficacy of a mouthrinse based on leaves of the neem tree (*Azadirachta indica*) in the treatment of patients with chronic gingivitis: A double-blind, randomized, controlled trial. *J Med Plants Res* 2008;2:341-6.
13. Gomez SS, Basili CP, Emilson CG. A 2-year clinical evaluation of sealed noncavitated approximal posterior carious lesions in adolescents. *Clin Oral Investig* 2005;9:239-43.
14. Chapman JA, Roberts WE, Eckert GJ, Kula KS, González-Cabezas C. Risk factors for incidence and severity

- of white spot lesions during treatment with fixed orthodontic appliances. *Am J Orthod Dentofacial Orthop* 2010;138:188-94.
15. Featherstone JD. Delivery challenges for fluoride, chlorhexidine and xylitol. *BMC Oral Health* 2006;6 Suppl 1:S8.
 16. Schaeken MJ, De Haan P. Effects of sustained-release chlorhexidine acetate on the human dental plaque flora. *J Dent Res* 1989;68:119-23.
 17. Maxfield BJ, Hamdan AM, Tüfekçi E, Shroff B, Best AM, Lindauer SJ, *et al.* Development of white spot lesions during orthodontic treatment: Perceptions of patients, parents, orthodontists, and general dentists. *Am J Orthod Dentofacial Orthop* 2012;141:337-44.
 18. Sandham HJ, Brown J, Chan KH, Phillips HI, Burgess RC, Stokl AJ, *et al.* Clinical trial in adults of an antimicrobial varnish for reducing mutans streptococci. *J Dent Res* 1991;70:1401-8.
 19. Brunner E, Langer F. Nonparametric analysis of ordered categorical data in designs with longitudinal observations and small sample sizes. *Biom J* 2000;42:663-75.
 20. Morrow D, Wood DP, Speechley M. Clinical effect of subgingival chlorhexidine irrigation on gingivitis in adolescent orthodontic patients. *Am J Orthod Dentofacial Orthop* 1992;101:408-13.
 21. Stecksén-Blicks C, Renfors G, Oscarson ND, Bergstrand F, Twetman S. Caries-preventive effectiveness of a fluoride varnish: A randomized controlled trial in adolescents with fixed orthodontic appliances. *Caries Res* 2007;41:455-9.
 22. Derks A, Kuijpers-Jagtman AM, Frencken JE, Van't Hof MA, Katsaros C. Caries preventive measures used in orthodontic practices: An evidence-based decision? *Am J Orthod Dentofacial Orthop* 2007;132:165-70.
 23. Geiger AM, Gorelick L, Gwinnett AJ, Benson BJ. Reducing white spot lesions in orthodontic populations with fluoride rinsing. *Am J Orthod Dentofacial Orthop* 1992;101:403-7.
 24. Beerens MW, van der Veen MH, van Beek H, ten Cate JM. Effects of casein phosphopeptide amorphous calcium fluoride phosphate paste on white spot lesions and dental plaque after orthodontic treatment: A 3-month follow-up. *Eur J Oral Sci* 2010;118:610-7.
 25. Bröchner A, Christensen C, Kristensen B, Tranæus S, Karlsson L, Sonnesen L, *et al.* Treatment of post-orthodontic white spot lesions with casein phosphopeptide-stabilised amorphous calcium phosphate. *Clin Oral Investig* 2011;15:369-73.
 26. Loe H, Silness J. Periodontal disease in pregnancy. I. Prevalence and severity. *Acta Odontol Scand* 1963;21:533-51.
 27. Ahovuo-Saloranta A, Hiiri A, Nordblad A, Mäkelä M, Worthington HV. Pit and fissure sealants for preventing dental decay in the permanent teeth of children and adolescents. *Cochrane Database Syst Rev* 2008;3:CD001830.
 28. Gorelick L, Geiger AM, Gwinnett AJ. Incidence of white spot formation after bonding and banding. *Am J Orthod* 1982;81:93-8.
 29. Walsh T, Worthington HV, Glenny AM, Appelbe P, Marinho VC, Shi X, *et al.* Fluoride toothpastes of different concentrations for preventing dental caries in children and adolescents. *Cochrane Database Syst Rev* 2010;4:CD007868.
 30. American Dental Association Council on Scientific Affairs. Professionally applied topical fluoride: Evidence-based clinical recommendations. *J Am Dent Assoc* 2006;137:1151-9.
 31. Griffin SO, Regnier E, Griffin PM, Huntley V. Effectiveness of fluoride in preventing caries in adults. *J Dent Res* 2007;86:410-5.
 32. Gehlen I, Netuschil L, Berg R, Reich E, Katsaros C. The influence of a 0.2% chlorhexidine mouthrinse on plaque regrowth in orthodontic patients. A randomized prospective study. Part I: Clinical parameters. *J Orofac Orthop* 2000;61:54-62.
 33. Miller RA, McIver JE, Gunsolley JC. Effects of sanguinaria extract on plaque retention and gingival health. *J Clin Orthod* 1988;22:304-7.
 34. Chen H, Liu X, Dai J, Jiang Z, Guo T, Ding Y, *et al.* Effect of remineralizing agents on white spot lesions after orthodontic treatment: A systematic review. *Am J Orthod Dentofacial Orthop* 2013;143:376-82.e3.
 35. Migliorati M, Isaia L, Cassaro A, Rivetti A, Silvestrini-Biavati F, Gastaldo L, *et al.* Efficacy of professional hygiene and prophylaxis on preventing plaque increase in orthodontic patients with multibracket appliances: A systematic review. *Eur J Orthod* 2015;37:297-307.
 36. Okada EM, Ribeiro LN, Stuani MB, Borsatto MC, Fidalgo TK, Paula-Silva FW, *et al.* Effects of chlorhexidine varnish on caries during orthodontic treatment: A systematic review and meta-analysis. *Braz Oral Res* 2016;30:e115.
 37. Singh S, Singh SP, Goyal A, Utreja AK, Jena AK. Effects of various remineralizing agents on the outcome of post-orthodontic white spot lesions (WSLs): A clinical trial. *Prog Orthod* 2016;17:25.
 38. Demir A, Malkoc S, Sengun A, Koyuturk AE, Sener Y. Effects of chlorhexidine and povidone-iodine mouth rinses on the bond strength of an orthodontic composite. *Angle Orthod* 2005;75:392-6.
 39. Ultramari-Navarro PV, Titarelli JM, Marsicano JA, Henriques JF, Janson G, Lauris JR, *et al.* Effectiveness of 0.50% and 0.75% chlorhexidine dentifrices in orthodontic patients: A double-blind and randomized controlled trial. *Am J Orthod Dentofacial Orthop* 2009;136:651-6.
 40. Olympio KP, Bardal PA, de M Bastos JR, Buzalaf MA. Effectiveness of a chlorhexidine dentifrice in orthodontic patients: A randomized-controlled trial. *J Clin Periodontol* 2006;33:421-6.
 41. Santos A. Evidence-based control of plaque and gingivitis. *J Clin Periodontol* 2003;30 Suppl 5:13-6.
 42. Jayaprakash K, Veerasha KL, Hiremath SS. A comparative study of two mouthrinses on plaque and gingivitis in school children in the age group of 13-16 years in Bangalore city. *J Indian Soc Pedod Prev Dent* 2007;25:126-9.
 43. Esfahanian V, Ketabi M, Farman AH. Efficacy of chlorhexidine and Irsha (Anti-plaque) mouth-rinses on reducing dental plaques. *J Isfahan Den Sch* 2007;3:10-14.
 44. Mitchell L. Decalcification during orthodontic treatment with fixed appliances – An overview. *Br J Orthod* 1992;19:199-205.
 45. Heymann GC, Grauer D. A contemporary review of white spot lesions in orthodontics. *J Esthet Restor Dent* 2013;25:85-95.
 46. Shirani F, Amrollahi M, Amrollahi N. Effect of remineralizing agents on surface roughness of demineralized enamel. *Journal of Isfahan dental school* 2016;12:165-174.