

## Case Report

# Unusual report of non-syndromic permanent unilateral mandibular canine agenesis

Carmen García-Marín<sup>1</sup>, Paula Ferrer<sup>1</sup>, María Victoria Mateos<sup>1</sup>, Nazaret Rodríguez<sup>1</sup>, Encarna de Fernando<sup>1</sup>, José María Marín<sup>1</sup>, Rosa Yanez<sup>2</sup>

<sup>1</sup>Department of Stomatology IV, School of Dentistry, Complutense University of Madrid, Madrid, <sup>2</sup>Department of Stomatology, School of Dentistry, University of Sevilla, Sevilla, Spain

### ABSTRACT

Nonsyndromic unilateral permanent canine agenesis, particularly in the lower jaw, is an infrequent clinical observation that has occasionally been reported in the scientific literature. The main aim of the present case report and study is to give insights into the clinical features and genetic information of a nonsyndromic patient affected by unilateral lower canine agenesis and her relatives. A young girl of 9-year-old with a Class II skeletal malocclusion, sella turcica bridging, and severe overjet but no other dental anomalies is described. No associations were found with other types of dental agenesis and previously described genetic variations of the CTNNA1 gene. The possibility of a novel genetic locus should be considered as a possible genetic etiology for this extremely rare condition in a nonsyndromic patient. Based on scientific literature written in English, the present clinical case is one of the first reports to describe a nonsyndromic permanent unilateral mandibular canine agenesis.

**Key Words:** Agenesis, canine, malocclusion, orthodontics

Received: June 2017  
Accepted: December 2017

#### Address for correspondence:

Dr. Rosa Yanez,  
School of Dentistry,  
University of Sevilla, Calle  
Avicena, S/N, Sevilla 41009,  
Spain.  
E-mail: rosaya83@hotmail.  
com

## INTRODUCTION

Dental agenesis, hypodontia, oligodontia, and anodontia, are developmental anomalies that involve the absence of one to all the teeth. This kind of congenital disorder is relatively common in humans and mostly affects the permanent teeth, rather than the deciduous ones; it is even more frequent in certain types of craniofacial syndrome with dental anomalies that include the absence of one or more of the teeth.<sup>[1]</sup> Nevertheless, many other nonsyndromic types of dental agenesis can be found in the general population, with the most common form being a missing third molar.<sup>[2]</sup>

Nonsyndromic agenesis of permanent mandibular canines represents an unusual type of tooth agenesis.<sup>[3]</sup>

This anomaly has occasionally been combined with agenesis of other teeth, but isolated unilateral forms occur very rarely in the general population. The most common forms of agenesis involve the lower second bicuspid (35, 45), upper lateral incisors (12, 22), and upper second bicuspid (15, 25) and it may be congenital or arise as a spontaneous clinical manifestation.<sup>[2]</sup>

### Prevalence and clinical manifestations

Over 60,000 to 20 million individuals worldwide are affected by disruptions of at least one tooth during formation (~0.03%–10.1%).<sup>[4]</sup> The exception is the third molar, which occurs more frequently. Clinical

This is an open access journal, and articles are distributed under the terms of the Creative Commons Attribution-NonCommercial-ShareAlike 4.0 License, which allows others to remix, tweak, and build upon the work non-commercially, as long as appropriate credit is given and the new creations are licensed under the identical terms.

**For reprints contact:** reprints@medknow.com

**How to cite this article:** García-Marín C, Ferrer P, Mateos MV, Rodríguez N, De Fernando DE, Marín JM, *et al.* Unusual report of nonsyndromic permanent unilateral mandibular canine agenesis. *Dent Res J* 2018;15:XX-XX.

#### Access this article online



Website: www.drj.ir  
www.drjjournal.net  
www.ncbi.nlm.nih.gov/pmc/journals/1480

manifestations of this developmental anomaly differ in terms of the number and type of teeth affected: Hypodontia refers to cases where fewer than six teeth are missing; oligodontia when six teeth or more are affected; and anodontia, the most severe form, when all teeth are missing from the mouth. Usually, the first diagnosis comes from the existence of diastemas along with midline deviations and other derivate clinical and esthetic effects.<sup>[5]</sup>

Although there is no conclusive evidence of a single factor affecting tooth agenesis, genetic, systemic, and local factors have been reported as associated with failure of permanent tooth formation.<sup>[6]</sup>

### Genetic influence

Whether tooth agenesis has a single etiology is still unclear. Various factors have been described in the literature as associated with the lack of development, mineralization, or formation of temporary or permanent teeth.<sup>[6]</sup> Spontaneous and congenital presentations of the anomaly can be found in the population.<sup>[7]</sup> Furthermore, when agenesis is present in a family context, it may present as an isolated trait or as characteristic of another complex syndrome. Cases of spontaneous agenesis may be influenced by local and/or genetic factors, frequently with one to three teeth missing. In this respect, tooth agenesis in the family setting generally follows an autosomal dominant/recessive disorder or forms part of a chromosome X-linked trait, while isolated cases tend to have a complex and multifactorial pattern of inheritance. In recent years, there has been growing scientific evidence of genes linked to the occurrence of tooth agenesis in both animal models and humans, and a map of the complexities of its genetic etiology is being constructed to define the genetic network and cross-talk processes between different chromosomal loci.<sup>[7-12]</sup> Some genetic factors have been described as linked to a background with a greater predisposition to affect any of the processes that mediate tooth embryogenesis, bud formation, and mineralization.<sup>[13-15]</sup>

The present case report describes the occurrence of a very unusual clinical report of agenesis of a unilateral inferior canine in a family setting. The genotype data of parents, grandparents, and siblings were recorded, and these data are discussed in light of current knowledge of this extremely rare phenotype worldwide.<sup>[6]</sup>

## CASE REPORT

### Clinical and radiographic information

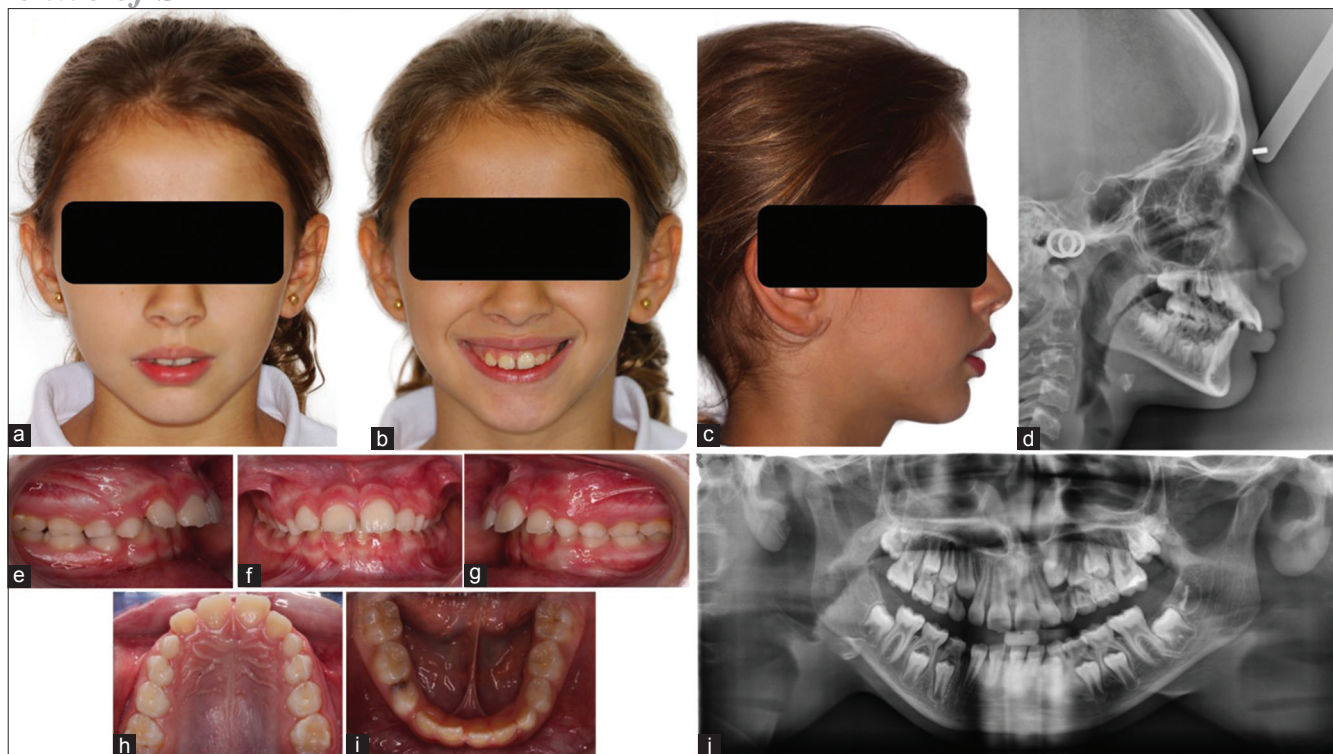A 9-year-old girl was examined at the School of Dentistry in the University Complutense of Madrid with the chief complaint being irregular protruding teeth [Figure 1 a-j]. The patient displayed mixed dentition with a Class II malocclusion, notable overjet (9 mm), and an inferior midline deviation 2 mm to the right. Several caries and gingival pathology were noted during the clinical exploration.

A detailed radiographic examination [Figure 1j] revealed a normal chronological eruption sequence, with incomplete root formation of the permanent maxillary and mandibular second molars and canines, mild infraocclusion of the deciduous molars with root resorption, and profound caries in 16 occlusomesial, 55 mesial and distal, 54 distal, 64 occlusodistal, 65 occlusomesial, 26 mesial, 36 occlusal, 75 occlusal, 84 occlusodistal, 85 occlusal, and 46 mesial. The main pathological finding on the patient's panoramic X-ray was the absence of the right permanent mandibular canine. The caries diagnosed at 16 mesial, 55 mesial and distal, 54 distal, 64 distal, 65 mesial, 26 mesial, 84 occlusodistal, and 46 mesial were confirmed with a bite wing series exploration.

Lateral X-ray analysis [Figure 1d] showed sella turcica bridging, while cephalometric characteristics indicated that the patient had a skeletal Class II malocclusion (ANB + 7°; Wits: +3.5 mm) with mandibular retrusion (SNB 77,5° a dolichofacial-mesofacial pattern (Go-Gn SN: 36°) and flaring of the upper incisors (I-SNA: +8 mm, 28°), as shown in detail in Table 1.

The patient's parents, siblings, and ascendant relatives (grandmothers and grandfathers) had no history of tooth agenesis. The patient had had no pathological alterations in her pre- or postnatal development and her mother had not been overexposed to radiation or particular medication during the gestational period. No systemic disease or syndrome could be determined. The anamnesis recorded no previous history of traumatic lesions in the oral cavity or rare pathological/systemic conditions in childhood.

Taking these data into account as well as the clinical/radiographic information, the diagnosis was a skeletal Class II division 1 malocclusion with an extremely rare nonsyndromic case of unilateral lower canine agenesis.



**Figure 1:** Clinical and radiographic records of the affected patient: (a) Facial-frontal view photograph at rest; (b) facial-frontal view photograph in smiling; (c) profile view photograph at rest; (d) lateral radiograph; (e) right buccal view in occlusion; (f) intraoral frontal view in occlusion; (g) left buccal view in occlusion; (h) upper occlusal view; (i) Lower occlusal view; (j) panoramic radiography.

**Table 1: Cephalometric characteristic of the affected patient**

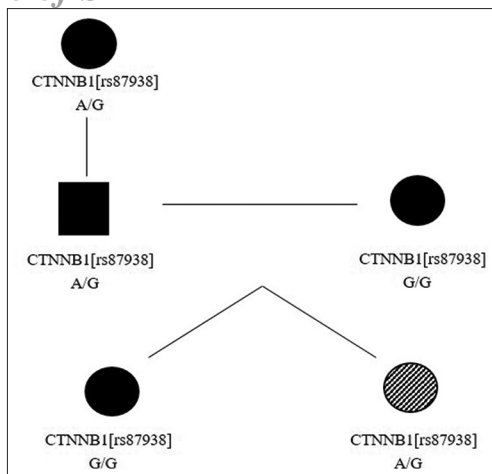
Cephalometric variable	Value	Standard deviation
SNA	84°	
SNB	77,5°	--
ANB	+7°	++++
SND	74,5°	
SE	20 mm	
SL	51 mm	
Maxillary incisor position	+6 mm	+
Maxillary incisor angle	28°	++
Mandibular incisor position	-3 mm	-----
Mandibular incisor angle	24°	
Interincisal incisor angle	121°	--
S-GN/SN	67°	
Go-Gn/SN	36°	+
Occlusal plane	18°	+
Esthetic plane	+2	

**Genetic screening and diagnosis: Sample collection, DNA isolation, and determination of genotypes**

All participants were invited to participate in the study as volunteers before initiating any restorative or orthodontic treatment. The Institutional Ethical Committee granted ethical approval. The patient and her relatives were genetically screened for

genetic variants reported in the literature<sup>[16,17]</sup> as predisposing to tooth agenesis. Samples were taken for DNA analysis, collecting 2 ml saliva using a commercially available collection tube and stabilization solution (Oragene DISCOVER ORG-500, DNA Genotek, Ontario, Canada). DNA was extracted using PrepIT•L2P; in brief, saliva samples gradually underwent ethanol cleavage and spin processes in accordance with the manufacturer’s instructions to obtain total DNA for each participant. This was then aliquoted at – 80°C in every case. Single-nucleotide polymorphisms of target genes were analyzed at CTNNB1 (rs87938) (Sequenom’s Gold and Mass array. iPLEX Technology). Briefly, after DNA extraction, target gene sequences were amplified using HotStarTaq polymerase (Qiagen, Hilden, Germany). Reverse hybridization was used to identify the genotypes of the patient’s target genes from the generated amplicons.

The genetic results are compiled in Figure 2. The affected patient was diagnosed as heterozygous for the less frequent allele (A) of the CTNNB1 genetic variant. Certainly, no unique and definitive relationship has been found to date in any of the different reports of teeth agenesis; nevertheless,



**Figure 2:** Genotyping information of the affected patient and relatives. A: Adenine; C: Cytosine; G: Guanine; T: Thymine.

several single markers have been explored and published to find any potential initial association. When talking about canine agenesis, that is, by far one of the less common types of tooth agenesis, no single markers have been analyzed to date so this paper offers, at least, some genetic information of the patient, and the ascendants who are not pretended to be definitive evidence (since case reports are not sound scientific material to be considered as a sole statement). Instead, case reports are well-intended description of unique or rare cases that should be described with high detail. In the present case, the genetic information is just that, additional information to be considered in this rare tooth agenesis along with all the radiographic and clinical records of the patient.

Figure 2 shows that none of the individuals involved, the patient, siblings, parents, or grandparents, reported any affectation due to a homozygous genotype of the rare allele in either of the genetic variants of the target genes studied.

## DISCUSSION

Phylogenetic evolution in humans has been explained in accordance with Bolk's theory of terminal reduction,<sup>[18,19]</sup> in which the most distal element of a group of teeth occurs is more frequently absent than one located in a mesial position. In other words, tooth agenesis occurs in the most distal germ of any particular group of teeth.<sup>[19]</sup>

The absence of permanent canines has been reported as more frequently affecting women, as in the present case, and the upper maxilla, unlike the present

case report.<sup>[20-22]</sup> The reported prevalence in the literature varies substantially from 0.4% in the Afro American population<sup>[23]</sup> to between 0.04%<sup>[20]</sup> and 0.46%<sup>[21]</sup> in other studies of the Chinese population, 0.11% in the Japanese population, both reported in large sample studies.<sup>[22]</sup> The prevalence studies in a European population reported rates ranging from 0.27%<sup>[21]</sup> and 0.37%<sup>[24]</sup> to 2.1%<sup>[25]</sup> although all these studies were based on small sample sizes, which could bias the observed prevalence of those types of agenesis. Agenesis of a permanent canine often occurs along with other forms of teeth agenesis, abnormal tooth shapes, or anomalous numbers<sup>[22]</sup> but may also occur as a spontaneous clinical manifestation secondary to environmental factors.<sup>[26,27]</sup> The present case report, similar to other previous studies,<sup>[28]</sup> is a clinical case with no other dental anomalies associated with lower canine agenesis and described the genetic findings associated with it, enabling comparisons with findings observed in individuals from other populations.<sup>[20-22]</sup>

Molecular studies of the tooth formation process using rodent models have led to the deciphering of a considerable number of genes and genetic pathways involved in odontogenesis which may be involved in pathological events like tooth agenesis and other tooth-related pathologies.<sup>[7,9,10,12,29]</sup> The *MSX1* knockout mouse model leads to defects of the palate (cleft palate) and tooth agenesis along with other congenital problems;<sup>[30]</sup> this correlates with the phenotype found in numerous patients carrying the *MSX1* gene mutation, in which a number of patients with *MSX1* mutations also had tooth agenesis and oral cleft lips.<sup>[9,10,30]</sup> This allele variant was absent in a sample of European descent reported in earlier genotype databases (dbSNP database – <http://www.ncbi.nlm.nih.gov/snp/>). Nevertheless, previous studies found that the T allele of the *MSX1* (rs1095) gene variant appeared only in patients affected by agenesis and not in nonaffected controls, who were found to be homozygous for the C allele instead.

With specific reference to permanent canine agenesis, no clear association with any particular genetic variant or gene point mutation has been described to date. Recent studies have associated the absence of both permanent maxillary canines with point mutations located in the *WNT10A* gene,<sup>[31]</sup> although no specific genetic pattern or anomaly has been identified as associated with agenesis of a single permanent lower canine without other tooth alterations. In this case

report, potentially suggestive genetic variations in the *CTNNB1*<sup>[16,17]</sup> gene of the affected patient and members of her family were explored and analyzed. Nevertheless, no differences of genotyping information were found between the affected patient and any of her unaffected relatives. Furthermore, in the present case report, the polymorphism previously described as associated with agenesis of the upper lateral incisors and third molars did not affect agenesis of the lower permanent canine. It should be highlighted that nonsyndromic congenital tooth agenesis is a complex trait with a polygenic, multifactorial etiology.<sup>[3]</sup> Interconnected gene functions are orchestrated sequentially to influence the structural development of the developing tooth. *MSX1* and *CTNNB1* genes appear to influence different types of agenesis patterns,<sup>[16,17]</sup> although several other genes, described or not yet discovered, could be implicated in the process and the precise mechanisms that lead to canine agenesis are yet to be deciphered.

In the present study, the affected patient was found to have a class II skeletal malocclusion. Sella turcica bridging was also found in this patient, which is an anatomical sign commonly associated with several other dental anomalies and systemic conditions.<sup>[31-34]</sup> This is the first time that it has been described in a unilateral case of a permanent lower canine in a nonsyndromic context.

### Concluding remarks and future perspectives

This report offers new information that may be useful for deciphering further the network underlying each type of tooth agenesis mechanism. The construction of an etiologic gene map for tooth agenesis offers the possibility of a new therapeutic field with new gene or protein-based treatments able to correct deficiencies deriving from aberrant gene products.<sup>[35]</sup>

### Declaration of patient consent

The authors certify that they have obtained all appropriate patient consent forms. In the form, the legal guardian has given his consent for images and other clinical information to be reported in the journal. The guardian understands that names and initials will not be published and due efforts will be made to conceal patient identity, but anonymity cannot be guaranteed.

### Financial support and sponsorship

Nil.

### Conflicts of interest

The authors of this manuscript declare that they have no conflicts of interest, real or perceived, financial or nonfinancial in this article.

## REFERENCES

1. Graber LW. Congenital absence of teeth: A review with emphasis on inheritance patterns. *J Am Dent Assoc* 1978;96:266-75.
2. Polder BJ, Van't Hof MA, Van der Linden FP, Kuijpers-Jagtman AM. A meta-analysis of the prevalence of dental agenesis of permanent teeth. *Community Dent Oral Epidemiol* 2004;32:217-26.
3. Nieminen P. Genetic basis of tooth agenesis. *J Exp Zool B Mol Dev Evol* 2009;312B: 320-42.
4. Karadas M, Celikoglu M, Akdag MS. Evaluation of tooth number anomalies in a subpopulation of the North-East of Turkey. *Eur J Dent* 2014;8:337-41.
5. Jiménez-Castellanos E, Orozco-Varo A, Arroyo-Cruz G, Iglesias-Linares A. Prevalence of alterations in the characteristics of smile symmetry in an adult population from Southern Europe. *J Prosthet Dent* 2016;115:736-40.
6. Yin W, Bian Z. The gene network underlying hypodontia. *J Dent Res* 2015;94:878-85.
7. Vastardis H, Karimbux N, Guthua SW, Seidman JG, Seidman CE. A human *MSX1* homeodomain missense mutation causes selective tooth agenesis. *Nat Genet* 1996;13:417-21.
8. Iglesias-Linares A, Morford LA, Hartsfield JK Jr. Bone density and dental external apical root resorption. *Curr Osteoporos Rep* 2016;14:292-309.
9. Stockton DW, Das P, Goldenberg M, D'Souza RN, Patel PI. Mutation of *PAX9* is associated with oligodontia. *Nat Genet* 2000;24:18-9.
10. van den Boogaard MJ, Créton M, Bronkhorst Y, van der Hout A, Hennekam E, Lindhout D, et al. Mutations in *WNT10A* are present in more than half of isolated hypodontia cases. *J Med Genet* 2012;49:327-31.
11. Tatematsu T, Kimura M, Nakashima M, Machida J, Yamaguchi S, Shibata A, et al. An aberrant splice acceptor site due to a novel intronic nucleotide substitution in *MSX1* gene is the cause of congenital tooth agenesis in a Japanese family. *PLoS One* 2015;10:e0128227.
12. Lammi L, Arte S, Somer M, Jarvinen H, Lahermo P, Thesleff I, et al. Mutations in *AXIN2* cause familial tooth agenesis and predispose to colorectal cancer. *Am J Hum Genet* 2004;74:1043-50.
13. Zhang W, Qu HC, Zhang Y. *PAX-9* polymorphism may be a risk factor for hypodontia: A meta-analysis. *Genet Mol Res* 2014;13:9997-10006.
14. Sarkar T, Bansal R, Das P. Whole genome sequencing reveals novel non-synonymous mutation in ectodysplasin A (*EDA*) associated with non-syndromic X-linked dominant congenital tooth agenesis. *PLoS One* 2014;9:e106811.
15. Kantaputra PN, Kaewgahya M, Hatsadaloi A, Vogel P, Kawasaki K, Ohazama A, et al. *GREMLIN 2* mutations and dental anomalies. *J Dent Res* 2015;94:1646-52.
16. Mostowska A, Biedziak B, Zadurska M, Dunin-Wilczynska I, Lianeri M, Jagodzinski PP, et al. Nucleotide variants of genes encoding components of the Wnt signalling pathway and the risk of non-syndromic tooth agenesis. *Clin Genet* 2013;84:429-40.
17. Wang XP, O'Connell DJ, Lund JJ, Saadi I, Kuraguchi M, Turbe-Doan A, et al. *Apc* inhibition of Wnt signaling regulates

- supernumerary tooth formation during embryogenesis and throughout adulthood. *Development* 2009;136:1939-49.
18. de Beer GR. *Embryos and Ancestors*. Oxford: Clarendon Press; 1951. p. 58-9.
  19. Fekonja A. Hypodontia in orthodontically treated children. *Eur J Orthod* 2005;25:457-60.
  20. Cho SY, Lee CK, Chan JC. Congenitally missing maxillary permanent canines: Report of 32 cases from an ethnic Chinese population. *Int J Paediatr Dent* 2004;14:446-50.
  21. Rózsa N, Nagy K, Vajó Z, Gábris K, Soós A, Alberth M, et al. Prevalence and distribution of permanent canine agenesis in dental paediatric and orthodontic patients in Hungary. *Eur J Orthod* 2009;31:374-9.
  22. Fukuta Y, Totsuka M, Takeda Y, Yamamoto H. Congenital absence of the permanent canines: A clinico-statistical study. *J Oral Sci* 2004;46:247-52.
  23. Harris EF, Clark LL. Hypodontia: An epidemiologic study of American black and white people. *Am J Orthod Dentofacial Orthop* 2008;134:761-7.
  24. Sisman Y, Uysal T, Gelgor IE. Hypodontia. Does the prevalence and distribution pattern differ in orthodontic patients? *Eur J Dent* 2007;1:167-73.
  25. Fekonja A. Hypodontia in orthodontically treated children. *Eur J Orthod* 2005;27:457-60.
  26. Mendoza-Mendoza A, González-Mallea E, Iglesias-Linares A. Intrusive luxation in primary teeth: A Case report. *J Clin Pediatr Dent* 2015;39:215-8.
  27. Mendoza-Mendoza A, Iglesias-Linares A, Yañez-Vico RM, Abalos-Labruzzo C. Prevalence and complications of trauma to the primary dentition in a subpopulation of Spanish children in Southern Europe. *Dent Traumatol* 2015;31:144-9.
  28. Yadav SK, Yadav AB, Kedia NB, Singh AK. Agenesis of permanent canines: Rare case report. *Dent Res J (Isfahan)* 2017;14:359-62.
  29. Cadenas-Perula M, Yañez-Vico RM, Solano-Reina E, Iglesias-Linares A. Effectiveness of biologic methods of inhibiting orthodontic tooth movement in animal studies. *Am J Orthod Dentofacial Orthop* 2016;150:33-48.
  30. Satokata I, Maas R. *Msx1* deficient mice exhibit cleft palate and abnormalities of craniofacial and tooth development. *Nat Genet* 1994;6:348-56.
  31. Kantaputra P, Kaewgahya M, Kantaputra W. *WNT10A* mutations also associated with agenesis of the maxillary permanent canines, a separate entity. *Am J Med Genet A* 2014;164A:360-3.
  32. Meyer-Marcotty P, Reuther T, Stellzig-Eisenhauer A. Bridging of the sella turcica in skeletal class III subjects. *Eur J Orthod* 2010;32:148-53.
  33. Caleza C, Yañez-Vico RM, Mendoza A, Iglesias-Linares A. Childhood obesity and delayed gratification behavior: A Systematic review of experimental studies. *J Pediatr* 2016;169:201-7.e1.
  34. Ali B, Shaikh A, Fida M. Association between sella turcica bridging and palatal canine impaction. *Am J Orthod Dentofacial Orthop* 2014;146:437-41.
  35. Huttner K. Future developments in XLHED treatment approaches. *Am J Med Genet A* 2014;164A: 2433-6.