

Histomorphogenesis of pancreas in ostrich embryo (*Struthio camelus*)

Masoumeh Ahadian , Zohreh Saadatfar, Hamideh Ghodrati Azadi

Department of Basic Sciences, Faculty of Veterinary Medicine, Ferdowsi University of Mashhad, Mashhad, Iran

Keywords

ostrich, histology, pancreas, development

connective tissue and ducts were decreased and the acinar cells were increased. Pancreatic islets were determined on the day 1 after hatching.

Abstract

The present study was carried out to determine the development of pancreas in ostrich embryo. For this purpose ostrich embryos obtained on 10, 13, 16, 22, 26, 30 and 36 days of prehatching and 1 day of post hatching life. The specimens were stained with haematoxylin eosin [H&E], Gomori and Toluidine blue, and then were explored by light microscopy. The Results showed the primitive pancreas near the liver and duodenum on day 13. Histological observations showed that the pancreas was consisted of undifferentiated epithelial cells, connective tissue, non -organized ducts and blood vessels. On day 16, pancreas was composed of two dorsal and ventral lobes with the same structure of day 13. The zymogen granules were evident in developed acini on day 22. By aging the level of

Abbreviations

H&E : Haematoxylin and Eosin
hr : Hour
M : Molar
µm : Micrometer

Introduction

In origin, the pancreas develops from two separate primordial buds. The ventral pancreatic bud arises from the hepatic diverticulum and the dorsal pancreatic bud arises from the duodenum [2]. The cells of the pancreatic buds proliferate and give rise to the ducts and secretory acini. The endocrine portion of the pancreas develops from some epithelial cells which lose their connection with the duct system [10].

The avian pancreas is composed of dorsal, ventral, third and splenic lobes [with species differences]. It is divided to four lobes in chickens and quails [13] but in other birds such as duck, three lobes are identified [12]. The ostrich pancreas is composed of dorsal, ventral and splenic lobes. The cranial part of dorsal lobe is known as splenic lobe [14].

The exocrine part of pancreas in avian is similar to other animals, but there is no centro-acinar cells in chicken. Although infrequently some of these cells have been reported in starling and domestic goose [13]. The major islet cells include alpha [α], beta [β] and delta [δ] cells. The endocrine cells can be identified in small numbers between the islets [1].

Results

At the day 10 of incubation there was not any pancreatic tissue, but on day 13 it was determined near the liver and duodenum. Thus, the primary pancreas is formed between days 10 and 13 of incubation. The primordial pancreas was connected to the peripheral mesenchymal tissue and histo-

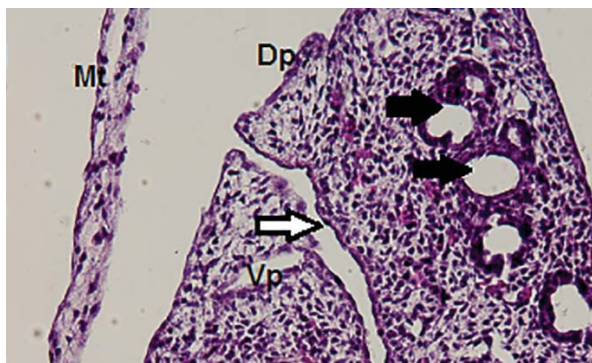


Figure 1
Pancreas at day 16 of prehatching development. DP: dorsal part of pancreas, VP: ventral part of pancreas, MT: mesenchymal tissue, Li: liver tissue, black arrows: ducts or vessels, white arrow: space between two parts of pancreas [H&E].

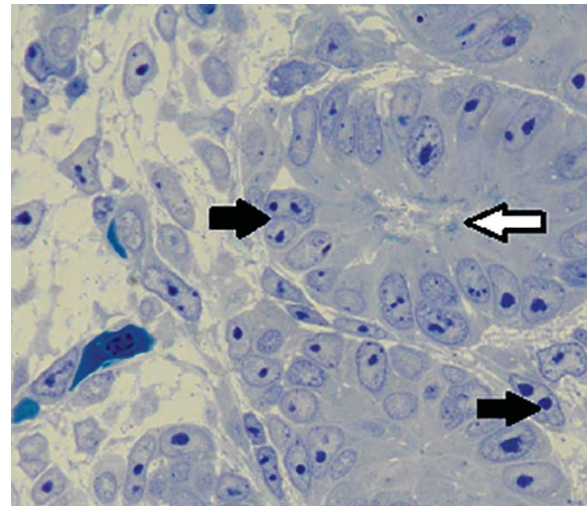


Figure 2
Pancreas on day 22 of prehatching development. CT: connective tissue, black arrows: mitotic cell, white arrow: zymogen granules [Toluidine blue staining].

logically was contained of undifferentiated epithelial cells and connective tissue. On day 16 of prehatching incubation, the pancreas had two dorsal and ventral lobes and was composed of developing exocrine parts, connective tissue, developing ducts and blood vessels (Figure 1).

On day 22, the structure of pancreas was similar to that in day 16. However, some mesenchymal tissue and the lobes were separated by narrow spaces. In semithin sections, the zymogen granules were rarely seen in exocrine cells (Figure 2).

On days 26 and 30 of incubation, the lobes were separated and the dorsal lobe was larger than ventral lobe. The acini were developed and the

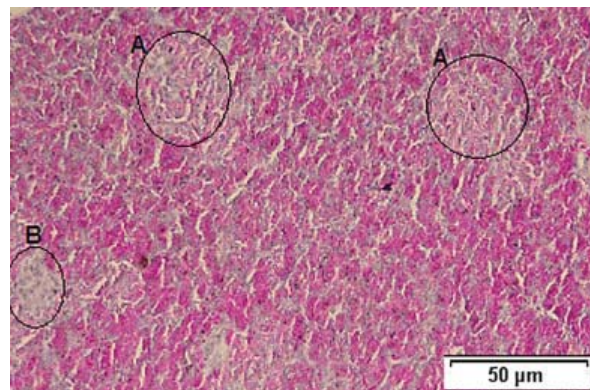


Figure 3
Histological structure of pancreas on day 1 after birth, A: Alpha islets, B: Beta islets in splenic lobe of pancreas [Gomori's staining].

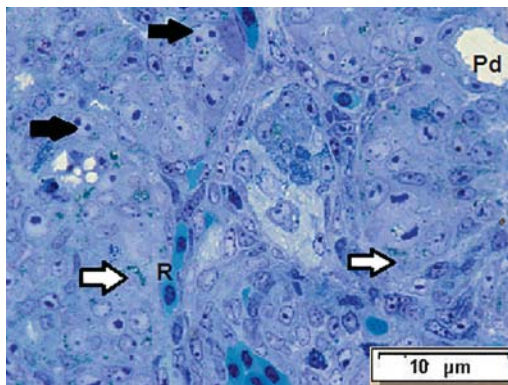


Figure 4
Histological structure of pancreas on day 1 after birth. Black arrows: mitotic cell, white arrows: zymogen granules, R: RBC, PD: pancreatic duct [Toluidine blue staining].

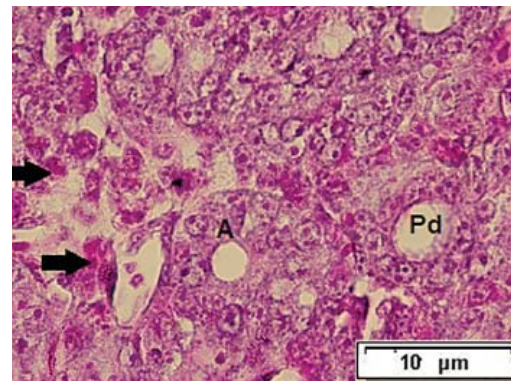


Figure 5
Histological structure of pancreas tissue on day 36 of prehatching development. A: acini, PD: pancreatic duct, arrows: eosinophilic alpha cells [Gomori's staining].

mesenchyme tissue had significantly decreased.

By day 36, the exocrine part had been completed and the zymogen granules were increased by aging (Figure 4). One day after hatch, the endocrine part was determined by H&E stain and more of the islets were concentrated in dorsal and splenic lobes (Figure 3).

With Gomori staining by day 36, the scattered alpha cells were determined between the acini (Figure 5). The typical alpha and beta islets were obvious on day 1 after hatching, and the islets were sporadic in ventral lobe. The alpha islets with pink cells were larger and more numerous than beta islets with blue cells (Figures 6 and 7).

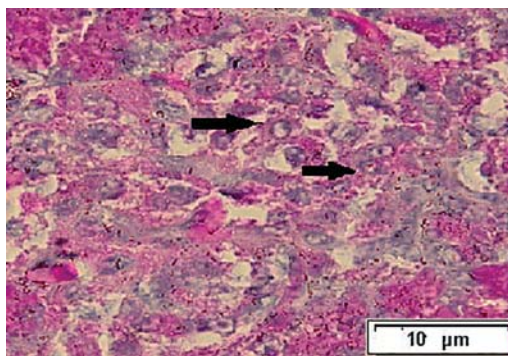


Figure 6
Histological structure of Alpha islet of pancreas on day 1 after birth. Black arrows: scattered Alpha cell [Gomori's staining].

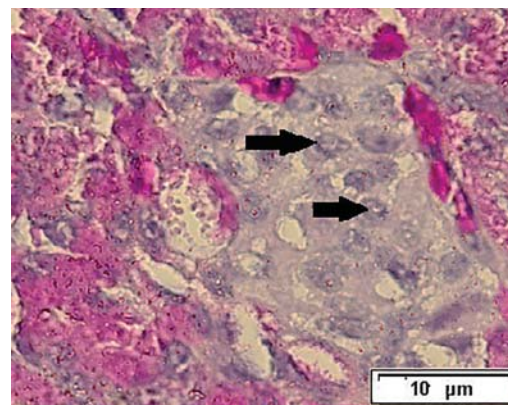


Figure 7
Histological structure of Beta islet of pancreas on day 1 after birth. Black arrows: Beta cell [Gomori's staining].

Discussion

The pancreas develops as dorsal and ventral endodermal outgrowth of distal foregut. The initial ventral bud arises from the hepatic diverticulum after dorsal bud [10]. In this study, primary pancreas determined between day 10 and 13 of incubation. By day 13, dorsal lobe appeared near the developing liver and by day 16, the ventral lobe was developed. In the chicken, the dorsal bud has been reported to appear by day 5 and the ventral bud has been determined on day 7 of incubation [8]. In the rodent, pancreatic bud appears at the middle stages of gestation [4]. For example the dorsal bud in rat, has been observed on day 11 of gestation (20 somite stage), in mouse on day 9.5,

and in rabbit on day 11 of embryonic development. In rat, the ventral part of pancreas has been observed to develop about 12hr later than dorsal part (28-30 somite stage) [3,16,15]. In this study on day 22, the lobes were separated with a narrow space. In chicken, the dorsal and ventral lobes are distinguished on day 9 and all the pancreatic lobes are demonstrated to be present by day 12 of incubation [8].

We noticed that between days 13 and 16 of incubation, the pancreas consisted of the undifferentiated epithelial cells, non-organized ducts, blood vessels and lots of mesenchyme connective tissue. Zymogen granules and mitotic cells were obvious in developing acini on day 22. By aging, the level of connective tissue and ducts were decreased and zymogen granules were increased. Mitosis was observed in all embryonic stages. In chicken, between days 5 and 7, the pancreas is composed of epithelial cells in mesenchymal tissue and between days 9 and 12, the ducts appear in connective tissue [8]. In rat by day 13, the pancreatic tissue consists of undifferentiated epithelial cells with high volume of mesenchyme and on day 19, most of epithelial cells are acinar cells with zymogen granules and ducts [3]. In rabbit, on day 12 of gestation, the pancreatic cords with thin lumen appear and the ductal and exocrine cells have mitotic activity. The cells have many free ribosomes and rough endoplasmic reticulum [15]. As expected, from fetal to newborn, the exocrine secretory units increase and the level of blood vessels and connective tissue decreases [9].

In this study, on day 1 after hatching the islets were appeared by haematoxylin eosin [H&E] and Gomori's stain. In chicken, by day 5, the endocrine cells are detectable with immunohistochemistry [8]. In quail the endocrine part includes beta, alpha and mixed islets and they are centralized in splenic and third lobes [13]. The pancreatic islets in goose are also composed of alpha, beta and mixed islets [11]. In rat, the glucagon cells are determined by day 11 and insulin cells are detect on day 12.5 by immunohistochemistry [3]. In rabbit, insulin and glucagon immunoreactive cells are infrequently detected on day 13 of embryonic development [15]. In human, insulin immunoreactive cells are found on week 7 of development [5]. Thus, according to other studies, immunohistochemical staining is suitable for detection of the endocrine cells in initial stages. In ostrich, on day 1 after hatching the islets were determined by routine examination

with haematoxylin & eosin and Gomori's staining. More islets were concentrated in dorsal and splenic lobes and the alpha islets were higher in number and larger than beta islets.

Materials and methods

In this study, twenty four ostrich embryos on days 10, 13, 16, 22, 26, 30 and 36 of prehatching and day 1 of posthatching life were used. The pancreas was separated and fixed in 10% buffered formalin and Bouin's solution for histological examinations. The fixed specimens were dehydrated with ethanol, cleared in xylene, embedded in paraffin wax, cut at 5-6 μm thickness, and stained with haematoxylin eosin [H&E] and Gomori [7].

For semi-thin sections, small specimens of pancreas were fixed in 2% glutaraldehyde in Na-cacodylate buffer, pH 7.4 for 1-2 hours. They were washed in the same buffer. For secondary fixation, the samples rinsed in 1% osmic acid in 0.1M Na-cacodylate buffer for 50-60 minutes. Then the sections were washed and dehydrated in ethanol. Propylene oxide was used for infiltration of resin in tissue and the samples embedded in Araldite-Epon mixture. Semi-thin sections [1 μm in thickness] stained with Toluidine blue [6].

Acknowledgements

The authors would like to thank the biochemistry and histology laboratories, Department of Basic Sciences, Faculty of Veterinary Medicine, Ferdowsi University of Mashhad. . This study was financially supported by Ferdowsi University of Mashhad.

Author contributions

Conceived and designed the experiments: Z.S. Performed the experiments: M.A. Analyzed the data: Z.S., M.A., H.G.A. Research space and equipment: Z.S. Contributed reagents/materials/analysis tools: Z.S. Wrote the paper: Z.S., M.A.

Conflict of Interest

None of the authors of this paper have a financial or personal relationship with other people or organizations that could inappropriately influence or bias the content of the paper.

References

1. Eurell JA, Frappier BR. Text book of veterinary histology [Dellman]. 6th ed. Blackwell publishing Ltd; 2006.
2. Fletcher TF, Weber AF. Veterinary developmental anatomy. Minnesota Veterinary Anatomy Courseware Web Site; CVM 6903; 2013.

3. Githens S. Differentiation and development of the pancreas in animals. 2nd edition. Raven press ltd: New York; 1993.
4. Gradwohl G. Development of endocrine pancreas. *Diab and amp metabol.* 2006; 32(5): 532-533.
5. Krivova SY, Proshchina AE, Barabanov VM, Saveliev SV. Development of the islets of Langerhans in the human fetal pancreas. *Nova science publisher.* 53-87; 2012.
6. Kuo J. Electron microscopy methods and protocols. Totowa: Humana press; 2007.
7. Luna LG. Histologic staining method of the armed forces institute of pathology of USA; 1998.
8. Manakova E, Titlbach M. Development of chick pancreas with regard to estimation of the relative occurrence and growth of endocrine tissue. *Anat Histol Embryol.* 2007; 36: 127-134.
9. Mansouri SH, Gholami H, Musavi Orimi GH. Histomorphometrical study of pancreas in mehraban female sheep. *Vet reaserch Shiraz.* 2006; 7(2): 13-19.
10. Mcgeady TA. *Veterinary embryology*: Blackwell publishing Ltd; 2006.
11. Mobini B. Histological study of pancreas of Goose [anser albiferons]. *Vet res forum.* 2011; 2(1): 25-29.
12. Rawdon BB. Morphogenesis and differentiation of the avian endocrine pancreas, with particular references to experimental studies on the chick embryo. *Micros Res Tech.* 1998; 26:31-43.
13. Simsek N, Alaby B. Light and electron microscopic examination of the pancreas in quails [Coturnix coturnix Japonica]. *Rev mev vet.* 2008; 4: 198-206.
14. Stornelli MR, Ricciardi MP, Miragliotta V, Coli A, Giannessi E. Morpho- structural study of the pancreas and pancreatic duct in ostrich [Struthio camelus L.]. *Acta vet brono.* 2006; 75: 157-160.
15. Titlbach M, Manakova E. Development of rabbit pancreas with particular regard to the argyrophilic cells. *Acta Vet Brono* 2007; 76: 509-517.
16. Wessels NK, Cohen J. Early pancreas organogenesis, morphogenesis, tissue interaction and mass effect. *Dev Biol.* 1967; 15(32): 237-270.

DOI: 10.22067/veterinary.v9i1.61068

بررسی هیستومورفوزن پانکراس جنین شتر مرغ

معصومه احدیان، زهره سعادتفر، حمیده قدرتی آزادی

گروه علوم پایه، دانشکده دامپزشکی، دانشگاه فردوسی مشهد، مشهد، ایران

پذیرش نهایی: ۱۳۹۵/۱۲/۱۸

دریافت مقاله: ۱۳۹۵/۰۹/۲۵

چکیده

مطالعه حاضر به منظور بررسی تکامل پانکراس در شتر مرغ انجام شد. این مطالعه بر روی ۲۴ عدد تخم شتر مرغ در سنین ۳۰، ۲۶، ۲۲، ۱۶، ۱۳، ۱۰ و ۳۶ روزه جنینی و ۱ روزگی بعد از خروج از تخم انجام شد. رنگ آمیزی های هماتوکسیلین- اتوزین، گوموری و تولوئیدین بلو برای بررسی نمونه ها با میکروسکوپ نوری استفاده شد. در ۱۳ روزگی، بافت پانکراس در مجاورت کبد و روده (دوازدهه) قابل مشاهده بود. در این سن پانکراس تنها از یک لوب تشکیل شده و حاوی سلول های پوششی تکامل نیافته، بافت همبند، مجاری و عروق خونی سازمان یافته نبود. در ۱۶ روزگی، پانکراس حاوی دو لوب پشتی و شکمی و از نظر ساختار بافتی مشابه ۱۳ روزگی بود. در ۲۲ روزگی گرانول های زیموژن درون بخش برون ریز مشخص شدند. با افزایش سن میزان بافت همبند و مجاری کاهش یافته و واحدهای آسینار افزایش یافتند. در سن ۱ روزگی پس از تولد جزایر پانکراس مشخص شدند.

واژگان کلیدی: شتر مرغ، بافت شناسی، پانکراس، تکامل