

Case Report

DOI: 10.22067/veterinary.v9i1.58619 Received: 2016-Sep-03
Accepted after revision: 2017-Feb-06
Published online: 2017-Aug 30

Fibrosarcoma in a Goldfish (*Carassius auratus*): a Case report

Annahita Rezaie,^a Zahra Tulaby Dezfuly,^b Rahim Peyghan^c

^a Department of Pathobiology, Faculty of Veterinary Medicine, Shahid Chamran University of Ahvaz, Ahvaz, Iran

^b Department of Aquatic Animals Health, Faculty of Veterinary Medicine, Shahid Chamran University of Ahvaz, Ahvaz, Iran

^c Department of Clinical Sciences, Faculty of Veterinary Medicine, Shahid Chamran University of Ahvaz, Ahvaz, Iran

Keywords

fibrosarcoma, goldfish

Abstract

Neoplasms in fishes are generally less aggressive than neoplasms in mammals and are most commonly discrete and focal. Although tumors were originated from connective tissue are frequently seen in the fishes, but dermal fibrosarcoma is rarely found in fish. A moribund four years old Goldfish (*Carassius auratus*), was referred veterinary hospital of Shahid Chamran University of Ahvaz with an exophytic non-ulcerated mass near the caudal peduncle. Microscopic examination of the mass revealed proliferated spindle cells and the interlacing, loose and eosinophilic bundles. For differential diagnosis, Masson's trichrome staining was performed and the fibers stained blue. According to histopathological and histochemical results, tumor identified as fibrosarcoma. It is the first report of histopathological features of cutaneous fibrosar-

comas in a Goldfish in Iran.

Abbreviations

WDSV: walleye Dermal Sarcoma Virus

IRANIAN JOURNAL OF VETERINARY SCIENCE AND TECHNOLOGY

Tel: +98 51 3880 3742 Fax: +98 51 3876 3852
Web: ijvst.um.ac.ir Email: ijvst@um.ac.ir

Corresponding author:

Annahita Rezaie
Department of Pathobiology,
Faculty of Veterinary Medicine,
Shahid Chamran University of Ahvaz, Ahvaz, Iran

Email: a.rezaie@scu.ac.ir

Introduction

Tumors of connective tissues are evaluated in subclassification of spindle cell tumors. Dermal fibroma and fibrosarcoma are infrequently found in fishes, however, tumors of fibrous connective tissues are frequently seen in all types of mesenchymal tumors of fishes. The dermal tumors are usually raised from the surface of the trunk, head and fins. It is substantiated that the tumors are likely found in association with environmental factors and infectious agents in farmed and wild fishes [8].

Fibroma is a benign tumour arising from fibroblasts, and fibrosarcoma is malignant equivalent with high cellularity. Proliferated fibroblasts are often arranged in irregular cords, and whorls. No clear etiology was established and the histogenesis of some of these tumors is ambiguous. Different types of fibrosarcoma have been reported in a number of species, including Goldfish (*Carassius auratus*) with three mass on the right side of the body, yellow perch [*Perca flavescens*] with two tumors on the right flank near the dorsal fin, and fork tailed catfish (*Hemibarbus diictes*) with multiple tumors in oral cavity, operculum and caudal peduncle [1; 3; 5]. Bowser et al (2005) have confirmed the presence of walleye dermal sarcoma virus (WDSV) by PCR and suggested that the virus is horizontally transmitted within the walleye population of the lake during spring when the adult fish migrate in streams for spawning [3]. Dennis and Diggles (2015) reported the histopathological features of multiple orocutaneous fibrosarcomas in a warrior catfish [*Hemibarbus diictes*] [5]. This report is related to clinicopathological features of cutaneous fibrosarcomas in a Goldfish in Iran.

Case description

A four-year old Goldfish with an exophytic non-ulcerated mass near the caudal peduncle were referred to the Aquatic Animals Health Department of Shahid Chamran University of Ahvaz. The owner has observed the tumor one year ago, but the fish became depressed and anorectic in the 1-2 week before presentation. Because of lethargy and unbalance swimming, the prognosis was poor and no therapeutic procedure proposed. The fish was euthanized and necropsy was carried out. The external surfaces, mouth, gill chambers and internal organs of the fish were clinically examined. The

weight of fish was 44 grams and its length was 18.5 cm and had the enlarged abdomen, which persisted for more than 2 weeks.

Macroscopically, the mass was localized in caudal peduncle and its diameter was approximately 1.5 cm. It had a rough surface and the consistency was firm and gray-white color (Figure 1). The cut surface was firm and white.

The tumor mass was fixed in 10% neutral buffered formalin and sent to the histopathological lab. The mass was sectioned at 5 μ m thicknesses from paraffin blocks and stained with Hematoxylin and Eosin (H&E) and Masson's Trichrome. The slides were observed by light microscope.



Figure 1
Goldfish (*Carassius auratus*). A white mass is visible near the peduncle.

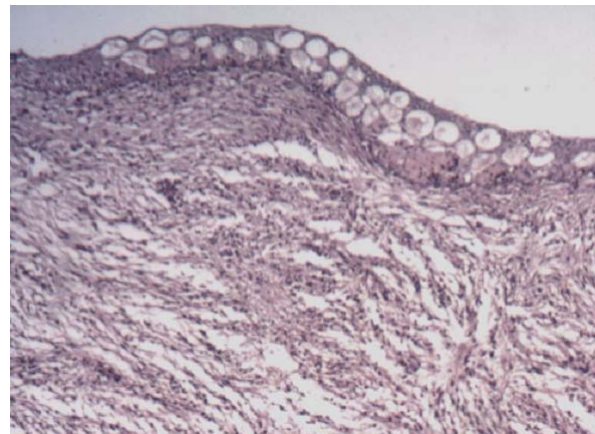


Figure 2
Low magnification of a histological section of fibrosarcoma in Goldfish (*Carassius auratus*). Note the interlacing bundles of connective tissue, which are in different directions (Hematoxylin and Eosin).

Microscopic examination of the mass revealed proliferated spindle cells with eosinophilic loose fibers. They were located in the interlacing pattern (Figure 2). The numbers of nuclei were high and hypercellularity was obvious. Also, pleomorphism

and anisokaryosis were identified which were characterized by different shape and size of nuclei (Figures 3 and 4). Necrosis and haemorrhage were not seen. As the entity of fibers was not detected, Masson's trichrome staining was performed and the interlacing bundles were stained blue (Figures 5 and 6). According to histopathological and histochemical results, fibrosarcoma was diagnosed.

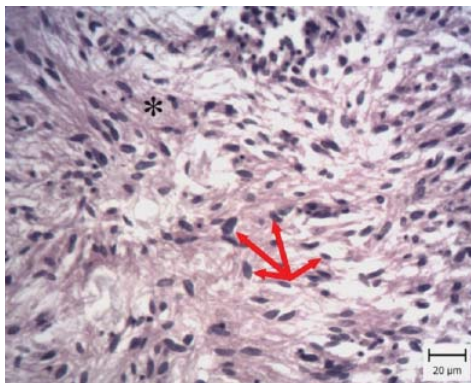


Figure 3
High magnification of a histological section of fibrosarcoma in Goldfish (*Carassius auratus*). Note the interlacing eosinophilic bundles of connective tissue, which are in different directions (asterisks). Pleomorphism and anisokaryosis is obvious. Nuclei of spindle cells have variable sizes and shapes (red arrows) (Haematoxylin and Eosin, Bar: 20µm)

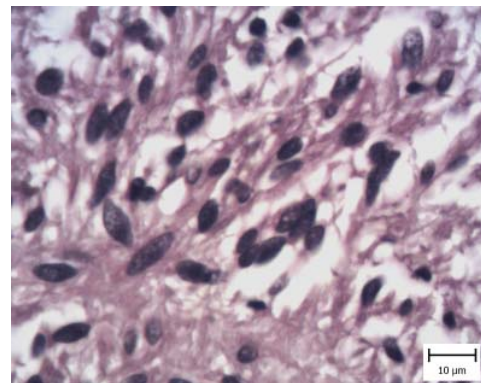


Figure 4
Hypercellularity, pleomorphism and anisokaryosis in fibrosarcoma. Nuclei of spindle cells have variable sizes and shapes (Haematoxylin and Eosin, Bar: 10µm).

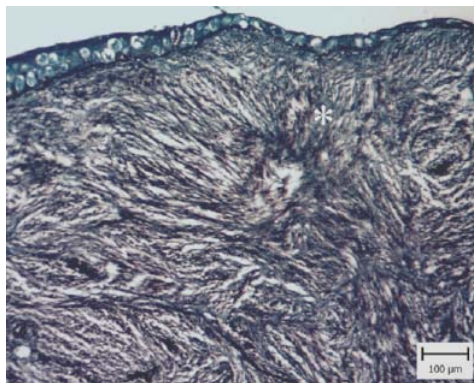


Figure 5
Low magnification interlacing blue bundles of connective tissue, which are in different directions (asterisk) (Masson's trichrome, Bar: 100µm).

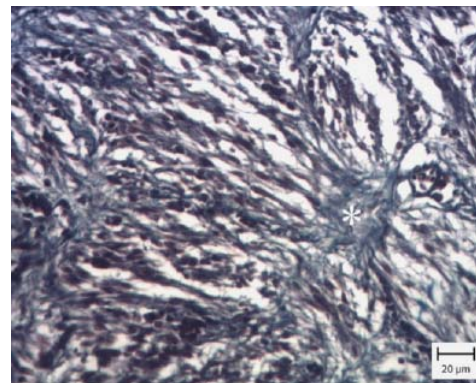


Figure 6
High magnification interlacing blue bundles of connective tissue, which are in different directions (asterisk) (Masson's trichrome, Bar: 20µm).

leiomyoma and leiomyosarcoma. In granulation tissue, the fibers are in one direction and between them, angiogenesis is occurred. However in this mass, angiogenesis was not seen and the direction of fibers was completely different and they had interlacing pattern. The hypercellularity, pleomorphism and anisokaryosis of proliferated

Discussion

This report described histopathological characteristics of fibrosarcoma in a Goldfish. The existence of spindle cells and interlacing fibers were confirmed which was in accordance with other reports [1, 8]. These characteristics are seen in other lesions such as granulation tissue, fibroma,

cells showed malignancy. The entity of fibers was detected by histochemical staining (Masson's Trichrome). The fibers did not have a muscular entity and they were differentiated from leiomyosarcoma or rhabdomyosarcoma.

Fibrosarcoma is a rare and malignant soft tissue sarcoma. Etiology is usually unknown, but is often

suspected to involve viral or chemical factors [8]. Retroviruses are first candidates for induction of cutaneous fibroma/fibrosarcoma of the hooknose (*Agonus cataphractus*), dermal sarcoma of walleye (*Stizostedion vitreum*), and fibroma of the lip of the angelfish (*Pterophyllum scalare*) [4]. Walker (1969) and Yamamoto et al., (1976) demonstrated C type particles of virus in the fibrosarcoma of an American pike-perch. Duncan (1978) diagnosed ultrastructurally oncoviruses associated with swim bladder fibrosarcoma in Atlantic Salmon. Another report has also been described from wild Atlantic salmon on the western seaboard of the Atlantic Ocean [7]. Adverse environmental factors such as high population densities, high concentrations of no specific pollutants and carcinogens in water, sediments and food organisms may contribute to a further suppression of defense mechanisms [2]. In the present case, the mass was developed during approximately 1 year period from 0.5 cm to 1.5 cm in diameter. It can be suggested that carcinogenic materials in water, sediment or biota can influence the development of a benign tumor by mutational modification of cellular functions, resulting in a progress to malignancy. However, the exact etiology is unknown and it needs more investigation.

In conclusion, according to histopathological characteristics of the tumor, it was diagnosed as fibrosarcoma.

Acknowledgements

The authors wish to thank Miss and Mr. Behdarvand for their technical assistance.

Author Contributions

Conceived and designed the experiments, performed the experiments, and wrote the paper: Z.T.D., R.P. Analyzed the data: A.R.

Conflict of Interest

The authors have no conflict of interest to declare.

References

1. Ahmed AT, Egusa S. Dermal fibrosarcoma in goldfish *Carassius auratus* (L.). *Journal of Fish Diseases*. 1980 May 1;3[3]: 249-54.
2. Anders K, Yoshimizu M. Role of viruses in the induction

of skin tumours and tumour-like proliferations of fish. *Diseases of Aquatic Organisms*. 1994 Aug 25; 19:215-32.

3. Bowser PR, Abou-Madi N, Garner MM, Bartlett SL, Grimmett SG, Wooster GA, Paul TA, Casey RN, Casey JW. Fibrosarcoma in yellow perch, *Perca flavescens* (Mitchill). *Journal of fish diseases*. 2005 May 1;28(5): 301-5.
4. Coffee LL, Casey JW, Bowser PR. Pathology of Tumors in Fish Associated With Retroviruses A Review. *Veterinary Pathology Online*. 2013 May 1;50(3): 390-403.
5. Dennis MM, Diggles BK. Multicentric orocutaneous fibrosarcoma in a fork-tailed catfish (*Hemiarus dioctes*). *Journal of fish diseases*. 2015 Dec 1;38(12): 1077-81.
6. Duncan IB. Evidence for an oncovirus in swimbladder fibrosarcoma of Atlantic salmon *Salmo salar* L. *Journal of Fish Diseases*. 1978 Jan 1;1(1): 127-31.
7. Paul TA, Quackenbush SL, Sutton C, Casey RN, Bowser PR, Casey JW. Identification and characterization of an exogenous retrovirus from atlantic salmon swim bladder sarcomas. *Journal of virology*. 2006 Mar 15;80(6): 2941-8.
8. Roberts RJ. *Fish pathology*. John Wiley & Sons; 2012 Mar 6.
9. Walker RO. Virus associated with epidermal hyperplasia in fish. *National Cancer Institute Monograph*. 1969 Jul; 31:195.
10. Yamamoto T, Macdonald RD, Gillespie DC, Kelly RK. Viruses associated with lymphocystis disease and dermal sarcoma of walleye (*Stizostedion vitreum vitreum*). *Journal of the Fisheries Board of Canada*. 1976 Nov 1; 33(11): 2408-19.

DOI: 10.22067/veterinary.v9i1.58619

فیروسارکوم در یک ماهی حوض: گزارش موردی

آناهیتا رضایی^{۱*}، زهرا طولابی دزفولی^۲، رحیم بیغان^۳

^۱گروه پاتوبیولوژی، دانشکده دامپزشکی، دانشگاه شهیدچمران اهواز، اهواز، ایران

^۲دانشجوی دکترای تخصصی بهداشت آبزیان، دانشکده دامپزشکی، دانشگاه شهیدچمران اهواز، اهواز، ایران

^۳گروه علوم درمانگاهی، دانشکده دامپزشکی، دانشگاه شهیدچمران اهواز، اهواز، ایران

دریافت مقاله: ۱۳۹۵/۰۶/۱۳ پذیرش نهایی: ۱۳۹۵/۱۱/۱۸

چکیده

نئوپلاسم‌ها در ماهیان نسبت به سایر حیوانات کمتر به صورت تهاجمی بوده و بیشتر به صورت مجزا و کانونی رخ می‌دهند. اگرچه تومورهای با منشأ بافت پیوندی اغلب در ماهیان دیده می‌شوند، اما فیروسارکوم پوستی به ندرت در ماهی گزارش شده است. یک ماهی حوض (*Carassius auratus*) چهار ساله در حال مرگ، با یک توده‌ی فاقد زخم در نزدیکی ساقه‌ی دمی به بخش آبزیان ارجاع داده شد. بررسی میکروسکوپی توده بیانگر سلول‌های دوکی شکل تکثیر یافته همراه با رشته‌های در هم رونده و ائورینوفیلی با تراکم کم بود. برای تشخیص افتراقی، رنگ‌آمیزی ماسون تری کروم انجام شد و رشته‌های همبندی به رنگ آبی دیده شدند. برپایه نتایج حاصل از بررسی هیستوپاتولوژی و هیستوشیمی، فیروسارکوم تشخیص داده شد. این اولین گزارش از خصوصیات آسیب شناسی بالینی فیروسارکومای پوستی ماهی حوض در ایران است.

واژگان کلیدی: فیروسارکوم، ماهی حوض